ISSN 1121 – 4171

1 | June 2018 | Vol. 32 |

GIORNALE ITALIANO DI ENDODONZIA

Società Italiana di Endodonzia

EDITORIAL

- SIE CONGRESS: BETWEEN FOUNDATIONS AND INNOVATIONS THE PAST IS IMPROVED TO LOOK AT THE FUTURE OF ENDODONTICS

ORIGINAL ARTICLES

- APICAL SURGERY VS APICAL SURGERY WITH SIMULTANEOUS ORTHOGRADE RETREATMENT: A PROSPECTIVE COHORT CLINICAL STUDY OF TEETH AFFECTED BY PERSISTENT PERIAPICAL LESION
- REVASCULARIZATION VERSUS APICAL BARRIER TECHNIQUE WITH MINERAL TRIOXIDE AGGREGATE PLUG: A SYSTEMATIC REVIEW
- IMPROVED SINGLE VISIT MANAGEMENT OF OLD INFECTED IATROGENIC ROOT PERFORATIONS USING BIODENTINE®

CASE REPORTS

- SURGICAL EXTRUSION: A RELIABLE TECHNIQUE FOR SAVING COMPROMISED TEETH. A 5-YEARS FOLLOW-UP CASE REPORT

VINCITORE MIGLIOR CASO CLINICO CLOSED MEETING 2017

- RETREATMENT OF A MANDIBULAR SECOND PREMOLAR WITH TWO CANALS IN TWO ROOTS

VINCITORI PREMI 35° CONGRESSO NAZIONALE BOLOGNA 2017

- HUMAN PERIAPICAL CYSTS-MESENCHYMAL STEM CELLS CULTURED WITH ALLOGENIC HUMAN SERUM ARE A ''CLINICAL-GRADE'' CONSTRUCT ALTERNATIVE TO BOVINE FETAL SERUM AND INDICATED IN THE REGENERATION OF ENDO-PERIO DONTAL TISSUES
- CYCLIC FATIGUE RESISTANCE OF NICKEL-TITANIUM RECIPROCATING INSTRUMENTS TESTED WITH AN INNOVATIVE KINEMATICS
- REMOVAL OF FIBER POSTS DURING ENDODONTIC RETREATMENTS USING ULTRASONIC TIPS: A COMPARISON BETWEEN TWO DIFFERENT ENDODONTIC FIBER POSTS

Available online at www.sciencedirect.com

ScienceDirect

One Curve

MICRO MEGA

EFFICIENTE

INTELLIGENTE

CONSERVATIVO

L'ESSENZA DEGLI STRUMENTI NITI ORA HA UN NUOVO NOME

One Curve è lo strumento unico progettato per tutte le fasi di sagomatura canalare che nella sua semplicità racchiude l'essenza dei trattamenti canalari di successo.

Un unico strumento iper-flessibile e pre-curvabile che garantisce un perfetto controllo del trattamento e si adatta ad anatomie canalari semplici e complesse.

Il protocollo One Curve è sicuro, veloce e semplificato: l' accesso facilitato al canale e l' adattamento a qualunque anatomia rendono più sicuro il trattamento, consentendo di dedicare maggior tempo all' irrigazione del canale.

59% + **veloce**

rispetto a una **sequenza di strumenti**

100% + **flessibile e precurvabile**

2,4 X **più resistente** alla frattura (stress ciclico)

DENTALICA
www.dentalica.com

DISTRIBUTORE ESCLUSIVO PER L'ITALIA
DENTALICA S.p.A. – Via Rimini, 22 – 20142 Milano
T 02.895981 – F 02.89504249 – info@dentalica.com – www.dentalica.com

NUMERO VERDE
800 70 71 72

Novità

2Shape



- **Semplicità**
- **Sicurezza**
- **Efficacia**

T·Wire

Trattamento termico esclusivo MICRO-MEGA®

Maggiore flessibilità

Maggiore resistenza alla frattura

Caso clinico

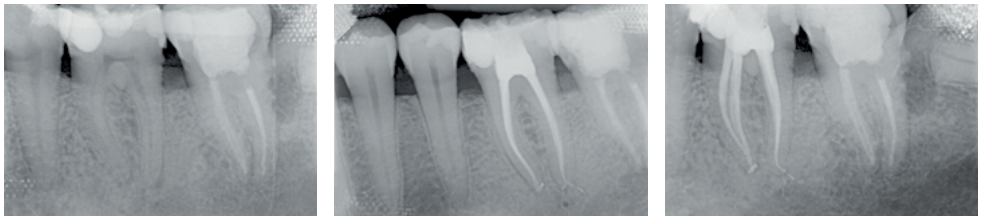

Sagomatura con 2Shape : TS1 e TS2. Dr. Jean-Philippe Mallet, Francia

DENTALICA
www.dentalica.com
NUMERO VERDE 800 70 71 72
info@dentalica.com

GIORNALE ITALIANO DI ENDODONZIA

Organo Ufficiale della SIE – Società Italiana di Endodonzia

EDITORIAL BOARD

EDITOR IN CHIEF

Prof. RENGO SANDRO
Professor and Chair of Endodontics,
Federico II University of Naples
Italy, Former President of SIE

ASSOCIATE EDITORS

Prof. DOTT. PLOTINO GIANLUCA
Private Practice, Grande Plotino
Torsello - Studio di Odontoiatria,
Rome - Italy

Prof. PRATI CARLO
Full Professor of Endodontics and
Operative Dentistry, Dean Master
in Clinical Endodontology
Head Endodontic Clinical Section
Dental School - University of Bologna,
Bologna, Italy

ASSISTANT EDITORS

Prof. BERUTTI ELIO
Professor and Chair of Endodontics
University of Turin
Dental School
Former President of SIE

Prof. CERUTTI ANTONIO
Professor and Chair of Restorative
Dentistry
University of Brescia
Dental School
Active member of SIE

Prof. COTTI ELISABETTA
Professor and Chair of Endodontics
University of Cagliari
Dental School
Active member of SIE

Prof. DI LENARDA ROBERTO
Professor and Chair of Endodontics
Dean of Dental School
University of Trieste
Dental School

Prof. GAGLIANI MASSIMO
Professor and Chair of Endodontics
University of Milan
Dental School

Prof. PIATTELLI ADRIANO
Professor and Chair of Oral Pathology
University of Chieti
Dental School

EDITORIAL COMMITTEE

Prof. AMATO MASSIMO
Associate Professor
University of Salerno
Department of Medicine and Surgery
Active member of SIE

Dr. BADINO MARIO
Private practice in Milan
SIE Officer

Dr. CARDINALI FILIPPO
Private practice in Ancona
Active member of SIE

Dr. CASTRO DAVIDE FABIO
Private practice in Varese
SIE Officer

Dr. CORAINI CRISTIAN
Private practice in Milan
Active member of SIE

Prof. FORTUNATO LEONZIO
Associate Professor of Odontostomatological Illnesses, University of Magna Graecia, CZ Italy
Active Member of SIE

Dr. FABIANI CRISTIANO
Private practice in Rome
Active member of SIE

Dr. FORNARA ROBERTO
Private practice in Magenta
Certified Member of ESE
SIE Officer

Prof. MANGANI FRANCESCO
Professor and Chair of Restorative
Dentistry
University of Rome Tor Vergata
Dental School
Active member of SIE

Dr. PISACANE CLAUDIO
Private practice in Rome
Active member of SIE

Prof. RE DINO
Professor and Chair of Prosthodontics
University of Milan Dental School
Active member of SIE

Dr. TASCHIERI SILVIO
Private practice in Milan
Active member of SIE

Dr. TOSCO EUGENIO
Private practice in Fermo
Active member of SIE

EDITORIAL BOARD

Dr. BARBONI MARIA GIOVANNA
Private practice in Bologna
Active member of SIE

Dr. BATE ANNA LOUISE
Private practice in Cuneo
Active member of SIE

Dr. BERTANI PIO
Private practice in Parma
Elected President of SIE

Prof. CANTATORE GIUSEPPE
Professor of Endodontics
University of Verona Dental School
Former President of SIE

Dr. CASTELLUCCI ARNALDO
Private practice in Florence
Former President of SIE
Former President of ESE

Prof. CAVALLERI GIACOMO
Professor and Chair of Endodontics
University of Verona Dental School
Former President of SIE

Dr. COLLA MARCO
Private practice in Bolzano
Active member of SIE

Prof. GALLOTTINI LIVIO
Professor and Chair of Endodontics II
University of Rome La Sapienza
Dental School
Active member of SIE

Prof. GEROSA ROBERTO
Professor and Chair of Endodontics
University of Verona
Dental School
Active member of SIE

Dr. GIARDINO LUCIANO
Private practice in Crotone
Member of SIE

Dr. GORNI FABIO
Private practice in Milan
Former President of SIE

Dr. GRECO KATIA
Lecturer in Endodontology
University of Catanzaro
Scientific Board Coordinator SIE

Prof. KAITSAS VASSILIOS
Professor of Endodontics
University of Thesalonikki (Greece)
Active member of SIE

Dr. LENDINI MARIO
Private practice in Turin
Scientific Secretary of SIE

Prof. MALAGNINO VITO ANTONIO
Professor and Chair of Endodontics
University of Chieti
Dental School
Former President of SIE

Dr. MALENTACCA AUGUSTO
Private practice in Rome
Former President of SIE

Dr. MANFRINI FRANCESCA
Private practice in Riva
Active member of SIE

Dr. MARCOLI PIERO ALESSANDRO
Private pratice in Brescia

Dr. MARTIGNONI MARCO
Private practice in Rome
President of SIE

Prof. PECORA GABRIELE
Former Professor of Microscopic
Endodontics
Post-graduate courses
University of Pennsylvania (USA)
Active member of SIE

Dr. PONGIONE GIANCARLO
Private practice in Naples
Active member of SIE

Prof. RICCITIELLO FRANCESCO
Professor of Restorative Dentistry
University of Naples
Dental School
Vice-President of SIE

Dr. SBERNA MARIA TERESA
Private practice in Milan
SIE Officer

Dr. SCAGNOLI LUIGI
Private practice in Rome
Active member of SIE

Prof. TESTORI TIZIANO
Private practice in Como
Former Editor of Giornale Italiano
di Endodonzia

INTERNATIONAL EDITORIAL BOARD

ANG LESLIE
Clinical assistant professor of
Endodontics
Division of Graduate Dental Studies
National University of Singapore

BOVEDA CARLOS
Professor Post-graduate Courses
University of Caracas (Venezuela)

CANCELLIER PETER
Clinical instructor at the University
of Southern California (USA)
School of Dentistry Graduate
Endodontic Program
President of the California State
Association of Endodontists

CHO YONGBUM
International lecturer and researcher
Private practice in Seoul (Korea)

DEBELIAN GILBERTO
Adjunct associate professor
Department of Endodontics
University of North Carolina,
Chapel Hill
University of Pennsylvania,
Philadelphia (USA)

FIGUEIREDO JOSE ANTONIO
Clinical lecturer in Endodontology
Eastman Dental Institute,
London (UK)

GLASSMAN GARY
International lecturer and researcher
Private Practice in Ontario (Canada)
Editor in Chief of Dental Health

GLICKMAN N. GERARD
Professor and Chairman of
Endodontics
School of Dentistry
University of Washington (USA)

HIMEL T. VAN
Professor of Endodontics
School of Dentistry
University of Tennessee (USA)

HUTTER W. JEFFREY
Professor and Chairman of
Endodontics
Goldman School of Dental Medicine
Boston University (USA)

JEERAPHAT JANTARAT
Professor of Endodontics
Mehidol University of Bangkok
(Thailand)
Dental School

KARTAL NEVIN
Professor of Endodontics
Marmara University Istanbul (Turkey)
School of Dentistry

KHAYAT BERTRAND
International lecturer and researcher
Private practice in Paris (France)

MOUNCE RICHARD
International lecturer and researcher
Private practice in Portland (Oregon)

NERVO GARY
International lecturer and researcher
Private practice in Melbourne
(Australia)

PUENTE CARLOS GARCIA
Professor of Endodontics
University of Buenos Aires (Argentina)
School of Dentistry

ROIG MIGUEL
Professor and Head Department of
Restorative Dentistry and Endodontics
Universitat Internacional de Catalunya,
Barcelona, (Spain)

RUDDLE J. CLIFFORD
Assistant Professor
Dept. of Graduate Endodontics
Loma Linda University (USA)

TROPE MARTIN
Professor and Chairman of
Endodontics
School of Dentistry
University of North Carolina (USA)

VERA JORGE
Professor of Endodontics
University of Tlaxcala (Mexico)

©2016 Dentsply Sirona. All rights reserved. *Data on file

Diversi livelli di umidità. Stessa forza adesiva.

Prime&Bond active™

Adesivo universale

PART OF THE **CLASS II** SOLUTION™

Grazie alla nuova tecnologia brevettata Active-Guard™
assicura:

- Prestazioni adesive affidabili sia su dentina eccessivamente bagnata che asciutta
- Versatilità di utilizzo: con tutti i metodi di mordenzatura (total-etch, self-etch e mordenzatura selettiva) e per tutti i restauri diretti e indiretti
- Basso spessore del film
- Nessuna sensibilità post-operatoria
- Formulazione brevettata priva di HEMA, TEGDMA o bisfenolo
- Tempi di lavorabilità lunghi e riduzione degli sprechi

Per saperne di più visita il sito www.dentsplysirona.com o contatta Simit Next al numero 0376.267811

THE DENTAL
SOLUTIONS
COMPANY™

Dentsply Sirona | Simit® NEXT
Endodonzia & Conservativa

L'originale bulk fill SDR®
con formula migliorata e più colori

SDR® flow+
Bulk fill in consistenza fluida

PART OF THE **CLASS II** SOLUTION™

Non ci accontentiamo mai dei nostri successi.
Dalla comprovata formula SDR® nasce il nuovo SDR® flow+ che offre una maggiore resistenza all'usura, una migliore radiopacità e tre nuove tinte. Mantenendo inalterate le sue caratteristiche vincenti: l'eccellente adattamento alla cavità, l'autolivellamento e oltre sei anni di successi clinici, SDR® si conferma il numero uno tra i compositi bulk fill del mercato.

L'inimitabile e migliore di sempre.



Per saperne di più visita il sito www.dentsplysirona.com o contatta Simit Next al numero 0376.267811

THE DENTAL SOLUTIONS COMPANY™

Dentsply Sirona | Simit® NEXT Endodonzia & Conservativa

©2017 Dentsply Sirona. All rights reserved.

1

June 2018 | Vol. 32

GIORNALE ITALIANO DI ENDODONZIA

Organo Ufficiale della SIE – Società Italiana di Endodonzia

Società Italiana di Endodonzia

SIE BOARD 2018

Editor in Chief
Sandro Rengo

Associate Editors
Gianluca Plotino
Carlo Prati

Assistant Editors
Elio Berutti
Antonio Cerutti
Elisabetta Cotti
Roberto Di Lenarda
Massimo Gagliani
Adriano Piattelli

Editorial Committee
Massimo Amato
Mario Badino
Filippo Cardinali
Davide Fabio Castro
Cristian Coraini
Cristiano Fabiani
Roberto Fornara
Leonzio Fortunato
Francesco Mangani
Claudio Pisacane
Dino Re
Silvio Taschieri
Eugenio Tosco

SIE - BOARD OF DIRECTORS

Past President
Pio Bertani

President
Francesco Riccitiello

President Elect
Vittorio Franco

Vice President
Maria Teresa Sberna

Secretary
Roberto Fornara

Treasurer
Filippo Cardinali

Cultural Coordinator
Mauro Rigolone

Comunication's Coordinator
Italo Di Giuseppe

Advisers
Katia Greco
Alberto Rieppi

SIE - Società Italiana di Endodonzia
Legal Head Office:
Via San Pietro snc 98050 Lipari - Isola di Panarea (ME)
Headquarters: Via Pietro Custodi, 3 20136 Milano
Contacts:
Tel. 02.8376799
Fax. 02.89424876
Email: segreteria.sie@me.com
info@endodonzia.it
PEC: segreteria.sie@pec.segreteriasie.it
Site: www.endodonzia.it
www.journals.elsevier.com/giornale-italiano-di-endodonzia/

TABLE OF CONTENTS

Editorial/Editoriale

1 **SIE Congress: Between foundations and innovations the past is improved to look at the future of Endodontics**
Congresso SIE: tra fondamenti ed innovazioni si migliora il passato per guardare al futuro dell'Endodonzia
S. Rengo

Original Articles/Articoli Originali

2 **Apical surgery vs apical surgery with simultaneous orthograde retreatment: A prospective cohort clinical study of teeth affected by persistent periapical lesion**
Chirurgia apicale vs Chirurgia apicale con ritrattamento ortogrado simultaneo: studio clinico prospettico di coorte
C. Prati, A. Azizi, C. Pirani, F. Zamparini, F. Iacono, L. Montebugnoli and M.G. Gandolfi

9 **Revascularization versus apical barrier technique with mineral trioxide aggregate plug: A systematic review**
Rivascolarizzazione contro tecnica della barriera apicale con tappo di MTA: una revisione sistematica
L.A. Chisini, G. Grazioli, A. Francia, A.S.S. Martin, F.F. Demarco and M.C.M. Conde

17 **Improved single visit management of old infected iatrogenic root perforations using Biodentine®**
Trattamento in singola visita delle « Old infected» perforazioni con Biodentine®
D. Mancino, F. Meyer and Y. Haikel

Case Reports/Casi Clinici

25 **Surgical extrusion: A reliable technique for saving compromised teeth. A 5-years follow-up case report**
Estrusione chirurgica: una tecnica predicibile per il recupero di denti compromessi. Un caso clinic con controllo a 5 anni
J. Argueta, A. Orellana and G. Plotino

>

EDITORIAL OFFICE

Gaia Garlaschè
E-mail: editor.giornale@endodonzia.it
Website: www.journals.elsevier.com/giornale-italiano-di-endodonzia/

Managing Director
Pio Bertani

Editorial Director
Roberto Fornara

PUBLISHING

Publishing Support Manager
Ponni Brinda Rajan
p.rajan@elsevier.com

Giornale Italiano di Endodonzia was founded in 1987 and is the official journal of the Italian Society of Endodontics (SIE). It is a peer-reviewed journal publishing original articles on clinical research and/or clinical methodology, case reports related to Endodontics. The Journal evaluates also contributes in restorative dentistry, dental traumatology, experimental pathophysiology, pharmacology and microbiology dealing with Endodontics. Giornale Italiano di Endodonzia is indexed in Scopus and Embase and published online only on ScienceDirect. SIE members can access the journal through the website: www.journals.elsevier.com/giornale-italiano-di-endodonzia/

Copyright © 2018 Società Italiana di Endodonzia. Production and hosting by Elsevier B.V. All rights reserved.

REGISTRATION Court of Milan n ° 89, 3 March 2009

TABLE OF CONTENTS

Vincitore miglior caso clinico closed meeting 2017

31 **Retreatment of a mandibular second premolar with two canals in two roots**
Ritrattamento di un secondo premolare mandibolare con due canali in due radici
C. Fossati

Vincitori Premi 35° Congresso Nazionale Bologna 2017

36 **Human periapical cysts-mesenchymal stem cells cultured with allogenic human serum are a "clinical-grade" construct alternative to bovine fetal serum and indicated in the regeneration of endo-periodontal tissues**
Le human periapical cysts-mesenchymal stem cells coltivate con siero umano allogenico costituiscono un costrutto "clinical-grade" alternativo al siero fetale bovino ed indicato nella rigenerazione dei tessuti endo-parodontali
M. Tatullo, M. Marrelli, F. Palmieri, C. Rengo, F. Paduano and G. Spagnuolo

42 **Cyclic fatigue resistance of Nickel-Titanium reciprocating instruments tested with an innovative kinematics**
Impatto di una nuova cinematica sulla resistenza in fatica ciclica di strumenti reciprocanti
F. Iacono, C. Pirani, L. Generali, M.R. Gatto and M.G. Gandolfi, C. Prati

47 **Removal of fiber posts during endodontic retreatments using ultrasonic tips: A comparison between two different endodontic fiber posts**
Ritrattamento di denti trattati endodonticamente e ricostruiti con perni in fibra: Tecniche di rimozione, vantaggi e limiti
L. Capriotti, K. Greco, G. Paolone, M.T. Sberna and G. Cantatore

Amsterdam • Boston • Jena • London • New York • Oxford • Paris • Philadelphia • San Diego • St. Louis

Scopri nuove opportunità in endo con R-PILOT™

per il glide path
meccanico con RECIPROC® -
se e quando necessario

ENDO
EASY
EFFICIENT

Gestione del glide path in modalità reciprocante più sicura e veloce*

Maggior rispetto dell'anatomia canalare* per un trattamento endodontico predicibile

* Confrontato con altri strumenti in acciaio della linea VDW

dentsplysirona.com
infoweb.italia@dentsplysirona.com
Numero Verde 800-310333
dentsplysirona.italia

VDW®

VDW® Endo Easy Efficient

EDDY®
Sistema innovativo per l'Irrigazione Sonica

Tre benefici in un'unica soluzione

Il potere sonico di EDDY® e il movimento di oscillazione tridimensionale della punta si sono dimostrati efficaci nell'attivazione degli irriganti quanto i sistemi ad ultrasuoni e migliori rispetto all'irrigazione manuale per la rimozione di detriti e dello smear layer.* La punta EDDY® in poliammide è più sicura e flessibile rispetto alle punte in metallo, senza rischi di danneggiamento della dentina.

Prova i benefici clinicamente testati di EDDY® nella tua pratica quotidiana.

Sicuro

Efficace

Clinicamente testato

*Source: Neuhaus, Klaus W, Liebi, Melanie, et. al. Antibacterial Efficacy of a New Sonic Irrigation Device for Root Canal Disinfection. *Journal of Endodontics 2016, 42 (12): 1799-1803.*

www.dentsplysirona.com

Società Italiana di Endodonzia

Available online at www.sciencedirect.com

ScienceDirect

journal homepage: www.elsevier.com/locate/gie

EDITORIAL/EDITORIALE

SIE Congress: Between foundations and innovations the past is improved to look at the future of Endodontics

Congresso SIE: tra fondamenti ed innovazioni si migliora il passato per guardare al futuro dell'Endodonzia

SIE always focused his "mission" on anticipating the innovations in Endodontics, in fact, the annual SIE congress is one of the most awaited moments in dental community. This year, the 35th SIE national congress was in Bologna and focused on the combination of "foundations and innovations", differentiating this binomial into four main themes: tissue-engineering applied to pulp physiopathology, the searching for bio-mimetism in new biomaterials, the demand for predictable treatments in Endodontics and the atypical and borderline aspects in Endodontic surgery.

The sections dedicated to the traditional SIE awards confirmed that the research in Endodontics is going through a phase of high quality, with topics ranging from regenerative Endodontics to the critical review of traditional techniques, compared to those of the latest generation.

The interesting aspect is the growing attention of clinician and researchers to biology and to new technologies on the market place, looking to their clinical and translational aspects.

Great efforts have been made to improve the skills of traditional materials, developing scaffols capable to promoting neo-angiogenesis and local homing of growth factors.

The SIE meeting in Bologna has been a moment of cultural growth, where clinicians and academics have defined the future challenges of Endodontics, following the path of the prestigious tradition that makes it one of the best in the world.

La SIE ha da sempre avuto la *mission* di percorrere le innovazioni in Endodonzia, infatti, il congresso annuale SIE rappresenta uno dei momenti più attesi in odontoiatria. Quest'anno, il 35° congresso nazionale SIE si è svolto a Bologna ed è stato focalizzato sulla commistione tra "fondamenti e innovazioni", declinando questo binomio in quattro tematiche principali: l'ingegneria tissutale applicata alla fisiopatologia pulpare, la ricerca del biomimetismo nei nuovi biomateriali, la richiesta di trattamenti predicibili in Endodonzia complessa e gli aspetti atipici e *border-line* in chirurgia Endodontica.

Le sezioni dedicate ai tradizionali premi SIE hanno confermato come la ricerca in Endodonzia stia attraversando una fase di grande qualità, con tematiche che spaziano dall'Endodonzia rigenerativa alla revisione critica delle tecniche tradizionali paragonate a quelle di ultima generazione.

L'aspetto maggiormente interessante è la crescente attenzione di clinici e ricercatori alla biologia ed alle nuove tecnologie presenti sul mercato, ponendo una peculiare attenzione ai risvolti clinici e traslazionali.

Grandi sforzi si stanno facendo per implementare le caratteristiche dei materiali tradizionali, sviluppando *scaffols* capaci di stimolare la neoangiogenesi e l'*homing* dei fattori di crescita *in-situ*.

Il meeting di Bologna è stato un momento di crescita culturale collegiale, in cui clinici ed accademici hanno definito le future sfide dell'Endodonzia, seguendo il solco della prestigiosa tradizione che l'ha resa tra le migliori nel mondo.

Sandro Rengo Editor in chief
Giornale Italiano di Endodonzia, Italy
E-mail address: editor.giornale@endodonzia.it

Available online 8 May 2018

Peer review under responsibility of Società Italiana di Endodonzia.

Production and hosting by Elsevier

https://doi.org/10.1016/j.gien.2018.04.001

1121-4171/© 2018 Società Italiana di Endodonzia. Production and hosting by Elsevier B.V. This is an open access article under the CC BY-NC-ND license (http://creativecommons.org/licenses/by-nc-nd/4.0/).

sweden & martina

Prof. Vinio Malagnino

Il sistema Mtwo:
immutato negli anni ma sempre in evoluzione nell'utilizzo clinico

MASTER CLINICIANS SESSION
Venerdì 9 novembre, ore 15.10

III SIE INTERNATIONAL CONGRESS 2018

ENDODONTICS:
CLINICAL SOLUTIONS

Milano, 8 - 10 Novembre 2018
San Raffaele Congress Center

Società Italiana di Endodonzia

Società Italiana di Endodonzia

Milan, 8th-10th November 2018

III SIE INTERNATIONAL CONGRESS

ENDODONTICS: CLINICAL SOLUTIONS

San Raffaele Congress Center - Dibit 1
Via Olgettina, 58 20132 Milan

www.endodontics.it

Dr. Giuseppe Squeo

“La via più rapida per un ritrattamento sicuro”

“Sono sempre stato alla ricerca di uno **strumento che permettesse una rimozione rapida e quanto più completa possibile del materiale presente all’interno dei canali radicolari**.
Con ReStart della Komet questa fase è stata semplificata moltissimo. Grazie alla sua punta attiva **ReStart riesce a penetrare anche all’interno di materiali molto duri e compatti.**
La sua flessibilità consente l’asportazione del vecchio materiale anche da canali curvi.”

Dr. Giuseppe Squeo
Specialista in endodonzia e ispiratore degli strumenti Endo ReStart

Promo

Set 4680 ENDO ReStart

che include

2x ENDO ReStart Opener
cod. RE10L15 204 030

4x ENDO ReStart File
cod. RE05L25 204 025

€ 79.00*+ iva

*Fino ad esaurimento scorte, presso i partner aderenti all’iniziativa

kometacademy.it

IL BLOG CHE TI INFORMA

Vai sul sito e consulta il calendario di tutti i corsi Komet.

UNA COMMUNITY AL SERVIZIO DELL’ODONTOIATRIA

UNA FONTE DI INFORMAZIONI CHE TI SEGUE OVUNQUE

UN PERCORSO PER LA TUA FORMAZIONE CONTINUA

Thinking ahead. Focused on life.

MORITA

Semplice, geniale e assolutamente sicuro. Perfetto per qualsiasi canale radicolare.

TriAuto X2
- UNICO
- COMPATTO
- INNOVATIVO

Il nuovo TriAuto ZX2 semplifica il trattamento canalare con la massima sicurezza – perfetto per tutti i tuoi pazienti.
Il manipolo con localizzatore apicale integrato è veramente sorprendente per la sua leggerezza: Senza cavo ed ergonomico si adatta perfettamente alla mano e garantisce massima libertà di movimento Il trattamento è sicuro e facile grazie alle nuove funzioni di sicurezza, quali l' Optimum Glide Path (OGP) e l'Optimum Torque Reverse (OTR). L'OPG semplifica la realizzazione del glide path. L'OTR protegge dalla rottura del file e dalle microfratture invertendo automaticamente la direzione di rotazione quando viene superato il livello di torque. In questo modo, TriAuto ZX2 preserva la sostanza del dente naturale e rende il trattamento ancora più efficiente. Per ulteriori informazioni, vedere **www.jmoritaitalia.com.**

Giornale Italiano di Endodonzia (2018) **32**, 2—8

Available online at www.sciencedirect.com

ScienceDirect

journal homepage: www.elsevier.com/locate/gie

ORIGINAL ARTICLE/ARTICOLO ORIGINALE

Apical surgery *vs* apical surgery with simultaneous orthograde retreatment: A prospective cohort clinical study of teeth affected by persistent periapical lesion

Chirurgia apicale vs Chirurgia apicale con ritrattamento ortogrado simultaneo: studio clinico prospettico di coorte

Carlo Prati, Arash Azizi *, Chiara Pirani, Fausto Zamparini, Francesco Iacono, Lucio Montebugnoli, Maria Giovanna Gandolfi

Endodontic Clinical Section, Department of Biomedical and Neuromotor Sciences (DIBINEM), University of Bologna, Bologna, Italy

Received 7 June 2017; accepted 14 March 2018
Available online 3 May 2018

KEYWORDS
Apical surgery;
Retreatment;
Treatment;
Endodontics;
MTA.

Abstract
Aim: This prospective clinical study analyzed the 24-month outcome of conventional apical surgery retro-filled with calcium-silicate cement *versus* apical surgery with simultaneous orthograde retreatment by means of clinical and radiographic criteria.
Materials and methods: This study included 83 teeth affected by persistent periapical lesions in 68 patients. Mean age was 52 years (median = 51 years; range 19—81 years). Twenty-eight cases were treated with apical surgery, 16 cases with apical surgery with simultaneous orthograde retreatment and 39 cases with orthograde retreatment in previously treated teeth established as control group. Periapical index score (PAI) was used as radiographic criteria. Teeth were examined at 6 months, 1 and 2 years and classified as *healed* (without any symptoms and

* Corresponding author at: Endodontic Clinical Section, Department of Biomedical and Neuromotor Sciences (DIBINEM), University of Bologna Alma Mater Studiorum, Bologna, Italy.
E-mail: carlo.prati@unibo.it (C. Prati), arash.azizi@studio.unibo.it (A. Azizi), chiara.pirani4@unibo.it (C. Pirani), fausto.zamparini2@unibo.it (F. Zamparini), francesco.iacono@hotmail.it (F. Iacono), lucio.montebugnoli@unibo.it (L. Montebugnoli), mgiovanna.gandolfi@unibo.it (M.G. Gandolfi).
Peer review under responsibility of Società Italiana di Endodonzia.

Production and hosting by Elsevier

https://doi.org/10.1016/j.gien.2018.03.001
1121-4171/© 2018 Società Italiana di Endodonzia. Production and hosting by Elsevier B.V. This is an open access article under the CC BY-NC-ND license (http://creativecommons.org/licenses/by-nc-nd/4.0/).

PAI $\leq$ 2), *healing* (without any symptoms and PAI = 3) or *diseased* (with symptoms or PAI $\geq$ 4 and not functional) on the basis of radiographic and clinical criteria. At 24 months evaluation, *healed* and *healing* were considered as *success* and *diseased* and *fracture* as *failure*. Multilevel GLM model and an ordered logistic regression as statistical analysis was made with level of significance set at $p < 0.05$.

Results: Total drop-out was 7% ($n = 6$). After 6—9 months, 6 teeth (3 from apical surgery, 2 from simultaneous treatment and 1 from orthograde retreatment) were extracted for root fracture. Twenty-four-month *success rate* of apical surgery group was 78% ($n = 17$), apical surgery with simultaneous orthograde retreatment presented 81% ($n = 10$) and orthograde retreatment success was 80% ($n = 24$). There was no statistically difference between the groups at 24 months ($p = 0.890$).

Conclusions: Both surgical techniques revealed a high percentage of healing, similar to that reported by previous studies. Apical surgery with simultaneous orthograde retreatment showed a faster healing after 12 months comparing to the control group.

© 2018 Società Italiana di Endodonzia. Production and hosting by Elsevier B.V. This is an open access article under the CC BY-NC-ND license (http://creativecommons.org/licenses/by-nc-nd/4.0/).

PAROLE CHIAVE
Chirurgia apicale;
Ritrattamento;
Trattamento;
Endodonzia;
MTA.

Riassunto

Scopo: In questo studio sono stati confrontati pazienti trattati con chirurgia apicale convenzionale *vs* chirurgia apicale con ritrattamento ortogrado simultaneo. Come gruppo controllo, sono stati considerati pazienti sottoposti a ritrattamento ortogrado.

Materiali e metodi: Questo studio ha incluso 83 elementi con lesioni periapicali persistente (68 pazienti). Ventotto casi di chirurgia apicale, 16 casi di chirurgia apicale con ritrattamento ortogrado simultaneo e 39 casi di ritrattamento ortogrado non chirurgico come gruppo controllo. L'indice periapicale (PAI) è stato utilizzato come criterio radiografico. Gli elementi sono stati esaminati ogni 6 mesi per 24 mesi e classificati in base a criteri clinici e radiografici come *guarito* (assenza di sintomi e PAI$\leq$2), *in guarigione* (assenza di sintomi e PAI = 3) e *non guarito* (presenza di sintomi o PAI$\geq$4). A 24 mesi gli elementi *guariti* e *in guarigione* sono stati classificati come *successo clinico* mentre gli elementi *non guariti* e *fratturati* come *fallimento*. È stata eseguita un'analisi statistica sul modello multilevel GLM e regressione logistica per valutare una possibile differenza significativa tra i gruppi ($p < 0.05$).

Risultati: Il drop-out è stato del 7% (n = 6). Sei elementi (3 dal gruppo chirurgia apicale, 2 dal gruppo chirurgia apicale con ritrattamento ortogrado simultaneo e 1 dal gruppo ritrattamento ortogrado non chirurgico) sono stati estratti dopo 6-9 mesi per frattura radicolare e sono stati considerati come fallimento. Nel gruppo di chirurgia apicale si è osservato un successo clinico a 24 mesi del 78% (n = 17), nel gruppo chirurgia apicale con ritrattamento ortogrado simultaneo dell' 81% (n = 10) e nel gruppo ritrattamento ortogrado non chirurgico dell' 80% (n = 24).

Conclusioni: Entrambe le tecniche chirurgiche hanno mostrato un'alta percentuale di successo a 24 mesi. Non ci sono state differenze significative tra i trattamenti (p = .890) a 24 mesi. È stato osservato una guarigione più rapida nel gruppo di chirurgia apicale con ritrattamento ortogrado simultaneo.

© 2018 Società Italiana di Endodonzia. Production and hosting by Elsevier B.V. Cet article est publié en Open Access sous licence CC BY-NC-ND (http://creativecommons.org/licenses/by-nc-nd/4.0/)

Introduction

The aim of orthograde retreatment is the elimination of necrotic tissue, bacteria and infected obturation material such as gutta-percha and cements from root canal and seal of the canals to prevent re-infection and allow healing.[1] Preparing root canals to the apical foramina[2] or using a patency file[3] may clean most of the apical portion of the main canal, but bacteria are still likely to remain in lateral and accessory canals or in apical ramifications[4] that remain un-instrumented or out of the reach of irrigants. In specific cases when bacteria colonize the apical ramifications of the canal or in presence of extraradicular infection, a surgical procedure effectively removes the infected site and enhances chances of healing.[5] However, in the majority of teeth in which bacteria colonize within the entire root canal system, root-end filling might not effectively prevent persistence or recurrence of apical periodontitis after surgical procedure,[5] hence a simultaneous orthograde therapy with apical surgery would eliminate the infection and prevent reinfection.[6] As orthograde retreatment is performed simultaneously with apical surgery, coronal and middle portions of the root canal system are also cleaned thoroughly.[7,8] Therefore, the present study compared results of two different surgical approaches, with and without simultaneous orthograde retreatment. As control group conventional orthograde retreatment was considered.

Materials and methods

The study was conducted in full accordance with the ethical principles, including the Declaration of Helsinki.[9] This report was written according to Consolidated Standards of Reporting trials guidelines for reporting clinical trials.[10]

Patient population

This study was conducted in the Department of Endodontic, Alma Mater Studiorum University of Bologna. It considered 83 teeth in 68 patients ($M = 35$, $F = 48$; mean age = 52; median = 51 years; range 19—81 years). Table 1 illustrates teeth distribution according to gender, age and treatments.

Inclusion criteria were previous root canal treatment, periodontal lesion of strictly endodontic origin with or without clinical signs or symptoms such as swelling and sinus tract and a minimum follow-up of 24 months. Only cooperative patients without any compromised medical history and use of bisphosphonates were included. Exclusion criteria were class II mobility or greater, horizontal and vertical fractures, perforations, local anatomical limits and inadequate periodontal support.

Criteria for inclusion of teeth in 3 groups were based on 2 different factors: lesion diameter and prosthetic restoration. When a lesion diameter was >5 mm, in presence or absence of prosthetic restoration, tooth was subjected respectively to apical surgery or apical surgery with simultaneous orthograde retreatment. Instead if a lesion diameter was ≤5 mm, tooth was subjected to orthograde retreatment independently from prosthetic restoration.

Treatments

In apical surgery group a preoperative periapical radiograph (Ultraspeed, Carestream, USA) of the tooth was captured, the tooth anaesthetized with 2% mepivacaine (Carboplyina, Molteni, Scandicci, Italy). A full-thickness mucoperiostal flap was raised. Then osteotomy with high speed water-cooled diamond burs (Intensiv, Grancia, Switzerland) mounted on a high-speed water-cooled handpiece (Castellini-Anthos, Bologna, Italy) has been done. After hemostasis, affected roots were resected for 2—3 mm with a diamond bur. Root-end cavities were prepared and filled with a hydraulic calcium silicate cement. Wound was closed using multiple interrupted sutures with Vicryl 3.0 (Johnson & Johnson, Spreitenbach, Switzerland). In different cases Coe-Pak (GC, Fuji, Japan) as a non-eugenol surgical dressing was used. Patient was recalled after 7—14 days. In this session, in case Coe-Pack was used, it was removed, wound was controlled, sutures were removed and a control X-ray was taken.

Table 1 Teeth distribution.

Distribution and number of the teeth		
Gender	Males	35
	Females	48
Age	18—30	9
	31—40	15
	41—50	16
	51—60	14
	>60	29
Treatments	Apical surgery	28
	Apical surgery with simultaneous orthograde retreatment	16
	Orthograde retreatment	39
Total		83

In apical surgery with simultaneous orthograde retreatment group a preoperative periapical radiograph of the tooth was captured, the tooth anaesthetized with 2% mepivacaine (Carboplyina, Molteni, Scandicci, Italy) and isolated with rubber dam (Hygienic Dental Dam, Coltène Waledent, Cuyahoga Falls, OH, USA). Straight-line access was prepared with a high-speed, water-cooled diamond bur (Intensiv, Grancia, Switzerland) mounted on a high-speed water-cooled handpiece (Castellini-Anthos, Bologna, Italy). After preliminary scouting of canals with size 10 K-files (Dentsply Sirona, Ballaigues, Switzerland), working length (WL) was established with an electronic apex locator (Root ZX, Morita, Tokyo, Japan) and confirmed radiographically. Canals were instrumented in a stepdown sequence with the coronal third enlarged with size 4-3-2 Gates-Glidden drills (Dentsply Sirona) and the middle and apical thirds instrumented by hand with K-files (Dentsply Sirona) with 1 mm increments to size 20 to 45 at WL in a step-back technique. Canals were intermittently irrigated with 5 to 10 mL of 5% NaOCl (Niclor 5, Ogna, Muggiò, Italy), cleaned with Endosolv (Septodont, Cedex, France) and finally flushed with 1 to 3 mL of 10% EDTA (Tubuliclean, Ogna). Canals were filled with vertical compaction of guttaperca (Hygenic, Coltène, Germany) and an endodontic sealer. Then Rubber dam was removed and apical surgery as described earlier was performed. A final X-ray was taken. In different cases Coe-Pak (GC, Fuji, Japan) as a non-eugenol surgical dressing was used. Patient was recalled after 7—14 days. In this session, in case Coe-Pack was used, it was removed, wound was controlled, sutures were removed and a control X-ray was taken.

In orthograde retreatment the procedures were standardized following Pirani et al.[11] Canals were instrumented in a stepdown sequence with the coronal third enlarged with size 4-3-2 Gates-Glidden drills (Dentsply Sirona) and the middle and apical thirds instrumented by hand with K-files (Dentsply Sirona) and obturated with Thermafil (Tulsa Dental Products, Tulsa, OK) and AH Plus sealer (Dentsply DeTrey, Konstanz, Germany).

Follow-up

A radiographic examination was performed prior to intervention, 1 week after treatment, 1 month and then every 6 months up to 24 months. Radiographs were taken with X-ray films using paralleling technique in the standardized position.

Assessment of clinical success

Clinical success was defined on the base of clinical and radiographic criteria. Clinical criteria were presence of symptoms (swelling, sinus tract) or other signs of infection and/or normal functioning of the tooth. Radiographic criteria were examined according with periapical index.[12] Teeth free from symptoms and PAI ≤ 2 were classified as *healed*. Teeth

Table 2 Final clinical outcome. Clinical success rate also considered fractures of 3 teeth in apical surgery group, 2 teeth in apical surgery with simultaneous orthograde retreatment group and 1 tooth in orthograde retreatment group. Success was defined when a tooth was considered *healed* or *healing* and failure when *diseased* or *fractured*. Final clinical outcome at 24 months for apical surgery was 78%, for apical surgery with simultaneous orthograde retreatment was 81% and for orthograde retreatment was 80%.

	Clinical outcome					
	Success %(*n*)			Failure %(*n*)		
	Healed	Healing	Total	Diseased	Fractured	Total
Apical surgery (*n* = 26)	67% (17)	11% (3)	78% (20)	11% (3)	11% (3)	22% (6)
Apical surgery with simultaneous orthograde retreatment (*n* = 15)	68% (10)	13% (2)	81% (12)	6% (1)	13% (2)	19% (3)
Orthograde retreatment (*n* = 36)	66% (24)	14% (5)	80% (29)	17% (6)	3% (1)	20% (7)

without any symptoms and PAI = 3 in which the lesion is reduced were classified as *healing* and teeth with symptoms or PAI $\geq$ 4 were classified as *diseased*. At 24 months evaluation, *healed* and *healing* were considered as *success* and *diseased* and *fracture* as *failure*.

Statistical analysis

Multilevel GLM model was fitted to evaluate the existence of any significant difference regarding treatments, follow-up times (baseline, 6 months, 12 months and 24 months), and the interaction between treatments and time frames; tooth type was added to the model as covariate. An ordered logistic regression was fitted to evaluate any significant difference between treatments as final outcome. *p* value was previously set at 0.05.

Results

Six teeth in 6 patients were excluded for lack of follow-up (drop-out = 7%), so that 77 teeth (62 patients) were included i the study. Results at 24 months are shown in Table 2. The PAI score and the presence of pathological signs and/or symptoms were recorded at follow-ups (Figs. 1—3). Six teeth were extracted for root fracture 3 to 12 months after the treatment, 3 teeth in apical surgery group (one central upper incisor, two lateral upper incisors), two teeth in apical surgery with simultaneous orthograde retreatment group (one central upper incisor and one lateral upper incisor) and one tooth in conventional orthograde retreatment group (first upper premolar).

A statistically significant difference between apical surgery with simultaneous orthograde retreatment and orthograde retreatment was observed at 12 months ($p = 0.025$). Apical surgery with simultaneous orthograde retreatment showed faster healing compared to conventional orthograde retreatment (Fig. 4). It should be mentioned that apical surgery with simultaneous retreatment and orthograde retreatment at 24 months were just at the limit of statistically significant difference ($p = 0.069$).

Discussion

According to data from the present study, apical surgery with simultaneous orthograde retreatment showed a statistically higher healing rate ($p = 0.025$) at 12 months, compared to conventional orthograde retreatment.

These results are in agreement with a previous Cochrane systematic review[13] which analyzed 3 different randomized controlled trials.[14—16] Results of this study confirmed also a meta-analysis,[17] where orthograde retreatment over a 2 years follow-up time showed a lower success rate compared to apical surgery, but considered an orthograde retreatment more effective over a 4 years follow-up time.[17] Hence, a longer follow-up (4 years) is required to evaluate results before final classification.[18] In a past systematic review[19] apical surgery with simultaneous orthograde retreatment showed a higher success compared to apical surgery and orthograde retreatment separately.

After the introduction of microsurgical principles and new materials for apical obturation in endodontic surgery (i.e. Calcium Silicate materials) healed rates of apical surgery with root-end filling improved.[20] Calcium silicate demon-

Figure 1 (A) A preoperative radiograph of a maxillary first premolar with a periradicular lesion. (B) A postoperative radiograph of tooth underwent apical surgery. (C) The radiograph taken at the 2-year recall exhibits a complete resolution of the periradicular endodontic lesion. The tooth is classified as healed.

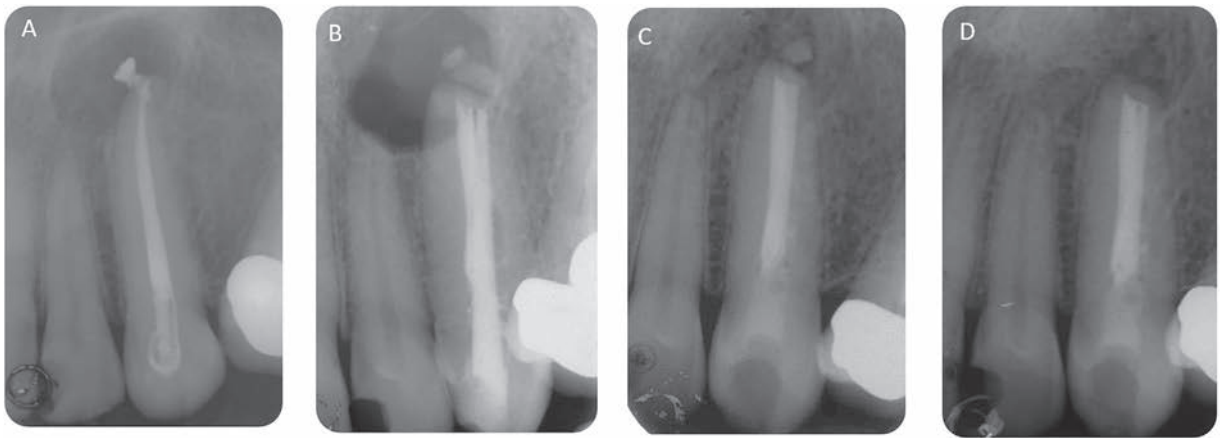

Figure 2 (A) A preoperative radiograph of a maxillary canine with a periradicular lesion. (B) A postoperative radiograph of tooth underwent apical surgery with simultaneous orthograde retreatment. (C) The radiograph taken at the 1-year recall. (D) The radiograph taken at the 2-year recall. The tooth is classified as healed.

Figure 3 (A) A preoperative radiograph of a first mandibular molar with a periradicular lesion. (B) The radiograph taken at the 6-month recall of tooth underwent orthograde retreatment. (C) The radiograph taken at the 2-year recall. The tooth is classified as healed.

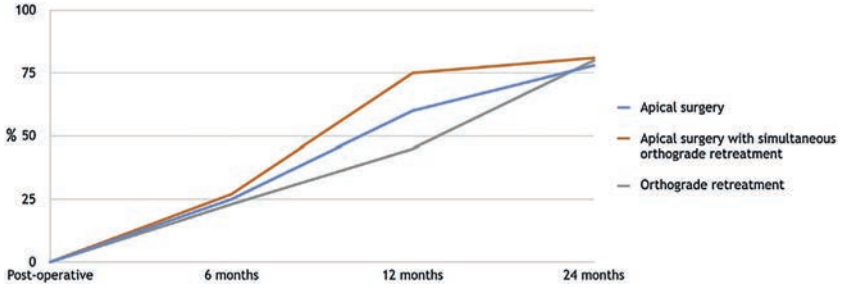

Figure 4 Percentages of healing lesions with different treatments over time. Different healing percentages are noticeable between apical surgery with simultaneous retreatment and orthograde retreatment at one year with statistically significant difference ($p < 0.025$), but final healing percentages at 24 months do not present any statistically significant difference among any of the treatments.

strated good biocompatibility,[21] antimicrobial properties,[22] hydrophilicity,[23] sealing ability,[24] biointeractive and bioactive features.[25,26]

In the present study 5 teeth subjected to apical surgery and apical surgery with simultaneous orthograde retreatment were extracted for root fracture which were not statistically analyzed but were considered as failures in survival rates. This fact may be interesting as reviewed by Ng et al.[27] amongst 15 studies only one[28] included extractions and retreatments in the failure category.[29] Calcium silicate cement showed in vitro a 1.04% expansion during fluid contamination (i.e. blood).[30] This expansion may be an initial cause for root crack during apical surgery.

In this study lesions size was a criteria for treatment selection. In small lesions resident progenitor cells/stem cells might be capable of restoring damage periapical tissue but in large lesions it will not occur and the defect will heal by fibrous connective tissue repair.[31–33]

Different flap techniques (papilla base and sulcular incision) is introduced in apical surgery but there was no statistically different between these groups in term of soft tissue modifications.[34]

In this study all teeth were endodontically treated before the surgery but also in specific cases such as restorations and dystrophic calcification apical surgery could be as the first treatment option.[35] A recent long term study shows high percentage of healing in endodontic treatments but few information is available on long-term outcome of apical surgery.[36]

Conclusions

Both surgical techniques and orthograde retreatment revealed a high percentage of healing.

The statistically significant difference at 12 months between apical surgery with simultaneous orthograde retreatment and orthograde retreatment showed a faster healing rate in the first group. This can be explained by slower healing dynamics in the orthograde retreatment in which the lesion in not radically removed. Anyway there was not any statistically significant difference between the groups at 24 months.

Conflict of interest

The authors have no conflicts of interest to declare.

References

1. Saunders WR. Considerations in the revision of previous surgical procedures. *Endod Top* 2005;**11**:206—18.
2. Buchanan LS. The standardized-taper root canal preparation — Part 1. Concepts for variably tapered shaping instruments. *Int Endod J* 2000;**33**:516—29.
3. Cailleteau JG, Mullaney TP. Prevalence of teaching apical patency and various instrumentation and obturation techniques in United States dental schools. *J Endod* 1997;**23**:394—6.
4. Nair PN, Henry S, Cano V, Vera J. Microbial status of apical root canal system of human mandibular first molars with primary apical periodontitis after "one-visit" endodontic treatment. *Oral Surg Oral Med Oral Pathol Oral Radiol Endod* 2005;**99**: 231—52.
5. Friedman S. Treatment outcome: the potential for healing and retained function. In: Ingle JI, editor. *Endodontics*. 6th ed. Hamilton, Ontario: BC Decker; 2008.
6. Molven O, Olsen L, Kerekes K. Scanning electron microscopy of bacteria in the apical part of root canals in permanent teeth with periapical lesions. *Endod Dent Traumatol* 1991;**7**:226—9.
7. Reit C, Hirsch J. Surgical endodontic retreatment. *Int Endod J* 1986;**19**:107—12.
8. Rubinstein RA, Kim S. Short-term observation of the results of endodontic surgery with the use of a surgical operation microscope and super-EBA as root-end filling material. *J Endod* 1999;**25**:43—8.
9. World Medical Association Declaration of Helsinki: ethical principles for medical research involving human subjects. *JAMA* 2013;**310**:2191—4.
10. Vandenbroucke JP, von Elm E, Altman DG, Gøtzsche PC, Mulrow CD, Pocock SJ, et al. Strengthening the Reporting of Observational Studies in Epidemiology (STROBE): explanation and elaboration. *PLoS Med* 2007;**4**:1628—54.
11. Pirani C, Friedman S, Gatto MR, Iacono F, Tinarelli V, Gandolfi MG, Prati C. Survival and periapical health after root canal treatment with carrier-based root fillings: Five-year retrospective assessment. *Int Endod J* 2017;**51**:178—88.
12. Ørstavik D, Kerekes K, Eriksen HM. The periapical index: a scoring system for radiographic assessment of apical periodontitis. *Endod Dent Traumatol* 1986;**2**:20—34.
13. Del Fabbro M, Taschieri S, Testori T, Francetti L, Weinstein R. Surgical versus non-surgical endodontic re-treatment for periradicular lesions. *Cochrane Database Syst Rev* 2007;CD005511.
14. Danin J, Strömberg T, Forsgren H, Linder LE, Ramsköld LO. Clinical management of nonhealing periradicular pathosis surgery versus endodontic retreatment. *Oral Surg Oral Med Oral Pathol Oral Radiol Endod* 1996;**82**:213—7.
15. Kvist T, Reit C. Results of endodontic retreatment: a randomized clinical study comparing surgical and nonsurgical procedures. *J Endod* 1999;**25**:814—7.
16. Kvist T, Reit C. Postoperative discomfort associated with surgical and nonsurgical endodontic retreatment. *Endod Dent Traumatol* 2000;**16**:71—4.
17. Torabinejad M, Corr R, Handysides R, Shabahang S. Outcomes of nonsurgical retreatment and endodontic surgery: a systematic review. *J Endod* 2009;**35**:930—7.
18. European Society of Endodontology. Quality guidelines for endodontic treatment. *Int Endod J* 1994;**27**:115—24.
19. Hepworth MJ, Friedman S. Treatment outcome of surgical and non-surgical management of endodontic failures. *J Can Dent Assoc* 1997;**63**:364—71.
20. Von Arx T. Failed root canals: the case for apicoectomy (Periradicular Surgery). *J Oral Maxil Surg* 2005;**63**:832—7.
21. Mitchell PJ, Pitt Ford TR, Torabinejad M, McDonald F. Osteoblast biocompatibility of mineral trioxide aggregate. *Biomaterials* 1999;**20**:167—73.
22. Torabinejad M, Hong CU, McDonald F, Pitt Ford TR. Physical and chemical properties of a new root-end filling material. *J Endod* 1995;**21**:349—53.
23. Torabinejad M, Higa RK, McKendry DJ, Pitt Ford TR. Dye leakage of four root end filling materials: effects of blood contamination. *J Endod* 1994;**20**:159—63.
24. Gandolfi MG, Sauro S, Mannocci F, Watson TF, Zanna S, Capoferri M, et al. New tetrasilicate cements as retrograde filling material: an in vitro study on fluid penetration. *J Endod* 2007;**33**: 742—5.
25. Gandolfi MG, Taddei P, Tinti A, Prati C. Apatite-forming ability (bioactivity) of ProRoot MTA. *Int Endod J* 2010;**43**:917—29.
26. Gandolfi MG, Taddei P, Modena E, Siboni F, Prati C. Biointeractivity-related versus chemi/physisorption-related apatite precursor-forming ability of current root end filling materials. *J Biomed Mater Res B Appl Biomater* 2013;**101**:1107—23.
27. Ng YL, Mann V, Rahbaran S, Lewsey J, Gulabivala K. Outcome of primary root canal treatment: systematic review of the literature — Part 1. Effects of study characteristics on probability of success. *Int Endod J* 2007;**40**:921—39.
28. Cheung GS. Survival of first-time nonsurgical root canal treatment performed in a dental teaching hospital. *Oral Surg Oral Med Oral Pathol Oral Radiol Endod* 2002;**93**:596—604.
29. Wu MK, Shemesh H, Wesselink PR. Limitations of previously published systematic reviews evaluating the outcome of endodontic treatment. *Int Endod J* 2009;**42**:656—66.
30. Gandolfi MG, Iacono F, Agee K, Siboni F, Tay F, Pashley DH, et al. Setting time and expansion in different soaking media of experimental accelerated calcium-silicate cements and ProRoot MTA. *Oral Surg Oral Med Oral Pathol Oral Radiol Endod* 2009;**108**:39—45.
31. Tsesis I, Rosen E, Tamse A, Taschieri S, Del Fabbro M. Effect of guided tissue regeneration on the outcome of surgical endodontic treatment: a systematic review and meta-analysis. *J Endod* 2011;**37**:1039—45.

32. Grzesik WJ, Narayanan AS. Cementum and periodontal wound healing and regeneration. *Crit Rev Oral Biol Med* 2002;**13**:474—84.
33. Andreasen JO, Rud J. Modes of healing histologically after endodontic surgery in 70 cases. *Int J Oral Surg* 1972;**1**:148—60.
34. Taschieri S, Del Fabbro M, Francetti L, Perondi I, Corbella S. Does the papilla preservation flap technique induce soft tissue modifications over time in endodontic surgery procedures? *J Endod* 2016;**42**:1191—5.
35. Jonasson P, Lennholm C, Kvist T. Retrograde root canal treatment: a prospective case series. *Int Endod J* 2017;**50**(6):515—21.
36. Prati C, Pirani C, Zamparini F, Gatto MR, Gandolfi MG. A 20-year historical prospective cohort study of root canal treatments. A Multilevel analysis. *Int Endod J* 2018. http://dx.doi.org/http://dx.doi.org/10.1111/iej.12908 [In press].

Giornale Italiano di Endodonzia (2018) **32**, 9—16

Available online at www.sciencedirect.com

ScienceDirect

journal homepage: www.elsevier.com/locate/gie

ORIGINAL ARTICLE/ARTICOLO ORIGINALE

Revascularization versus apical barrier technique with mineral trioxide aggregate plug: A systematic review

Rivascolarizzazione contro tecnica della barriera apicale con tappo di MTA: una revisione sistematica

Luiz Alexandre Chisini [a,d,*], Guillermo Grazioli [a,b], Alejandro Francia [a,c], Alissa Schmidt San Martin [a], Flavio Fernando Demarco [a], Marcus Cristian Muniz Conde [d]

[a] *Graduate Program in Dentistry, School of Dentistry, Federal University of Pelotas, Department of Restorative Dentistry, 457, Gonçalves Chaves St. 5th floor, Pelotas 96015560, Brazil*
[b] *School of Dentistry, University of the Republic, Department of Dental Materials, 1925, Las Heras St., Montevideo, Uruguay*
[c] *School of Dentistry, University of the Republic, Department of Physiology, 1925, Las Heras St., Montevideo, Uruguay*
[d] *Graduate Program in Dentistry, School of Dentistry, University Vale do Taquari — Univates, Department of Restorative Dentistry, 171, Avelino Talini, Universitário, Lajeado 95900-000, Brazil*

Received 31 July 2017; accepted 22 March 2018
Available online 20 April 2018

KEYWORDS
Apexification;
Mineral trioxide aggregate;
Revascularization.

Abstract
Aim: To compare the clinical and radiographic outcomes observed in Necrotic Immature Permanent Teeth (NIPT) after revascularization or apexification with MTA-apical plug.
Methodology: PubMed/MEDLINE, Web of science and Scopus were the databases used, up to July 30th, 2017, for article research. Independent reviewers read the titles and abstracts of all reports that met inclusion/exclusion criteria: prospective or retrospective clinical studies comparing the revascularization of root canal and apexification. Clinical success of therapies, deposition and thickening of lateral dentinal walls (root width) and the continuation of root development (root

* Corresponding author.
E-mail: alexandrechisini@gmail.com (L.A. Chisini).
Peer review under responsibility of Società Italiana di Endodonzia.

Production and hosting by Elsevier

https://doi.org/10.1016/j.gien.2018.03.006
1121-4171/© 2018 Società Italiana di Endodonzia. Production and hosting by Elsevier B.V. This is an open access article under the CC BY-NC-ND license (http://creativecommons.org/licenses/by-nc-nd/4.0/).

PAROLE CHIAVE
Apecificazione;
Mineral trioxide aggregate;
Rivascolarizzazione.

length) were investigated. Bias risk of included studies was assessed using the Cochrane risk of bias.
Results: From 1642 records, five papers fulfilled all inclusion criteria. Overall, 91 teeth were submitted to revascularization and 64 teeth to apexification with MTA. The mean follow-up was 23.2 months in revascularization and 21.8 in apexification. Clinical success rate was of 87.9% in the revascularization group and 90.6% in the apexification group. An increase on lateral dentinal walls thickening was observed in most revascularization cases (13%) while MTA as apical plug suggest a mild resorption of the root (−1.3%). High bias risk was observed on included studies.
Conclusions: Apexification with MTA-apical plug provides similar clinical success to revascularization. However, radiographic measurements showed an improvement in thickening of lateral dentinal walls in most of the revascularization cases in addition to a higher dental development. However, these results should be interpreted with caution.
© 2018 Società Italiana di Endodonzia. Production and hosting by Elsevier B.V. This is an open access article under the CC BY-NC-ND license (http://creativecommons.org/licenses/by-nc-nd/4.0/).

Riassunto
Obiettivi: Confrontare gli esiti clinici e radiografici osservati nei denti necrotici permanenti immaturi (NIPT) dopo rivascolarizzazione o apecificazione con un tappo apicale di MTA.
Materiali e metodi: PubMed/MEDLINE, Web of science e Scopus sono stati i database utilizzati fino al 30 luglio 2017 per la ricerca di articoli. Revisori indipendenti hanno letto i titoli e gli abstract di tutti i report che hanno soddisfatto i criteri di inclusione/esclusione: studi clinici prospettici o retrospettivi che hanno confrontato la rivascolarizzazione del canale radicolare e l'apecificazione. Sono stati studiati il successo clinico delle terapie, la deposizione e l'ispessimento delle pareti dentinali laterali (larghezza della radice) e la continuazione dello sviluppo della radice (lunghezza della radice). Il rischio di *bias* degli studi inclusi è stato valutato utilizzando il rischio di *bias* di *Cochrane*.
Risultati: Di 1.642 documenti, cinque articoli soddisfano tutti i criteri di inclusione. Complessivamente, 91 denti sono stati sottoposti a rivascolarizzazione e 64 denti all'apecificazione con MTA. Il follow-up medio è stato di 23,2 mesi per la rivascolarizzazione e 21,8 per la apecificazione. Il tasso di successo clinico è stato dell'87,9% nel gruppo di rivascolarizzazione e del 90,6% nel gruppo di apecificazione. Un aumento dell'ispessimento delle pareti dentinali laterali è stato osservato nella maggior parte dei casi di rivascolarizzazione (13%) mentre l'uso di MTA come tappo apicale riporta un lieve riassorbimento della radice (−1,3%). Un elevato rischio di *bias* è stato osservato per gli studi inclusi.
Conclusioni: L'apecificazione con il tappo apicale di MTA fornisce un successo clinico simile alla rivascolarizzazione. Tuttavia, le misurazioni radiografiche hanno mostrato un miglioramento dell'ispessimento delle pareti dentinali laterali nella maggior parte dei casi di rivascolarizzazione oltre a uno sviluppo dentale superiore. Tuttavia, questi risultati dovrebbero essere interpretati con cautela.
© 2018 Società Italiana di Endodonzia. Production and hosting by Elsevier B.V. Cet article est publié en Open Access sous licence CC BY-NC-ND (http://creativecommons.org/licenses/by-nc-nd/4.0/)

Introduction

Traditionally, when pulp tissue undergoes necrosis a conventional endodontic therapy (CET) is performed, but despite good prognosis and favorable results observed [1], it comprises a challenging task to be carried out in necrotic immature permanent teeth (NIPT). NIPT possess thin root walls with a wide apical foramen, hampering to create an adequate apical stop [2].

Apexification is an indicated technique to manage NIPT since it induces a calcified barrier at the immature apex performed in several clinical appointments [3,4]. This technique comprises removal of the necrotic tissue followed by debridement of the canal and use of disinfection solution (such as sodium hypochlorite) to control the infection. Thus, several placements of a medicament able to induce a calcified barrier in a root with an open Apex is needed, thus, a subsequent condensation of gutta-percha can be properly achieved [3,4]. Calcium hydroxide — $Ca(OH)_2$ — is the most used material in apexification to develop the apical barrier due to biological and healing performances. However, apexification with $Ca(OH)_2$ presents considerable drawbacks such as increased risk of root fracture and poor patient compliance due to the extended treatment time, since is need a range of approximately 5 to 20 months to apical barrier formation [5]. Therefore, in addition to risk of fracture, the vulnerability of the temporary coronal restoration to re-infection is a great challenge [5]. The apical barrier technique using an apical plug of MTA has been reported as an alternative to long-term $Ca(OH)_2$ application by presenting shorter treatment time and higher predictability for apical closure [6]. In this tech-

nique, the treatment can be performed in one-single visit, providing biocompatibility, bacteriostatic action and favourable sealing ability [6]. Similarly to apexification, the necrotic pulp is removed and debridement and disinfection of the canal is performed. In this stage, MTA is employed in the canal as an apical plug [6]. MTA apical plug offers an effective barrier at the end of the root canal allowing vertical condensation of warm guttapercha in the remainder of the canal [6]. Although clinical trials have shown the efficacy of apexification, literature has documented apical closure, but no root elongation or maturation of the apical region [2].

In such context, revascularization aims to induce the maturation of root apex on NIPT, relying on root canal decontamination and subsequent induction of bleeding from the periapical tissue. Briefly, decontamination is performed with irrigant (such as sodium hypochlorite - 0.5% to 6% - or chlorhexidine), mild mechanical debridement of the root canal (because mechanical instrumentation is contraindicated) and antibiotic slurries (traditionally the triple antibiotic paste -TAP - metronidazole, ciprofloxacin, and minocycline) [7—9]. Ethylenediaminetetraacetic acid (EDTA) has been also indicated because it showed to promote the release of growth factors embedded in dentine. After that, subsequent induction of bleeding from the periapical tissue is performed [7—9]. The blood is stimulated with the use of a file. Thus, blood fills the root canal and coagulates forming a natural scaffold (which will serve as an anchorage site for cells from the apical region), which is subsequently covered with MTA [9].

Thenceforth, revascularization has been an important alternative for NIPT treatment showing good clinical results in several clinical studies [9—15]. Studies have shown that tissues formed in the root canal comprised vital pulp-like tissues with blood vessels, bone and cementum deposition and few inflammatory cells without dentin deposition [16—19]. Thus, this new tissue deposited can provide an increase in root canal length and thickening of lateral dentinal walls generating apical closure, as well as a high deposition of mineralized tissue observed radiographically [20,21], which is not possible with apexification treatment. However, revascularization is still a not well-established therapy since very little is known about the exact outcomes in the long term [2].

Thus, the objective of this study was to conduct a systematic literature review comparing clinical and radiographic outcomes observed in NIPT after revascularization or apexification using apical barrier technique with an MTA apical plug.

Methodology

This systematic review is reported in accordance with PRISMA Statement guidelines [22].

Eligibility criteria

In this systematic review studies with randomized controlled clinical trials design as well as prospective or retrospective clinical trials were included. To be eligible, studies should compare the revascularization of root canal and apexification with MTA-apical plug. No restriction of language was performed, however, studies *in vitro*, letters to editor and reviews were not include in the present study.

Table 1 Structured search strategy carried in databases.

Search syntaxes	
PubMed	
#1	((“clinical” [Title/Abstract] AND “trial” [Title/Abstract]) OR “clinical trials” [MeSH Terms] OR “clinical trial” [Publication Type] OR random[a] [Title/Abstract] OR “random allocation” [MeSH Terms] OR “Longitudinal Studies” [MeSH Terms] OR “Longitudinal Studies” [All Fields] OR “Longitudinal Study” [All Fields] OR “Studies, Longitudinal” [All Fields] OR “Study, Longitudinal” [All Fields] OR “Retrospective Studies” [MeSH Terms] OR “Studies, Retrospective” [All Fields] OR “Study, Retrospective” [All Fields] OR “Retrospective Study” [All Fields] OR “Clinical Evaluation” [All Fields] OR “Follow-up” [All Fields])
#2	“Immature Permanent Teeth” [All Fields]
#3	“Root Canal Revascularization” [All Fields] OR Revascularization [All Fields] OR Maturogenesis [All Fields]
#4	“apexification” [MeSH Terms] OR “apexification” [All Fields] OR “Apexifications” [All Fields] OR “Apexogenesis” [All Fields] OR (“apexification” [MeSH Terms] OR “apexification” [All Fields])
#5	“Mineral trioxide aggregate” [Supplementary Concept] OR “mineral trioxide aggregate” [All Fields]

[a] Searches were combined in each database.

Outcomes

The outcomes of this review were: clinical success of therapies (revascularization vs. apexification with MTA apical plug), deposition and thickening of lateral dentinal walls (root width) and the continuation of root development (root length).

Strategy of search

An electronic search was conducted in PubMed/MEDLINE, Web of Science and Scopus databases up to July 30th, 2017 following the inclusion criteria. The search structures followed Table 1, to answer the questions “Which technique (revascularization or apexification with MTA) provides higher clinical success?” and “Is revascularization able to promote higher deposition of mineral tissue and continuation of root development compared to apexification with MTA?”, based in the PICO model:

- Population: only human subjects
- Intervention: performing revascularization relying on blood clot formation after induced periapical bleeding
- Comparison: apexification of root canal using the barrier technique with MTA as apical plug
- Outcomes: clinical success, radiographic deposition of mineral tissue on root walls and continuation of root development.

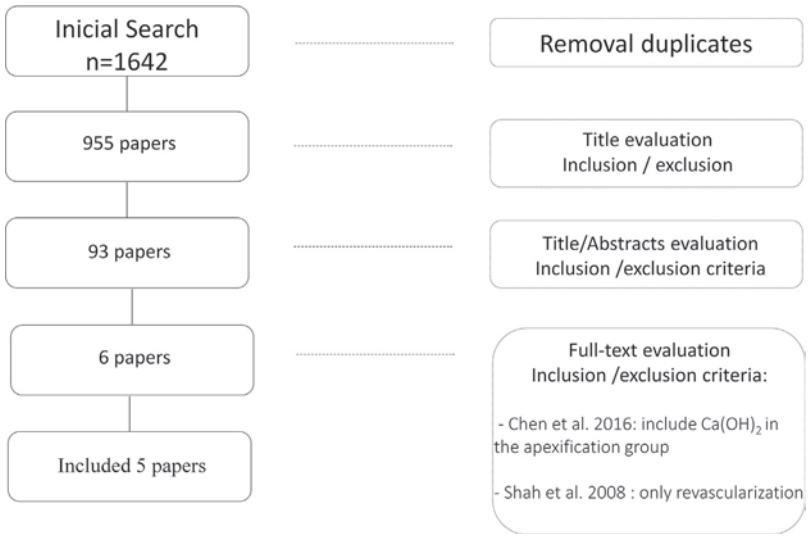

Figure 1 Prisma diagram flow.

Study selection

The records retrieved were uploaded into ENDNOTE® basic software (www.myendnoteweb.com), aiming to delete duplicates and to build up a virtual library (VL). Two independent reviewers (LAC and GG) read the titles and abstracts of all reports identified throughout the electronic searches, following the inclusion/exclusion criteria. Discrepancies between the reviewers were discussed to reach a consensus. In disagreement, a third reviewer decided (MCMC). Studies that filled the eligibility criteria were included in the review and processed for data extraction.

Table 2 Characteristics of included studies.

Author	Jeeruphan et al. [6]	Alobaid et al. [18]	Nagy et al. [23]	Narang et al. [24]	Silujjai et al. [17]
Study design	Retrospective	Retrospective	Prospective	Prospective and randomized	Restrospective
Number of teeth	Rev: 20; Ap: 19	Rev: 19; Ap: 5	Rev: 20; Ap: 9	Rev: 15; Ap: 5	Rev: 17; Ap: 26
Follow-up	Rev: 21 M; Ap: 14 M	17 M	18 M	18 M	Rev: 35 M; Ap: 49 M
Etiology of pulp necrosis	NR	Trauma, caries and *dens evaginatus*	NR	NR	Trauma, caries and *dens evaginatus*
Intracanal medication	TAP	$Ca(OH)_2$/TAP/DAP	Metronizadole, Ciprofloxacin, Doxycycline	TAP	TAP
Irrigation	2.25% NaOCl	NaOCl and chlorhexidine	Sodium hypochlorite 2.6%	2.5% NaOCl	1.5%—2.5% NaOCl and 17% EDTA
Clinical success	Rev: 20/20; Ap: 18/19	REV: 15/19; Ap: 5/5	Rev: 17/20; Ap: 9/9	Rev: 15/15; Ap: 5/5	Rev: 13/17; Ap: 21/26
Vitality pulp test	NR	NR	NR	NR	NR
Thickening of lateral dentinal walls (root width)	Rev 28.2%; Ap: 0%	Rev 10.2%; Ap: 1.4%	Rev 0.31%; Ap: 0.0%	NR	Rev 13.8%; Ap: −3.3%
Continuation of dental development (root length)	Rev: 14.9%; Ap: 6.1%	Rev: NE; Ap: NE Similar results	Rev: 1.25%; Ap: 0%	NR	Rev: 9.5%; Ap: 8.5%

Legend: Revascularization (Rev); mineral trioxide aggregate (MTA); apexification with mineral trioxide aggregate (Ap); triple antibiotic paste (TAP); double antibiotic paste (DAP); no reported (NR); no specified (NE); sodium hypochlorite (NaOCl); calcium hydroxide ($Ca(OH)_2$); months (M).

The reasons for exclusion were justified and reported in the flow chart (Fig. 1).

Data extraction

Data extraction was performed independently by two reviewers (LAC and GG). Disagreements were solved by discussion between reviewers. The mean follow-up, etiology of pulp necrosis, intracanal medication, irrigation solution, clinical and/or radiographic success, return of pulp vitality and deposition of dentinal walls thickening and root lengthening were collected (Table 2).

Bias risk

The bias risk of included studies was assessed using the Cochrane risk of bias tool. The bias tool considered were: judgment of the random sequence generation, allocation concealment, blinding of participants and personnel, blinding of outcome assessment, incomplete outcome data, selective reporting and other sources of bias [23].

Data analysis

Papers included showed a high heterogeneity regarding study design and evaluation criteria. Thus, a qualitative analysis was carried on extracted data.

Results

The initial research found 1642 records corresponding to 955 studies. The titles of the studies were evaluated and 93 were selected for abstract evaluation. After full-text evaluation, five papers fulfilled all inclusion criteria and two [24,25] were excluded (Fig. 1). In relation to study design, three studies were retrospective [6,20,21] and two prospective [11,26], of which only one is a clinical trial [11]. Overall, 91 teeth were submitted to revascularization and 64 teeth to apexification with MTA (Table 2).

The follow-up ranged from 17 to 35 months (mean 23.2) in the revascularization groups and 14—49 months (mean 21.8) in the MTA apexification group. Intracanal irrigation was performed in all studies with sodium hypochlorite, whilst Alobaid et al. [21] also used chlorhexidine and Silujjai et al. [20] used EDTA 17%. In addition, a considerable variation of intracanal medication was observed, with the use of double [21] and triple antibiotic paste (DAP-TAP) [6,11,20,21], even as $Ca(OH)_2$ [21]. Etiology of pulp necrosis was reported only in two studies [20,21] they reported trauma, caries and *dens evaginatus* as reasons for the necrosis.

Thus, a clinical success rate of 87.9% ($n = 80$) in the revascularization group was observed and 90.6% ($n = 58$) in the apexification. Although no study evaluated the pulp vitality after revascularization procedure, a considerable increase on thickening of lateral dentinal walls was showed in most of revascularization cases (pondered mean = 13%) while apical barrier technique with MTA as apical plug showed an inferior outcome (pondered mean = −1.3%), also suggesting a mild resorption of the root. Similarly, continuation of dental development was higher in the revascularization group (pondered mean = 8.5%) compared to the MTA apexification group (pondered mean = 5.2%).

Regarding the bias risk, a high bias risk of the included studies was observed (Fig. 2). Allocation concealment, blinding of participants and personnel and selective reporting presented the highest risk of bias while blinding of outcome assessment and incomplete outcome data presented the lowest risk.

Discussion

The main objective of revascularization is to generate a new pulp-like tissue inside the root canal to restore the tooth physiology and to reduce significantly the risk of tooth loss [10,27—30]. Therefore, it was observed that revascularization was slightly more effective than apexification through MTA apical barrier technique, providing an increase of the thickness of lateral dentinal walls and promoting the continuation of dental development. The global success rate showed equivalent results between revascularization and apexification through MTA apical barrier technique.

The unfavorable results regarding the survival rate in MTA were mostly related to non-restorable dental fracture [6,20], while revascularization failure was mostly related to a persistent infection [6,20]. Nagy et al. [26] reported that 3 teeth exhibited clinical and radiographic fail signs during examination while being treated with apexification. Alobaid et al. [21] described 4 failures in the revascularization group, of which one tooth failed due to trauma, needing to be extracted because of a complicated facture. The other failures were due to persistent infection of root canal systems, requiring a new endodontic reintervention. Extensive mechanical instrumentation is contraindicated in NIPT as it can make teeth more susceptible to fracture [2,9]. In this context, disinfection of radicular system canals is a crucial step in regenerative endodontics, which is mainly obtained by disinfectant solutions and intracanal medications [8,10]. Moreover, periapical tissues around immature teeth present a rich blood supply and a specific population of stem cells named stem cells from apical papilla (SCAP) that possess potential to regenerate tissue in response to injury [30]. If a sterile tissue matrix is present, providing an optimal environment for cells adhesion, proliferation and differentiation, pulp vitality can be restored [31,32].

While several irrigation solutions and intracanal medication can be employed in revascularization [8,10], the studies included in the present review employed the sodium hypochlorite as main irrigation solution [6,11,20,21,26] along with TAP [6,11,20] and their modifications [21,26] to obtain canal decontamination. The modifications of TAP are used to avoid tooth discoloration caused by the conventional paste [10]. Hoshinoet al et al. [33] showed that a TAP composed by ciprofloxacin, metronidazole and minocycline presented bactericidal effect against the colonizing-dentin microorganisms *in vitro*. Iwaya et al. [34] described a technique applying such TAP and observed an increase of thickening of the root dentinal walls. Some years later, a new procedure to disinfect NIPT root canals was published, which consisted on root disinfection with 5.25% sodium hypochlorite (NaOCl) irrigation without root instrumentation [35] and this protocol has been the most employed ever since [10].

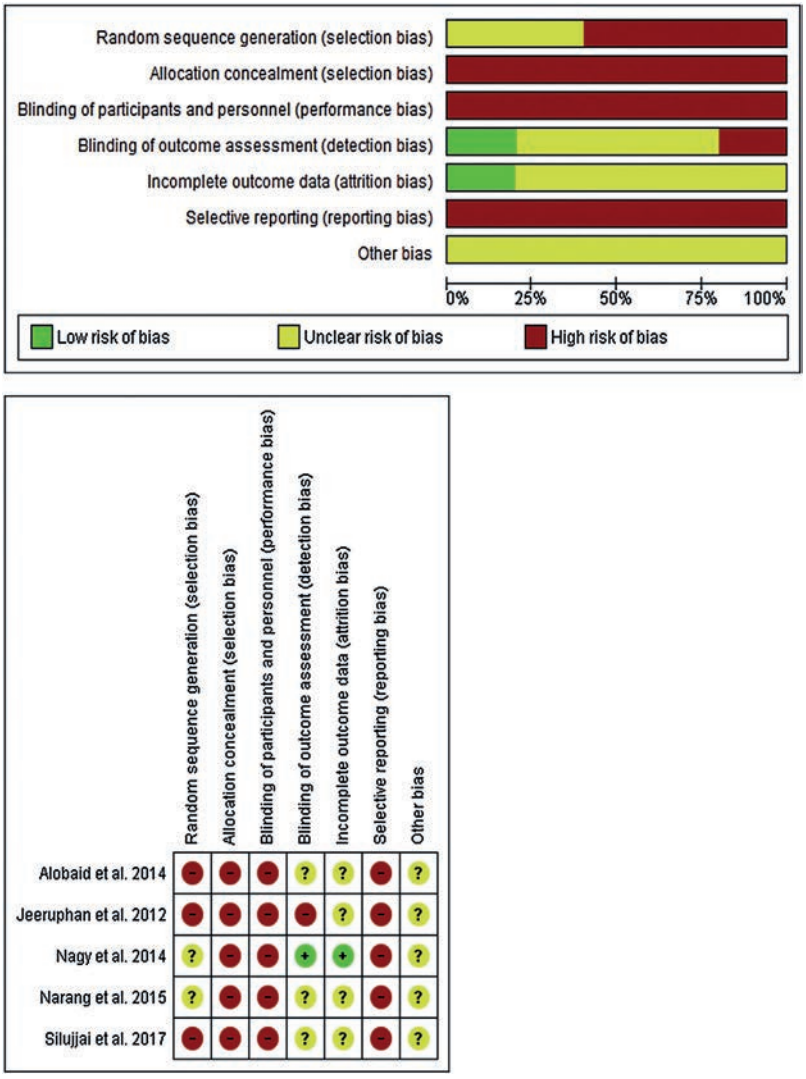

Figure 2 Bias risk of included studies.

Although the studies showed that TAP and their modifications can be effective to provide a sterile environment, some failures were observed due to reinfection of the canal, maybe due to residual bacteria in the root canal, effectively observed in histological analyses [16,21]. These variations in the ability to promote an effective disinfection could be explained by the different concentrations of the intracanal paste used. While the included studies did not report the final concentrations of the antibiotic paste, the American Association of Endodontists recommended the use of antibiotic pastes at a concentration ranging from 0.1 to 1 mg/mL [7]. This concentration seems to maintain the viability of stem cells from apical papilla, which will subsequently migrate and cling to the blood clot [7,10].

Blood clot acts as a natural scaffold, bringing a simple support for stem cell proliferation and differentiation [10,30]. It should act mimicking the original tissue and the extracellular matrix, which provides support for the cells presenting ligands and bioactive molecules to guide the stem cells behavior [36,37]. Fibrin present in the clot is a biopolymer, critical to hemostasis and wound healing, it serves as a natural scaffold to capture the blood cells and it contains in its structure ligand molecules [38]. When the induced bleeding starts inside the root canal, the evoked-bleeding enrolls the manipulation of the periapical tissues and this manipulation step seems to release stem cells from the surrounding tissues and results in their delivery to the canal system [39]. In such cases, fibrin is the main responsible for the blood clot formation and stabilization acting as a ''trap'' to retain SCAPs from apical site [39]. Recent studies have combined blood clot with a natural scaffold from platelet rich plasma (PRP) [13,40] and platelet rich fibrin (PRF) [11,41]. These blood concentrates showing a high range of biomolecules [42] can facilitate the migration of stem cells from apical papilla. Of the included studies, Narang et al. [11] also realized the revascularization both with PRP and PRF, describing that PRF showed better results of dentin wall thickness and continuation of root development than PRP, conventional revascularization and MTA apexification. Therefore, it was observed that the use of PRF could accelerate the potential of regeneration in NIPT [11].

In such context, revascularization seems to possess a range of advantages when compared to apexification with the apical barrier technique using MTA, including increased

thickening of the canal walls and continued root development, which was superior in the present systematic review. Histological and immuno-histochemical analyses in animals [43,44] and in humans [16—18] did not detect the presence of polarized cells resembling odontoblasts after revascularization [18,45]. Apical closure was generated by cellular/acellular cementum and bone-like tissue, expressing bone sialoprotein, instead of dentin sialoprotein [16,46,47]. However, it is important to highlight that the dental pulp is one of the most important biological structures of a tooth. Revascularization has revitalized teeth with irreversible pulpits and necrosis associated with apical periodontitis. Although this tissue seems not able to deposit dentin [16], observed mineralized tissue provides an increase in width and length of teeth and resolution of apical periodontitis.

The results of the present systematic review should be interpreted with caution, since it is based on studies with different methodological designs, limited sample and with high risk of bias. Thus, well-designed clinical trials comparing the two procedures should be conducted to provide more concise and safe information.

Conclusions

Apexification with the barrier technique using MTA-apical plug provides similar clinical success rate than revascularization. Moreover, radiographic measurements showed an improvement on thickening of lateral dentinal walls in most of the cases of revascularization. The continuation of dental development was also higher in the revascularization group. These results should be interpreted with caution.

Funding

This study has not founding sources.

Conflict of interest

The authors have no conflicts of interest to disclose.

References

1. Friedman S, Mor C. The success of endodontic therapy — healing and functionality. *J Calif Dent Assoc* 2004;**32**(6):493—503.
2. Andreasen JO, Farik B, Munksgaard EC. Long-term calcium hydroxide as a root canal dressing may increase risk of root fracture. *Dent Traumatol* 2002;**18**(3):134—7.
3. Bonte E, Beslot A, Boukpessi T, Lasfargues JJ. MTA versus $Ca(OH)_2$ in apexification of non-vital immature permanent teeth: a randomized clinical trial comparison. *Clin Oral Investig* 2015;**19**(6):1381—8.
4. Vidal K, Martin G, Lozano O, Salas M, Trigueros J, Aguilar G. Apical closure in apexification: a review and case report of apexification treatment of an immature permanent tooth with biodentine. *J Endod* 2016;**42**(5):730—4.
5. Moreno-Hidalgo MC, Caleza-Jimenez C, Mendoza-Mendoza A, Iglesias-Linares A. Revascularization of immature permanent teeth with apical periodontitis. *Int Endod J* 2014;**47**(4):321—31.
6. Jeeruphan T, Jantarat J, Yanpiset K, Suwannapan L, Khewsawai P, Hargreaves KM. Mahidol study 1: comparison of radiographic and survival outcomes of immature teeth treated with either regenerative endodontic or apexification methods: a retrospective study. *J Endod* 2012;**38**(10):1330—6.
7. AAE. AAE guide to clinical endodontics; 2016, http://www.aae.org/clinical-resources/aae-guide-to-clinical-endodontics.aspx.
8. Wigler R, Kaufman AY, Lin S, Steinbock N, Hazan-Molina H, Torneck CD. Revascularization: a treatment for permanent teeth with necrotic pulp and incomplete root development. *J Endod* 2013;**39**(3):319—26.
9. Llaquet M, Mercade M, Plotino G. Regenerative endodontic procedures: a review of the literature and a case report of an immature central incisor. *G Ital Endod* 2017;**31**.
10. Conde MC, Chisini LA, Sarkis-Onofre R, Schuch HS, Nor JE, Demarco FF. A scoping review of root canal revascularization: relevant aspects for clinical success and tissue formation. *Int Endod J* 2016.
11. Narang I, Mittal N, Mishra N. A comparative evaluation of the blood clot, platelet-rich plasma, and platelet-rich fibrin in regeneration of necrotic immature permanent teeth: a clinical study. *Contemp Clin Dent* 2015;**6**(1):63—8.
12. Bezgin T, Sonmez H, Orhan K, Ozalp N. Comparative evaluation of $Ca(OH)_2$ plus points and $Ca(OH)_2$ paste in apexification. *Dent Traumatol* 2012;**28**(6):488—95.
13. Bezgin T, Yilmaz AD, Çelik BN, Sönmez H. Concentrated platelet-rich plasma used in root canal revascularization: 2 case reports. *Int Endod J* 2014;**47**(1):41—9.
14. Bezgin T, Yilmaz AD, Celik BN, Kolsuz ME, Sonmez H. Efficacy of platelet-rich plasma as a scaffold in regenerative endodontic treatment. *J Endod* 2015;**41**(1):36—44.
15. Petrino JA, Boda KK, Shambarger S, Bowles WR, McClanahan SB. Challenges in regenerative endodontics: a case series. *J Endod* 2010;**36**(3):536—41.
16. Becerra P, Ricucci D, Loghin S, Gibbs JL, Lin LM. Histologic study of a human immature permanent premolar with chronic apical abscess after revascularization/revitalization. *J Endod* 2014;**40**(1):133—9.
17. Lei L, Chen Y, Zhou R, Huang X, Cai Z. Histologic and immunohistochemical findings of a human immature permanent tooth with apical periodontitis after regenerative endodontic treatment. *J Endod* 2015;**41**(7):1172—9.
18. Lin LM, Shimizu E, Gibbs JL, Loghin S, Ricucci D. Histologic and histobacteriologic observations of failed revascularization/revitalization therapy: a case report. *J Endod* 2014;**40**(2):291—5.
19. Martin G, Ricucci D, Gibbs JL, Lin LM. Histological findings of revascularized/revitalized immature permanent molar with apical periodontitis using platelet-rich plasma. *J Endod* 2013;**39**(1):138—44.
20. Silujjai J, Linsuwanont P. Treatment outcomes of apexification or revascularization in nonvital immature permanent teeth: a retrospective study. *J Endod* 2017;**43**(2):238—45.
21. Alobaid AS, Cortes LM, Lo J, Nguyen TT, Albert J, Abu-Melha AS, et al. Radiographic and clinical outcomes of the treatment of immature permanent teeth by revascularization or apexification: a pilot retrospective cohort study. *J Endod* 2014;**40**(8):1063—70.
22. Moher D, Liberati A, Tetzlaff J, Altman DG, Group P. Preferred reporting items for systematic reviews and meta-analyses: the PRISMA statement. *PLoS Med* 2009;**6**(7):e1000097.
23. Higgins J, Green S. Cochrane handbook for systematic reviews of interventions, version 5.1.0. London: The Cochrane Collaboration; 2011.
24. Chen SJ, Chen LP. Radiographic outcome of necrotic immature teeth treated with two endodontic techniques: a retrospective analysis. *Biomed J* 2016;**39**(5):366—71.
25. Shah N, Logani A, Bhaskar U, Aggarwal V. Efficacy of revascularization to induce apexification/apexogensis in infected, nonvital, immature teeth: a pilot clinical study. *J Endod* 2008;**34**(8):919—25. Discussion 1157.
26. Nagy MM, Tawfik HE, Hashem AA, Abu-Seida AM. Regenerative potential of immature permanent teeth with necrotic pulps after

different regenerative protocols. *J Endod* 2014;**40**(2):192—8. Available from:http://onlinelibrary.wiley.com/o/cochrane/clcentral/articles/866/CN-01118866/frame.html.
27. Chueh LH, Ho YC, Kuo TC, Lai WH, Chen YHM, Chiang CP. Regenerative endodontic treatment for necrotic immature permanent teeth. *J Endod* 2009;**35**(2):160—4.
28. Saoud TM, Martin G, Chen YHM, Chen KL, Chen CA, Songtrakul K, et al. Treatment of mature permanent teeth with necrotic pulps and apical periodontitis using regenerative endodontic procedures: a case series. *J Endod* 2016;**42**(1):57—65.
29. Shah N, Logani A, Bhaskar U, Aggarwal V. Efficacy of revascularization to induce apexification/apexogensis in infected, nonvital, immature teeth: a pilot clinical study. *J Endod* 2008;**34**(8):919—25.
30. Conde MC, Chisini LA, Demarco FF, Nor JE, Casagrande L, Tarquinio SB. Stem cell-based pulp tissue engineering: variables enrolled in translation from the bench to the bedside, a systematic review of literature. *Int Endod J* 2016;**49**(6):543—50.
31. Chisini LA, Conde MC, Alcazar JC, Silva AF, Nor JE, Tarquinio SB, et al. Immunohistochemical expression of TGF-beta1 and osteonectin in engineered and $Ca(OH)_2$-repaired human pulp tissues. *Braz Oral Res* 2016;**30**(1):e93.
32. Demarco FF, Conde MC, Cavalcanti BN, Casagrande L, Sakai VT, Nor JE. Dental pulp tissue engineering. *Braz Dent J* 2011;**22**(1):3—13.
33. Hoshino E, Kurihara-Ando N, Sato I, Uematsu H, Sato M, Kota K, et al. In-vitro antibacterial susceptibility of bacteria taken from infected root dentine to a mixture of ciprofloxacin, metronidazole and minocycline. *Int Endod J* 1996;**29**(2):125—30.
34. Iwaya SI, Ikawa M, Kubota M. Revascularization of an immature permanent tooth with apical periodontitis and sinus tract. *Dent Traumatol* 2001;**17**(4):185—7.
35. Banchs F, Trope M. Revascularization of immature permanent teeth with apical periodontitis: new treatment protocol? *J Endod* 2004;**30**(4):196—200.
36. Prescott RS, Alsanea R, Fayad MI, Johnson BR, Wenckus CS, Hao J, et al. In vivo generation of dental pulp-like tissue by using dental pulp stem cells, a collagen scaffold, and dentin matrix protein 1 after subcutaneous transplantation in mice. *J Endod* 2008;**34**(4):421—6.
37. Chisini LA, Karam SA, Noronha TG, Sartori LGM, San Martin AS, Demarco FF, et al. Platelet-poor plasma as a supplement for fibroblasts cultured in platelet-rich fibrin. *Acta Stomatol Croat* 2017;**51**(2):133—40.
38. Galler KM, Cavender AC, Koeklue U, Suggs LJ, Schmalz G, D'Souza RN. Bioengineering of dental stem cells in a PEGylated fibrin gel. *Regen Med* 2011;**6**(2):191—200.
39. Lovelace TW, Henry MA, Hargreaves KM, Diogenes A. Evaluation of the delivery of mesenchymal stem cells into the root canal space of necrotic immature teeth after clinical regenerative endodontic procedure. *J Endod* 2011;**37**(2):133—8.
40. Sachdeva GS, Sachdeva LT, Goel M, Bala S. Regenerative endodontic treatment of an immature tooth with a necrotic pulp and apical periodontitis using platelet-rich plasma (PRP) and mineral trioxide aggregate (MTA): a case report. *Int Endod J* 2015;**48**(9):902—10.
41. Keswani D, Pandey RK. Revascularization of an immature tooth with a necrotic pulp using platelet-rich fibrin: a case report. *Int Endod J* 2013;**46**(11):1096—104.
42. Kawase T. Platelet-rich plasma and its derivatives as promising bioactive materials for regenerative medicine: basic principles and concepts underlying recent advances. *Odontology* 2015;**103**(2):126—35.
43. da Silva LA, Nelson-Filho P, da Silva RA, Flores DS, Heilborn C, Johnson JD, et al. Revascularization and periapical repair after endodontic treatment using apical negative pressure irrigation versus conventional irrigation plus triantibiotic intracanal dressing in dogs' teeth with apical periodontitis. *Oral Surg Oral Med Oral Pathol Oral Radiol Endod* 2010;**109**(5):779—87.
44. Scarparo RK, Dondoni L, Bottcher DE, Grecca FS, Rockenbach MI, Batista Jr EL. Response to intracanal medication in immature teeth with pulp necrosis: an experimental model in rat molars. *J Endod* 2011;**37**(8):1069—73.
45. Nosrat A, Kolahdouzan A, Hosseini F, Mehrizi EA, Verma P, Torabinejad M. Histologic outcomes of uninfected human immature teeth treated with regenerative endodontics: 2 case reports. *J Endod* 2015;**41**(10):1725—9.
46. Demarco GT, Kirschnick LB, Watson LB, Conde MCM, Demarco FF, Chisini LA. What is the clinical applicability of regenerative therapies in dentistry? *Rev Gaúch Odontol* 2017;**65**(4):359—67.
47. Chisini LA, Conde MCM, Grazioli G, Martin ASS, Carvalho RV, Nor JE, Demarco FF. Venous blood derivatives as FBS-substitutes for mesenchymal stem cells: a systematic scoping review. *Braz Dent J* 2017;**28**(6):657—68.

Giornale Italiano di Endodonzia (2018) **32**, 17—24

Available online at www.sciencedirect.com

ScienceDirect

journal homepage: www.elsevier.com/locate/gie

ORIGINAL ARTICLE/ARTICOLO ORIGINALE

Improved single visit management of old infected iatrogenic root perforations using Biodentine®

Trattamento in singola visita delle « Old infected » perforazioni con Biodentine®

Davide Mancino [a,b,*], **Florent Meyer** [a,b], **Youssef Haikel** [a,b]

[a] *Université de Strasbourg, Inserm UMR1121 Biomatériaux et Bioingénierie, FMTS, F-67000 Strasbourg, France*
[b] *Hôpitaux universitaires de Strasbourg, F-67000 Strasbourg, France*

Received 7 February 2018; accepted 4 May 2018
Available online 24 May 2018

KEYWORDS
Iatrogenic perforation;
Acidic environnement;
Bioactivity;
Biodentine;
Single visit.

Abstract
Aim: The aim of this retrospective observational case series study was to evaluate the middle term outcomes on endodontic management of old infected iatrogenic root perforations using Biodentine. The treatments were always concluded in a single visit, without previous medication with calcium hydroxide. Our goal was to facilitate this kind of treatments and to make them more reproducible and manageable even for a general practitioner or a student.
Methodology and methods: Between January 2011 and June 2016, 51 patients with old infected root perforations have been enrolled. All the treatments were performed using Biodentine in a single visit. Infected root perforation repair was performed by supervised dental students (39%) or a qualified endodontist (61%), employing surgical microscope magnification during treatments. After the treatment, the 51 patients were monitored for 18—64 months. We used clinical and radiographic examinations.
Results: Of 51 examined teeth, 48 (94%) were classified as healed. The time, the size and the location of the perforations did not have a significant effect on the outcome. We proved the ineffectiveness of the null hypothesis. According to this latter, the single visit treatment of old infected perforations with Biodentine was inadequate.
Conclusions: In single visit treatments, Biodentine seems to provide a biocompatible and effective seal in acidic environment, in accidental root perforations, even if the treatment is

* Corresponding author at: Inserm UMR_S 1121: Biomaterials and Bioengineering, 11 rue Humann, 67000 Strasbourg, France.
E-mail: mancino@unistra.fr (D. Mancino).
Peer review under responsibility of Società Italiana di Endodonzia.

Production and hosting by Elsevier

https://doi.org/10.1016/j.gien.2018.05.001
1121-4171/© 2018 Società Italiana di Endodonzia. Production and hosting by Elsevier B.V. This is an open access article under the CC BY-NC-ND license (http://creativecommons.org/licenses/by-nc-nd/4.0/).

performed by an inexperienced operator and regardless of the location, the size and the time of occurrence of the perforation.
© 2018 Società Italiana di Endodonzia. Production and hosting by Elsevier B.V. This is an open access article under the CC BY-NC-ND license (http://creativecommons.org/licenses/by-nc-nd/4.0/).

PAROLE CHIAVE
Perforazione iatrogena;
Ambiente acido;
Bioattività;
Biodentine;
Singola visita.

Riassunto
Obiettivi: Lo scopo di questo studio osservazionale retrospettivo è stato quello di valutare la percentuale di guarigione a medio termine nel trattamento delle ''old infected'' perforazioni con contaminazione batterica usando biodentine. Il trattamento di tutte le perforazioni è stato fatto in seduta singola, senza medicazione con idrossido di calcio. Altro obiettivo è stato quello di facilitare questo tipo di trattamenti, rendendoli riproducibili e fattibili anche per un dentista generico o uno studente.
Materiali e metodi: Tra Gennaio 2011 e Giugno 2016, abbiamo selezionato 51 pazienti con ''old infected'' perforationi. Ogni caso é stato trattato con Biodentine in singola seduta. Il 39% dei casi é stato trattato da studenti della clinica universitaria sotto la supervisione di un tutor senior, mentre il 61% da un endodontista qualificato, usando il microscopio operatorio durante ogni fase del trattamento. Dopo il trattamento, i 51 pazienti sono stati monitorati tra 18 e 64 mesi, con esami radiografici e clinici.
Risultati: Fra i 51 denti esaminati, 48 (94%) sono stati classificati come guariti. Nel nostro studio il tempo, la dimensione e la localizzazione della perforazione non hanno avuto alcun valore prognostico. Abbiamo dunque rigettato l'ipotesi nulla, secondo la quale il trattamento in singola visita delle ''old infected'' perforazioni con Biodentine fosse inadequato.
Conclusioni: Il trattamento delle ''old infected'' perforazioni in ambiente acido in singola visita con Biodentine sembra assicurare un sigillo biocompatibile e tridimensionale della perforazione anche se il trattamento è stato eseguito da operatori senza tanta esperienza (studenti), indipendentemente dalla localizzazione, dimensione e tempo dell'avvenuta perforazione.
© 2018 Società Italiana di Endodonzia. Production and hosting by Elsevier B.V. Cet article est publié en Open Access sous licence CC BY-NC-ND (http://creativecommons.org/licenses/by-nc-nd/4.0/)

Introduction

Iatrogenic root perforations, resulting from the destruction of the dentine root wall or floor along with the underlying cementum, are defined as mechanical communications defects between the root canal system and the external tooth surface. Such injury of the periodontium leads to localized inflammation and infection, triggering the destruction of periodontal fibers, bone resorption, and the formation of granulomatous tissue. Eventually proliferation of oral mucosa epithelium and development of a periodontal pocket jeopardizes tooth survival. According to Fuss and Trope, the prognosis is particularly poor with larger and older perforations. But above all, the location of the perforation is a key determinant, with particularly bad prognosis for crestal perforations [1].

To prevent or treat periradicular inflammation following root perforation, the standard treatment is sealing the perforation with a bioceramic-based material using orthograde access [2—4]. Success depends mainly on proper cleaning of perforation site and complete tridimensional sealing. Mineral trioxide aggregate (MTA) is the standard material used to seal perforations. The procedure, in case of infection and inflammation, is typically divided in two steps. The first visit involves cleaning and temporarily sealing the perforation with calcium hydroxide. The second visit (usually ∼1 week later) involves placing a definitive MTA seal. Several benefits of MTA include biocompatibility, osteoconductivity, and the promotion of cementum regeneration. Several drawbacks make MTA less suitable for large crestal and/or infected perforations [5—15]. Disadvantages of MTA include its long setting time, compromising the application in large crestal cases. Use of MTA can lead to tooth discoloration. In addition, the local pH variations, acidic in case of an inflammation, can influence material setting [12,15—19]. Finally, MTA handling requires practice. Particularly challenging is performing complete three-dimensional sealing of deep cavities [20]. Biodentine® (Septodont, Saint Maur des Fosses, France) a silicate loaded bioceramic has emerged as an effective cement in several endodontic procedures. Biodentine® biocompatibility and osteoconductivity properties are equal to MTA, but thanks to its properties Biodentine is easier to handle. Its chemical qualities also make it more efficient in acidic environment. Collectively, Biodentine® might provide clear advantage in the treatment of older perforations [21—24]. To assess this hypothesis clinically, we performed a prospective case series study using reports on outcomes of infected old iatrogenic root perforations referred to our university dental hospital and treated either by supervised dental students, or by a qualified endodontist.

Material and methods

Study design

We performed a retrospective observational study based on documented cases of old infected root perforation (more that 6 months beforehand) treated in the Department of Endodontics at the Strasbourg University Dental Hospital (Pôle de Médicine et Chirurgie Bucco-dentaires, Hôpitaux Universitaires de Strasbourg, Strasbourg, France). Patients were treated by direct sealing with Biodentine® in a single visit. The patient enrolment took place place from January 2011 to June 2016. Analyses were based on the clinical records and radiographic examination.

Case selection

Cases were selected based on the following criteria:
- Presence of iatrogenic root perforation.
- Signs of infection (either by probing (negative $\leq$4 mm, positive $>$4 mm), presence of sinus tract, swelling, and bone radiolucency).
- No previous treatment of the perforation.
- Time lapse between perforation injury and its repair was 6 months or more.
- Immunocompetent adults above 18 years of age.
- Complete medical and dental history were available.

Diagnosis of perforation

The correct diagnosis of the presence and localization of an iatrogenic root perforation was made using one or more of the following signs or tools:
- visualization with surgical microscope;
- periodontal probing;
- sudden bleeding;
- radiographic analysis (including fistulography);
- apex locator.

Single step treatment of iatrogenic root perforations

All procedures were done in conformity with current state of the art practices in endodontic. These included effective local anesthesia, appropriate tooth restoration to insure watertight rubber dam installation, and surgical microscopic manipulations for precision (Leika M320).

Procedures began with locating the perforation, then infected dentin was removed with minor enlargements using endodontic ultrasonic tips of different diameters according to the perforation size (Pro-Ultra®, StartX®, Dentsply-Sirona). In some cases, when granulation tissue invaded the perforation site, surgical removal was performed using cautery knife (Satelec). Then, keeping the pulp chamber constantly flooded with 6% sodium hypochlorite (Coltene), root canal shaping was performed using either Protaper Universal or Protaper Next (Dentsply-Sirona) instruments. Irrigation helps in perforation disinfection and hemostasis. In case of a large osseous defect and/or when bleeding is still occurring, after sodium hypochlorite irrigation small pieces of resorbable collagen matrix (Pangen, URGO Medical) are used to stop the bleeding. The perforation site was then dried with sterile cotton pellets and/or sterile paper points. In the case of lateral root perforation, the site was always sealed before root canal filling, allowing a 12 min lag time between the two procedures to insure adequate Biodentine® setting. In the case of furcal perforations, perforation filling was performed either before or after root canal filling. When performed before root canal filling, a high taper paper point was used to fill root canal to avoid Biodentine® contamination. Otherwise the perforation site was protected from endodontic sealer or guttapercha contamination using sterile cotton pellets. Biodentine® was mixed according to manufacturers instructions. The material was inserted into the teeth with a spatula then pushed into the perforation using microbrushes (Figs. 1 and 2). In two examples, when the perforation site was very close to the apical foramen, we filled both the perforation and the root canal with Biodentine (Fig. 3).

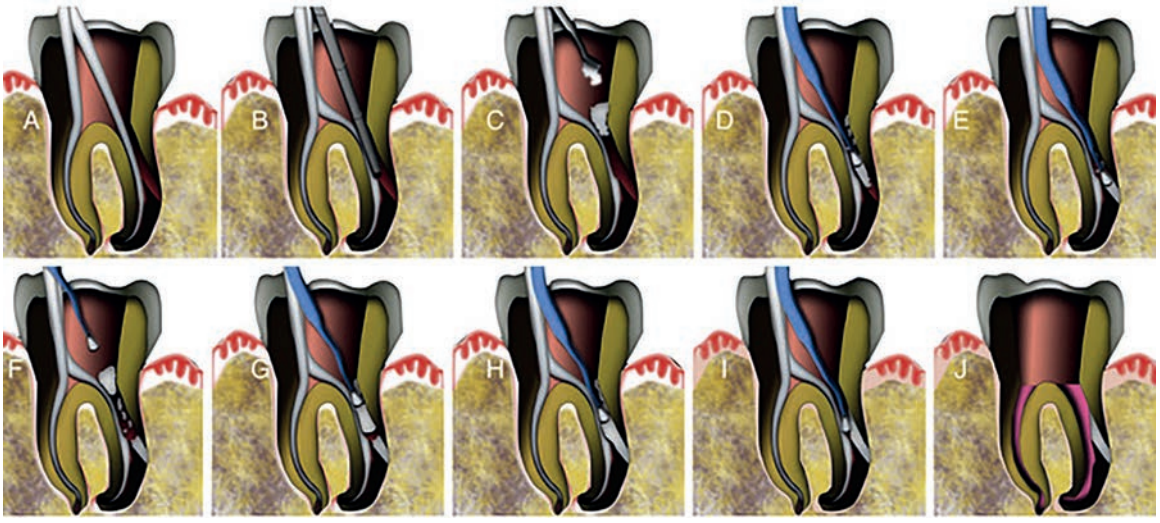

Figure 1 (A—J) Lateral root perforation management procedure.

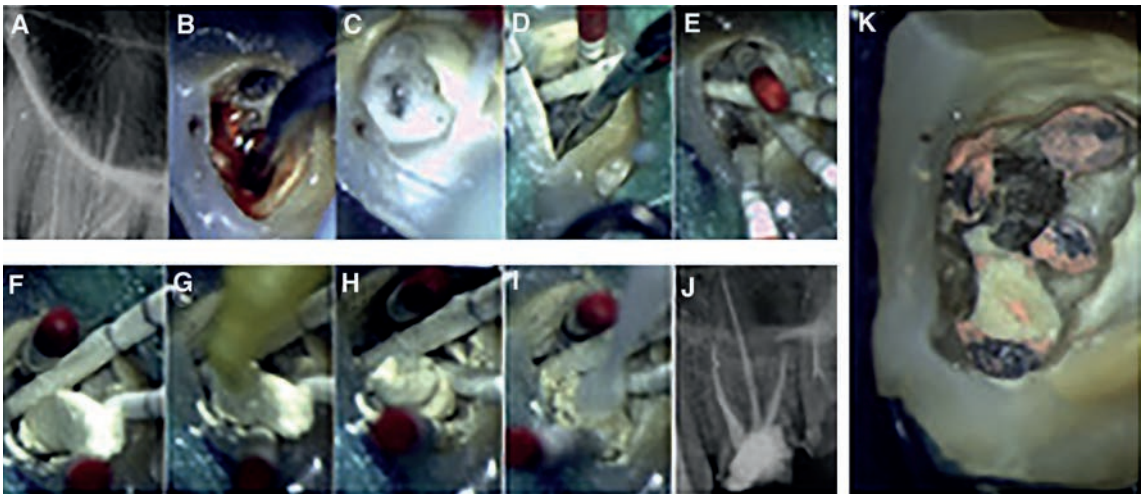

Figure 2 (A) K file highlights perforation in palatal root. (B) Infected dentin removing by a Start X3. (C) Disinfection and hemostasis of the perforation. (D—I) Lateral root perforation management procedure. (J) Post-operative radiograph: root canals filled after 12 min. (K) Pulp floor at the end of procedure.

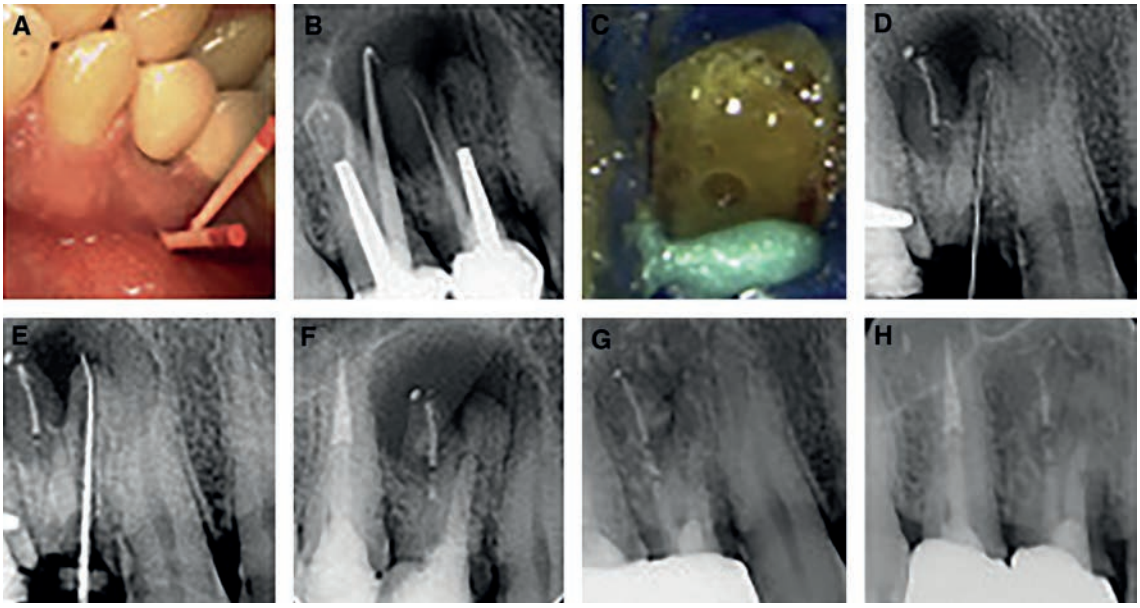

Figure 3 (A) Fistulas. (B) Fistulography. (C) Leaking of pus after crown and post removal. (D—E) Ledge management using manual files. (F) Filling of the perforation and root canal by biodentine. (G) 18 months radiographic follow-up. (H) 48 months radiographic follow-up.

Perforation repair management of 20 perforations was performed by supervised dental students under the direction of a qualified endodontist and 31 were performed exclusively by an expert endodontist (DM).

Preoperative and intraoperative data recording

1. Age;
2. Sex;
3. Tooth type (anteriors, premolars, molars);
4. Tooth location (maxilla, mandible)
5. Number of roots;
6. Tooth mobility (Miller);
7. Swelling;
8. Fistula;
9. Presence of post cast or fiber post;
10. Periapical radiolucency;
11. Furcation involvement;
12. Perforation localization (at the crestal level, apical to the crestal level);
13. Time between occurrence and repair (old: from 6m to 12m, very old perforation: $>$12 mm);
14. Pathological probing: assessed on gingival level by using a dichotomous score (negative for probing $<$4 mm, positive for probing $>$4 mm);
15. Step when the perforation occurred (during endodontic treatment; during prosthodontics treatment);

Table 1 Outcome distribution across preoperative variables.

Variable	Variable	Variable	Variable	Variable
Age				1
Until to 50	28 (93%)	2 (7%)	30 (59%)	
>50	20 (95%)	1 (5%)	21 (41%)	
Gender				1
Female	27 (93%)	2 (7%)	29 (57%)	
Male	21 (95%)	1 (5%)	22 (43%)	
Tooth type				0,59
Anteriors + premolars	22 (92%)	2 (8%)	24 (47%)	
Molars	26 (96%)	1 (4%)	27 (53%)	
Tooth location				0,28
Maxilla	32 (97%)	1 (3%)	33 (65%)	
Mandible	16 (89%)	2 (11%)	18 (35%)	
Number of roots				0,25
Single root	15 (88%)	2 (12%)	17 (33%)	
Multirooted	33 (97%)	1 (3%)	34 (67%)	
Tooth mobility (Miller)				1
Yes (class I, II, III)	13 (93%)	1 (7%)	14 (27%)	
No (class 0)	35 (96%)	2 (4%)	37 (73%)	
Sinus tract				1
Yes	25 (93%)	2 (7%)	27 (53%)	
No	23 (96%)	1 (7%)	24 (47%)	
Swelling				1
Yes	16 (94%)	1 (6%)	17 (33%)	
No	32 (94%)	2 (6%)	34 (67%)	
Presence of post (cast or fiber)				0,59
Yes	22 (92%)	2 (8%)	24 (47%)	
No	26 (96%)	1 (4%)	27 (53%)	
Periapical radiolucency				0,28
Yes	16 (89%)	2 (11%)	18 (35%)	
No	32 (97%)	1 (3%)	33 (65%)	
Furcation involvement				0,52
Yes	10 (91%)	1 (9%)	11 (22%)	
No	38 (95%)	2 (5%)	40 (78%)	
Localisation of perforation				1
Crestal	23 (96%)	1 (4%)	24 (47%)	
Apical to crestal bone	25 (93%)	2 (7%)	27 (53%)	
Time between occurrence and repair				1
From 6 m to 12 m	17 (94%)	1 (6%)	18 (35%)	
>12 mm	31 (94%)	2 (6%)	33 (65%)	
Pathological probing				0,28
Yes (>4 mm)	16 (89%)	2 (11%)	18 (35%)	
No (≤4 mm)	32 (97%)	1 (3%)	33 (65%)	
Occurrence of perforation				1
During endodontic treatment	19 (95%)	1 (5%)	20 (39%)	
During prosthodontic treatment	29 (93%)	2 (7%)	31 (61%)	
Size of perforation				1
≤1 mm	9 (100%)	0 (0%)	9 (18%)	
1−3 mm	29 (93%)	2 (7%)	31 (61%)	
>3 mm	10 (91%)	1 (9%)	11 (21%)	

Table 2 Outcome distribution across intra-operative and post-operative variables.

Variable	Healing N (%)	Non-healing N (%)	Total N (%)	*P* value
Bleeding leaking				1
Yes	20 (95%)	1 (5%)	21 (41%)	
No	28 (93%)	2 (7%)	30 (59%)	
Pus leaking				0.57
Yes	20 (91%)	2 (9%)	22 (43%)	
No	28 (96%)	1 (4%)	29 (57%)	
Root filling				1
Continuous wave	21 (95%)	1 (5%)	22 (43%)	
Carrier based filling	25 (93%)	2 (7%)	27 (53%)	
Bio dentine filling	2 (100%)	0 (0%)	2 (4%)	
Practitioner				1
Qualified endodontist	29 (93%)	2 (7%)	31 (61%)	
Supervised undergraduate student	19 (95%)	1 (5%)	20 (39%)	
Type of restoration after repair perforation				0.60
Crown + access cavity sealed with composite	25 (96%)	1 (4%)	26 (51%)	
Crown + access cavity sealed with composite ant fiber post	23 (92%)	2 (8%)	25 (49%)	

16. Perforation size (<1 mm, 1–3 mm, >3 mm);
17. Bleeding after the final irrigation (from perforation site);
18. Pus leaking (from perforation site);
19. Root filling technique;
20. Practitioner (expert, supervised undergraduate).

Outcome measures

Treatment outcome was assessed on the basis of clinical picture and radiographic analysis. A binary classification was used: ''healed'' or ''not healed''. Perforation was classified as healed when there were not any of the following findings: pain or discomfort, presence of a sinus tract infection or swelling, positive probing and radiolucency. Perforation was classified as not healed when at least one of these findings was observed. Follow-up examinations were performed every 6 months after treatment, for up to 24 months. After this period annual exams were performed.

Statistical analysis

The Fisher exact test was performed to investigate the effect of potential preoperative, intraoperative and postoperative outcome predictors as shown in Tables 1 and 2. Data was processed using SigmaPlot (Version 11.2; Systat Software, INC., San Jose, CA). Data was considered significant at $p \leq 0.05$.

Results

51 patients with an old infected root perforation resulting from endodontic or prosthodontic treatments were eligible and included in this study. Patients were treated from January 2011 to June 2016, either by supervised dental students (20 patients), or exclusively by a qualified endodontist (31 patients). Our patient panel shows broad variations in localization and type of tooth involved, as well as the location of the perforation. 24 perforations were in the crestal area and 27 were apical to the crestal area. Perforations in maxillary teeth were observed almost twice as often (65%) as in mandibular teeth (35%). Multi-root teeth were perforated twice as often (67%) as single root teeth (33%). 61% of perforations occurred during prosthodontic treatment (post-space preparation), the remaining 39% were induced during routine endodontic treatment.

The patient follow-up rate at 18 months was 100%. 46 patients were assessed having complete healing at 18 months following the initial treatment, and 48 completely healed at 24 months. We thus obtained a success rate of 94%.

As perforations characteristics can influence treatment prognosis, we evaluate the potential influence of preoperative (Table 1), intraoperative, and postoperative variables (Table 2).

The healing rate of perforations associated to sinus tract was lower than perforations without sinus tract (93% versus 96%, $p = 1$). The healing rate of large perforations (>3 mm) was lower than that of small ones (≤1 mm) (91% versus 100%, $p = 1$). The healing rate of perforations with leaking pus was lower than for perforations without leaking pus (91% versus 96%, $p = 0.57$). However, none of the differences observed were statistically significant.

Discussion

Iatrogenic root perforations are commonly occurring problems affecting 12–20% of primary endodontic treatments [2]. Perforation management represents a major challenge, even for experienced endodontists [1,2]. There is thus an urgent need to find a more suitable procedure to make treatment easier, more reproducible, and manageable even for general dentists and for student. In the present study, we investigated the healing rate of accidental old infected perforations after treatment with Biodentine® in a single visit using a simplified handling protocol. Moreover, unlike previous studies, we included in our study only old infected perforations. These sorts of lesions have the lowest reported

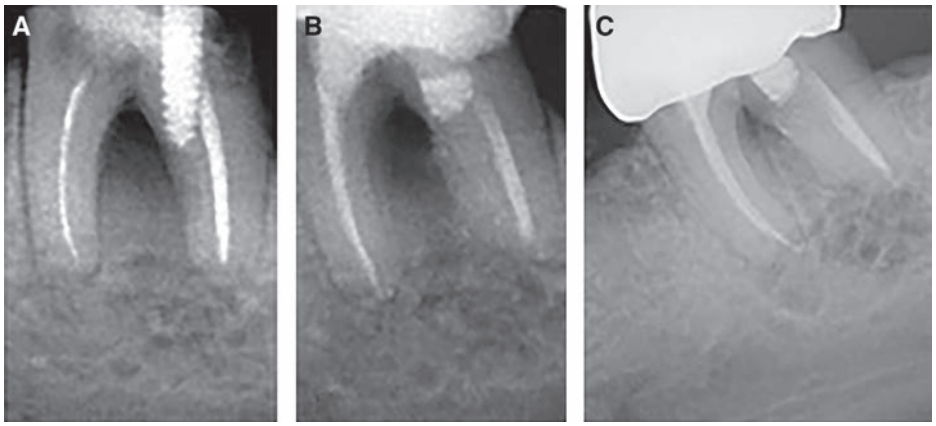

Figure 4 (A) Pre-operativee radiograph. (B) 48 months radiographic follow-up. (C) 48 months radiographic follow-up.

healing rate [1]. Our results show Biodentine is highly effective as repair material in a single visit, with a success rate of 94% (among a patient sample of 51 patients). This could show that the procedure is equal or superior to the standard two-step procedure, involving a first treatment with calcium hydroxide and a subsequent perforation sealing using MTA. Indeed Mente et al. using MTA in their study of 26 teeth, reported a success rate of 90% with old perforation and 86% for those at the crestal level, they thus obtained a total success rate of 86% [3]. Aside Gorni et al. record 96% of success rate for coronal perforation and 87% for intermediate ones, they thus obtained a total success rate of 92% [2].

Our high success rate might be explain because by two factors: first the effectiveness of Biodentine® and second, the simplification of the handling procedure. Concerning its effectiveness as perforation repair material, Biodentine® has the shortest setting time, good handling properties, and setting capability within an acidic environment [16,21—24]. A simplified procedure makes the outcomes more reproducible. The MTA-gun is not required to place the Biodentine® bioceramic material into the tooth, a simple spatula is sufficient. To pack Biodentine® into the bottom of the perforation, we use microbrushes instead of paper points, plastic carriers, and/or metal pluggers. Our failure rate was low, with only 3 out of 51 teeth scored as unhealed. Of these three failures, one tooth was extracted because of a fracture (detected in the 18th month follow-up visit). The others showed residual radiolucency at the perforation site, with no other clinical sign that could explain delayed healing (Fig. 4) [25].

In our study, size of the perforation, location and time, does not appear to influence treatment prognosis. It is in accordance with the study of Gorni et al. and Mente et al. [2—4]. It disagrees the historical description by Fuss and Trope's. However, to answer further this question our study should be extended to include more cases.

There was no difference, in terms of efficacy, if the management of perforations repair was directly performed by supervised dental students or by a qualified endodontist. That further confirms the robustness of the procedure. Unlike Gorni et al. [2]. Our study concluded that the perforation repair is reproducible, provided they use strict isolation and disinfection protocols and sufficient magnification.

Conclusion

The results of this study are encouraging nevertheless it is only a retrospective observational case series study with a low sample size.

The high success rate achieved supports that Biodentine® is an effective and well-tolerated agent in repairing old infected perforations in one step procedure.

In our study, time, size and location of the perforation does not appear to influence treatment prognosis. Moreover the success rate was comparable between supervised dental students and a qualified endodontist thanks to the superior handling properties simplifying Biodentine® application. This retrospective case series study proves that the management of old infected perforations using Biodentine® is a reproducible treatment even if performed by an inexperienced operator provided they use strict isolation and disinfection protocols and sufficient magnification.

Clinical relevance

The management of old infected iatrogenic root perforations using Biodentine might be considered an alternative treatment, since it usually requires a easier procedure and tends to be a more affordable option.

Conflict of interest

The authors deny any conflicts of interest.

Acknowledgements

The authors thank Bernard Senger for his precious help in the statistical analysis. The authors thank Damiano Pasqualini (DDS, Associate Professor) for fruitful discussion. In addition, the authors wish to thank Mrs Valentina Macaluso and Dr

Karen Niederreither for their assistance in preparation of this manuscript.

References

1. Fuss Z, Trope M. Root perforations: classification and treatment choices based on prognostic factors. *Endod Dent Traumatol* 1996;**12**:255—64.
2. Gorni FG, Andreano A, Ambrogi F, Brambilla E, Gagliani M. Patient and clinical characteristics associated with primary healing of iatrogenic perforations after root canal treatment: results of a long-term Italian study. *J Endod* 2016;**42**:211—5.
3. Mente J, Hage N, Pfefferle T, Koch MJ, Geletneky B, Dreyhaupt J, et al. Treatment outcome of mineral trioxide aggregate: repair of root perforations. *J Endod* 2010;**36**:208—13.
4. Mente J, Leo M, Panagidis D, Saure D, Pfefferle T. Treatment outcome of mineral trioxide aggregate: repair of root perforations-long-term results. *J Endod* 2014;**40**:790—6.
5. Camilleri J, Montesin FE, Papaioannou S, McDonald F, Pitt Ford TR. Biocompatibility of two commercial forms of mineral trioxide aggregate. *Int Endod J* 2004;**37**:699—704.
6. Haglund R, He J, Jarvis J, Safavi KE, Spångberg LS, Zhu Q. Effects of root-end filling materials on fibroblasts and macrophages in vitro. *Oral Surg Oral Med Oral Pathol Oral Radiol Endod* 2003;**95**:739—45.
7. Keiser K, Johnson CC, Tipton DA. Cytotoxicity of mineral trioxide aggregate using human periodontal ligament fibroblasts. *J Endod* 2000;**26**:288—91.
8. Krupp C, Bargholz C, Brüsehaber M, Hülsmann M. Treatment outcome after repair of root perforations with mineral trioxide aggregate: a retrospective evaluation of 90 teeth. *J Endod* 2013;**39**:1364—8.
9. Nosrat A, Nekoofar MH, Bolhari B, Dummer PMH. Unintentional extrusion of mineral trioxide aggregate: a report of three cases. *Int Endod J* 2012;**45**:1165—76.
10. Parirokh M, Torabinejad M. Mineral trioxide aggregate: a comprehensive literature review — part I: chemical, physical, and antibacterial properties. *J Endod* 2010;**36**:16—27.
11. Parirokh M, Torabinejad M. Mineral trioxide aggregate: a comprehensive literature review — part III: clinical applications, drawbacks, and mechanism of action. *J Endod* 2010;**36**:400—13.
12. Roy CO, Jeansonne BG, Gerrets TF. Effect of an acid environment on leakage of root-end filling materials. *J Endod* 2001;**27**:7—8.
13. Torabinejad M, Parirokh M. Mineral trioxide aggregate: a comprehensive literature review — part II: leakage and biocompatibility investigations. *J Endod* 2010;**36**:190—202.
14. Torabinejad M, Hong CU, Lee SJ, Monsef M, Pitt Ford TR. Investigation of mineral trioxide aggregate for root-end filling in dogs. *J Endod* 1995;**21**:603—8.
15. Watts JD, Holt DM, Beeson TJ, Kirkpatrick TC, Rutledge RE. Effects of pH and mixing agents on the temporal setting of tooth-colored and gray mineral trioxide aggregate. *J Endod* 2007;**33**:970—3.
16. Elnaghy AM. Influence of acidic environment on properties of biodentine and white mineral trioxide aggregate: a comparative study. *J Endod* 2014;**40**:953—7.
17. Lee Y-L, Lee B-S, Lin F-H, Yun Lin A, Lan W-H, Lin C-P. Effects of physiological environments on the hydration behavior of mineral trioxide aggregate. *Biomaterials* 2004;**25**:787—93.
18. Namazikhah MS, Nekoofar MH, Sheykhrezae MS, Salariyeh S, Hayes SJ, Bryant ST, et al. The effect of pH on surface hardness and microstructure of mineral trioxide aggregate. *Int Endod J* 2008;**41**:108—16.
19. Saghiri MA, Shokouhinejad N, Lotfi M, Aminsobhani M, Saghiri AM. Push-out bond strength of mineral trioxide aggregate in the presence of alkaline pH. *J Endod* 2010;**36**:1856—9.
20. Giovarruscio M, Uccioli U, Malentacca A, Koller G, Foschi F, Mannocci F. A technique for placement of apical MTA plugs using modified Thermafil carriers for the filling of canals with wide apices. *Int Endod J* 2013;**46**:88—97.
21. Aggarwal V, Singla M, Miglani S, Kohli S. Comparative evaluation of push-out bond strength of ProRoot MTA, Biodentine, and MTA Plus in furcation perforation repair. *J Conserv Dent* 2013;**16**:462—5.
22. Akcay H, Arslan H, Akcay M, Mese M, Sahin NN. Evaluation of the bond strength of root-end placed mineral trioxide aggregate and Biodentine in the absence/presence of blood contamination. *Eur J Dent* 2016;**10**:370—5.
23. Han L, Okiji T. Uptake of calcium and silicon released from calcium silicate-based endodontic materials into root canal dentine. *Int Endod J* 2011;**44**:1081—7.
24. Vallés M, Roig M, Duran-Sindreu F, Martínez S, Mercadé M. Color stability of teeth restored with biodentine: a 6-month in vitro study. *J Endod* 2015;**41**:1157—60.
25. Leprince JG, Zeitlin BD, Tolar M, Peters OA. Interactions between immune system and mesenchymal stem cells in dental pulp and periapical tissues. *Int Endod J* 2012;**45**:689—701.

Giornale Italiano di Endodonzia (2018) **32**, 25—30

Available online at www.sciencedirect.com

ScienceDirect

journal homepage: www.elsevier.com/locate/gie

CASE REPORT/CASO CLINICO

Surgical extrusion: A reliable technique for saving compromised teeth. A 5-years follow-up case report

Estrusione chirurgica: una tecnica predicibile per il recupero di denti compromessi. Un caso clinic con controllo a 5 anni

Jenner Argueta [a,b,*], **Ana Orellana** [b], **Gianluca Plotino** [c]

[a] *Endodontics Department, Universidad Mariano Gálvez de Guatemala, Guatemala*
[b] *Argueta — Orellana, Integral Microscopic Dentistry Center, Guatemala*
[c] *Grande, Plotino & Torsello — Studio di Odontoiatria, Rome, Italy*

Received 4 March 2018; accepted 19 March 2018
Available online 5 April 2018

KEYWORDS
Crown fracture;
Crown lengthening;
Surgical extrusion;
Surgical repositioning;
Biologic width.

Abstract
Aim: To present a long term follow up clinical case in which a compromised anterior tooth was saved by a surgical extrusion procedure.
Summary: Although different techniques have been suggested for clinical crown lengthening in the anterior zone, some of them have limitations in terms of aesthetics and procedural requirements. The current case report demonstrates how a simplified surgical extrusion procedure was successfully performed for saving a severely damaged anterior tooth; furthermore, it is possible to apply the technique described in this case using minimum and simple armamentarium like a scalpel, elevators, forceps and splinting flexible cord.
Key-learning points: Saving severely compromised anterior teeth is possible by applying surgical extrusion techniques when crown-root ratio allows it. Risk of root resorption or ankylosis is minimum.
© 2018 Società Italiana di Endodonzia. Production and hosting by Elsevier B.V. This is an open access article under the CC BY-NC-ND license (http://creativecommons.org/licenses/by-nc-nd/4.0/).

* Corresponding author at: Dubai Center, Office 501, 1st Av. and 13 Street, zone 10, Guatemala, C.A., Guatemala. Tel.: +502 4128 9169.
E-mail: jennerargueta@gmail.com (J. Argueta).
Peer review under responsibility of Società Italiana di Endodonzia.

Production and hosting by Elsevier

https://doi.org/10.1016/j.gien.2018.03.005
1121-4171/© 2018 Società Italiana di Endodonzia. Production and hosting by Elsevier B.V. This is an open access article under the CC BY-NC-ND license (http://creativecommons.org/licenses/by-nc-nd/4.0/).

PAROLE CHIAVE
Frattura coronale;
Allungamento di corona clinica;
Estruzione chirurgica;
Riposizionamento chirurgico;
Ampiezza biologica.

Riassunto
Obiettivo: Presentare un caso clinico con controllo a 5 anni in cui un dente anteriore compromesso è stato recuperato con una procedura di estrusione chirurgica.
Riassunto: Sebbene siano state suggerite diverse tecniche per l'allungamento della corona clinica nella zona anteriore, alcune di esse presentano limitazioni in termini di estetica e competenza nelle procedure. Il presente case report dimostra come una procedura di estrusione chirurgica semplificata sia stata eseguita con successo per salvare un dente anteriore gravemente danneggiato. Va sottolineato che la tecnica descritta in questo caso può essere portata a termine utilizzando un armamentario minimo e molto semplice come un bisturi, leve, pinze e uno splintaggio flessibile.
Key learning points: E' possibile salvare elementi dentari gravemente compromessi applicando tecniche di estrusione chirurgica quando il rapporto corona-radice lo consente. Il rischio di riassorbimento della radice o anchilosi è minimo.
© 2018 Società Italiana di Endodonzia. Production and hosting by Elsevier B.V. This is an open access article under the CC BY-NC-ND license (http://creativecommons.org/licenses/by-nc-nd/4.0/).

Introduction

Nowadays that dental implants are popular options for replacing natural teeth, it is not always necessary to perform heroic efforts to save severely damaged teeth[1]; however, retain patient's natural dental organs should be one of the main goals of dentists around the world.

Although different techniques have been suggested for clinical crown lengthening procedures to provide good conditions to restore severely damaged teeth, all of them have some limitations in aesthetic terms. In aesthetic zone, crown lengthening requires a more complex diagnostic and planning process, because, when choosing a surgical crown lengthening technique, special care should be taken or it could cause asymmetry of the gingival line.[2,3]

A high percentage of traumatic injuries occur most frequently in the anterior zone, mostly in central and lateral maxillary incisors.[4,5] When these injuries happen, sometimes is not possible to restore the affected tooth without additional dental procedures for obtaining adequate supra-gingival structure.

Different terminologies have been used for surgical extrusion: it is also known as intra-alveolar transplantation, intentional replantation and forceps eruption.[6–8] A surgical tooth extrusion technique was described in 1978,[9] while the first case report was published in 2002.[10] Despite of its first description long time ago, this technique still remains rarely performed among practitioners.

Surgical extrusion is defined as the procedure in which the remaining tooth structure is repositioned at a more coronal/supra-gingival position in the same socket in which the tooth was located originally.[8,11] The main principle is to place the affected tooth in a more coronal position for providing acceptable conditions to achieve the reestablishment of healthy supra-coronal tooth structure; this last point is important to be able to create a good restoration, that will maintain the biologic width healthy.[1,3] Thus, this technique can be used successfully to treat severely damaged teeth, especially in the anterior esthetic zone.

A resume of the main steps involved in the technique described are: syndesmotomy, luxation of the tooth using periotomes and/or elevators, extrusion of the root with forceps, immobilization of the root for two to three weeks in the new position using a semi-flexible splinting cord or interdental sutures, post placement and final restoration.[1,3,6,7,12] The technique can be successfully applied with minimal chair side procedures, no needed of special surgical skills, good esthetics, low incidence of failure and easy acceptance from the patient.

Case series and reports are categorized as low evidence literature[13,14] because causal relationships between intervention and outcome cannot be definitely established without a control group. Nevertheless, clinical reports can influence clinical decision making during dental clinical practice,[13] as well as open interest in new techniques, clinical approaches and investigation lines. Therefore, the aim of this report is to show a long-term follow up of a clinical case in which a compromised anterior tooth was saved by a surgical extrusion procedure.

Report

In the present case report, a simplified surgical extrusion procedure is described where an upper lateral incisor with severely compromised structure was treated successfully.

A 37 years old female patient suffered a traumatism at the level of anterior—superior teeth. The patient arrived at the office with a fractured upper left central incisor. The tooth had a previous root canal treatment, a pre-fabricated metal post and a composite build-up (Fig. 1). After removing the post and the build-up material, it was evident the lack of supra-gingival sound tooth structure to perform a predictable and reliable long time lasting restoration (Fig. 2): ferrule effect was not possible to be obtained in such conditions.[15] The next steps were to evaluate the radicular length and the width of remaining radicular and coronal walls and to consider the possible different treatment options to save the tooth. After a complete evaluation, it was decided to perform a surgical tooth extrusion to obtain a proper supra-gingival sound structure, thus offering to the patient a reliable long-term result.[8]

Clinical procedures were performed as follows: after disinfection of the affected area using a wet gauze with 2% chlorhexidine, syndesmotomy was made using a 15c scalpel and luxation of the tooth was achieved using a fine elevator

Figure 1 Preoperative radiograph; the root length is enough for extruding the tooth approximately 3—4 mm to gain supra-gingival structure without compromising the crown-root ratio.

Figure 2 Clinical scenario after removing the core buid-up material and the prefabricated metal post. Lack of supra-gingival tooth structure is evident.

applying luxating forces just at the first 3—4 mm of the radicular structure to prevent damaging to the periodontal ligament that will remain in an infra-bony position. After that the tooth got lost from the socket, it was extruded approximately 4 mm (Figs. 3 and 4): extrusion was made using forceps and the tooth was grabbed only at the zone of the radicular portion that was supposed to stay in a supra-bony position after the procedure.

When the tooth was in the desired position, a slight pressure was applied in bucco-lingual direction with a gauze

Figure 3 Clinical picture of the tooth during the extrusion procedure.

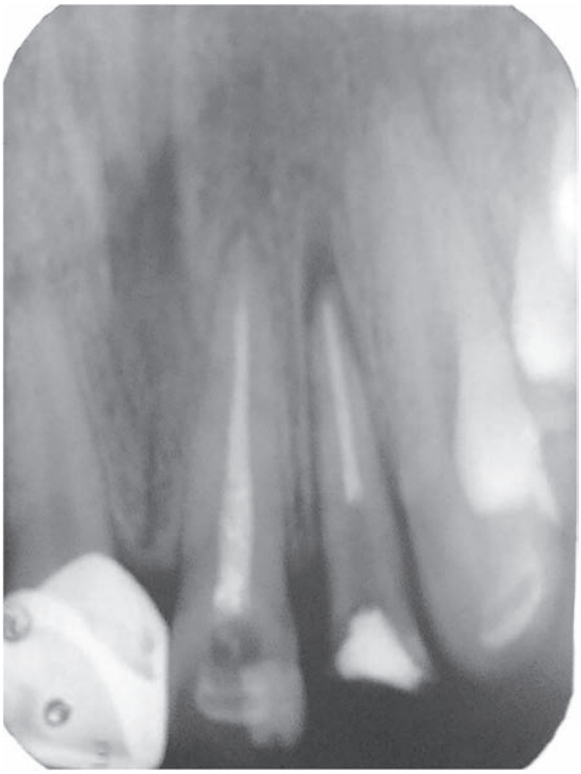

Figure 4 Post-operative radiograph; it is possible to evaluate at apical level the quantity of mm extruded as a radiolucent area.

embedded with chlorhexidine to obtain hemostasis before splinting. Even though, interdental sutures for stabilizing the tooth are the most reported type of splinting material,[16] in this case it was decided to use 0.8 mm diameter monofilament nylon fishing cord; it has the advantages that is cheap and easy to be obtained, offers a semi-rigid splinting and is easy to keep clean by the patient. The splint was placed using an auto-adhesive flowable composite, easy to be applied when a dry environment is difficult to be maintained for long time (Fig. 5). The splinting time was 15 days, as this splinting lapse is advisable for providing tooth stability and decreasing risk of ankylosis.[16,17] It has been reported that mobility can decreases after a period of 3—4 weeks after the

Figure 5 Splinting the involved element to the adjacent teeth; a monofilament nylon fishing cord was used.

splint is removed.[8] Even though bone grafting have been reported for improving tissue repair at apical level, benefits have not been clearly demonstrated[9,18]; in this case it was not used any bone grafting material because the main purpose was to keep the technique as simple as possible. Patient got instructions of cleaning the area in a regular basis, using a soft brush for not affecting gingival tissue repair.

Orthograde endodontic retreatment was made 15 days after the extrusion with the splinting cord in place. After rubber dam placement, the canal was desobturated using a K3XF 35.06 file (Kerr Endodontics, Orange, CA, US) at 1200 rpm without using any kind of solvent, disinfection was made using 20 mL of 5.25% sodium hypochlorite and 3 mL of 17% EDTA as final irrigating solution. Continuous wave of compaction technique of gutta-percha and resin based sealer was used for filling the root canal. During the same appointment, a fiber post was placed to provide proper height to the core preparation; the fiber post was cemented using a dual-cure composite cement inside the canal and SonicFill composite (Kerr Endodontics, Orange, CA, US) was used as core build-up material to reconstruct the missed coronal tooth structure (Figs. 6 and 7).

Crown preparation was made 30 days after the surgical extrusion procedure, confirming that a proper ferrule height and thickness was effectively present. The tooth was then temporized and a final full metal-ceramic crown restoration was placed three months after the initial procedure to provide enough time for the periodontal tissues to heal and thus avoiding post-restorative gingival migration.[19,20] Cuspal covering restorations (overlay or complete crowns) are the most indicated final restorative options in the cases in which a severe loss of tooth structure was present.[16] The radiographic control taken the day of the final restoration placement showed signs of periapical healing (Fig. 8). It has been reported that it is possible to see a normal periodontal ligament contour three months after the procedure,[8,19] while periapical healing and resolution of radiolucency is commonly observed 6 months after with minor loss of marginal bone,[8] commonly related to bone damage during the extrusion procedure. After five years follow up, a complete periodontal tissue repair was observed (Fig. 9). Slight radiographic signs of superficial root resorption are present at distal apical level. The tooth remained asymptomatic, without mobility and in completely aesthetic and biological function.

Figure 6 Post-operative radiograph; root canal retreatment and fiber post placement were done in the same appointment, 15 days after the surgical extrusion procedure.

Figure 7 Clinical picture of the tooth after post placement, core build-up reconstruction and splinting removal.

Discussion

The basic principle for biologic width care says that there should be at least 2—3 mm of tooth between the bone and the margin of the final restoration.[21] If biologic width is invaded during restorative procedures, they may lead to periodontal breakdown.[22] When crown lengthening is planned to increase the length of affected available teeth for restorative preparations, some anatomic and biologic considerations need to be done. Different techniques have been proposed for clinical crown lengthening procedures; particularly in anterior esthetic regions the preservation of gingival margin and interdental papilla is required in order to obtain satisfactory final esthetic outcome.[19,21,23]

Figure 8 Radiograph of the final full-crown in place, three months after the initial procedure; it is possible to note the periapical healing without changes on radicular surface.

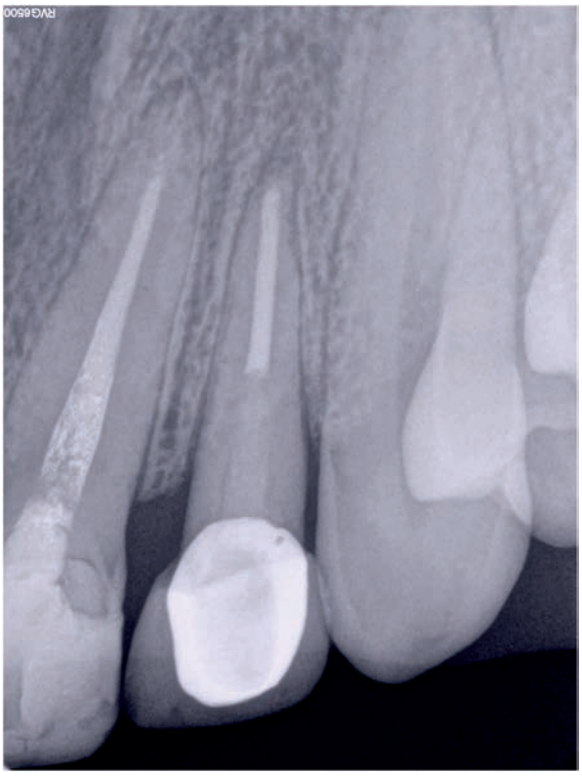

Figure 9 Five years follow-up radiograph; it is possible to observe the complete periapical bone healing, a continuous periodontal ligament space and a superficial root resorption at the apical distal level.

Surgical extrusion represents the separation of bone-root periodontal attachment using surgical instruments such as fine elevators, periotomes, forceps, scalpel, for placing the tooth in a more coronal position with the aim to obtain supragingival sound structure to be able to perform a proper long-time lasting final restoration, without risk of damaging periodontal tissues and invading biologic width.[3,16,18] This procedure is indicated in cases of crown-root fracture (involving enamel, dentine and cementum with or without the pulp compromised),[24] root fracture (involving cementum, dentine and pulp),[25] carious lesions extending near to the alveolar bone crest that appear to be un-restorable,[26] cervical root resorption and teeth with lack of supra-gingival tooth structure to provide an adequate ferrule effect.[16,27] In cases where sub-gingival labial fracture occurs, rotation of the tooth by 180 degrees may also be indicated to reduce the quantity of tooth needed to be extruded,[16] because when tooth is rotated it requires less extrusion to provide access to the margins of the fracture on the facial aspect.[8] In some cases it is important to limit the extrusion quantity to maintain an adequate coronal—radicular ratio.

One of the surgical extrusion techniques published involves flap elevation with careful exposure of the apex, but this technique is not recommended for the anterior zone and nowadays more conservative approaches are advisable.[8] Root extraction studies have reported that the use of vertical axial traction forces produces significantly less cementoblast loss on root surfaces than extracting teeth with forceps.[28] One of the disadvantages of the technique suggested in the present report for luxating the tooth is that, if the clinician is not gentle while applying pressure, a possibility exists of exerting too high compressive forces to the periodontal ligament at apical and coronal radicular level; it may cause a damage to the cementoblasts and periodontal ligament cells at some points around the radicular surface, increasing as a consequence the risk of superficial root resorption.[28,29] However, superficial root resorption is not progressive in nature and primarily associated whit the surgical technique[8,30] and functional repaired surface resorption have been observed and reported in some root segments. Higher rates of root resorption have been seen in cases in which the root canal treatment was made before the extrusion procedure.[8]

Even though bone grafting have been reported for improving tissue repair at apical level[9,18] benefits have not been clearly demonstrated. On the other hand, apical rupture of periodontal tissues leads to formation of a coagulum apical to the root apex, which subsequently leads the formation of a fibrous scaffold with ultimate maturation into cancellous bone[31,32]; for this reason, bone grafting was not considered as a treatment option in the present case.

Some advantages of the surgical extrusion technique are: less operative and overall treatment time compared to orthodontic extrusion, a relatively easy procedure with less cost compared with conventional crown lengthening techniques, a short chair time, patient recovery is not complicated and long term cooperation from the patient is not required.[1,8,12,23] Possible adverse events associated to the technique presented in the present case report may be: root fracture during the extrusion procedure, superficial root resorption, marginal bone loss, persistent tooth mobility,

tooth loss due to compromised periodontal attachment or inadequate crown-root ratio and tooth ankylosis (not common with this technique because all the procedures are performed under a controlled environment).[1,16] Further limitations related to this procedure may be: patient acceptance, difficulty for the temporization of the tooth, poor patient oral hygiene (mainly during the first post-operative week) and bleeding control when an adhesive splint is placed.[16]

Conclusion

The 5-years follow-up of the case of surgical extrusion presented in this report showed a complete healing of the periapical tissues, with only a radiographic evidence of a small superficial root resorption in the distal area of apical third. Clinically, the tooth remains asymptomatic, without mobility and in completely aesthetic and biological function, demonstrating a satisfactory outcome of the clinical technique presented.

Clinical relevance

The technique showed in the present case report demonstrated to be a possible valid alternative treatment for the maintenance of compromised teeth.

Conflict of interest

The authors have no conflict of interest to declare.

References

1. Lee JH, Yoon SM. Surgical extrusion of multiple teeth with crown-root fractures: a case report with 18-months follow up. *Dent Traumatol* 2015;**31**:150—5. PubMed PMID: 25130861.
2. Singh A, Verma R. Crown lengthening vs forced eruption. *Orthod J Nepal* 2011;**1**.
3. Sterr N, Becker A. Forced eruption: biological and clinical considerations. *J Oral Rehabil* 1980;**7**:395—402. PubMed PMID: 6936521. Epub 1980/09/01.eng.
4. Andersson L. Epidemiology of traumatic dental injuries. *J Endod* 2013;**39**(Suppl):S2—5. PubMed PMID: 23439040.
5. Petersson EE, Andersson L, Sorensen S. Traumatic oral vs non-oral injuries. *Swed Dent J* 1997;**21**:55—68. PubMed PMID: 9178450. Epub 1997/01/01.eng.
6. Moura LF, Lima MD, Moura MS, Carvalho PV, Cravinhos JC, Carvalho CM. Treatment of a crown-root fracture with intentional replantation — case report with 16-year follow-up. *Int Endod J* 2012;**45**:955—60. PubMed PMID: 22671028.
7. Khayat A, Fatehi S. Clinical evaluation of forceps eruption: reestablishing biologic width and restoring no restorable teeth. *Indian Endod J* 2006;**1**.
8. Das B, Muthu MS. Surgical extrusion as a treatment option for crown-root fracture in permanent anterior teeth: a systematic review. *Dent Traumatol* 2013;**29**:423—31. PubMed PMID: 23802693.
9. Tegsjo U, Valerius-Olsson H, Olgart K. Intra-alveolar trans-plantation of teeth with cervical root fractures. *Swed Dent J* 1978;**2**:73—82.
10. Roeters J, Bressers J. The combination of a surgical and adhesive restorative approach to treat a deep crown-root fracture: a case report. *Quintessence Int* 2002;**333**.
11. Yiğit Özer S, Uysal İ, Bahşi E. Surgical extrusion of a complete crown fractured tooth: a case report. *Int Dent Res* 2011;**1**:70—4.
12. Kim DS, Shin DR, Choi GW, Park SH, Lee JW, Kim SY. Management of complicated crown-root fractures using intentional replantation: two case reports. *Dent Traumatol* 2013;**29**:334—7. PubMed PMID: 22066915.
13. Bauer J, Spackman S, Chiappelli F, Prolo P. Evidence-based decision making in dental practice. *J Evid Based Dent Pract* 2005;**5**:125—30. PubMed PMID: 17138350.
14. Lilford RJ, Pauker SG, Braunholtz DA, Chard J. Decision analysis and the implementation of research findings. *BMJ (Clinical Research ed)* 1998;**317**:405—9. PubMed PMID: 9694762. Pubmed Central PMCID: PMC1113676. Epub 1998/08/08.eng.
15. Kar S, Tripathi A, Trivedi C. Effect of different ferrule length on fracture resistance of endodontically treated teeth: an in vitro study. *J Clin Diagn Res* 2017;**11**:ZC49—52. PubMed PMID: 28571261. Pubmed Central PMCID: PMC5449917. Epub 2017/06/03.
16. Elkhadem A, Mickan S, Richards D. Adverse events of surgical extrusion in treatment for crown-root and cervical root fractures: a systematic review of case series/reports. *Dent Traumatol* 2014;**30**:1—14. PubMed PMID: 23796195.
17. Veras SRA, Bem JSP, de Almeida ECB, Lins C. Dental splints: types and time of immobilization post tooth avulsion. *J Istanb Univ Fac Dent* 2017;**51**(Suppl 1):S69—75. PubMed PMID: 29354311. Pubmed Central PMCID: PMC5750830. Epub 2018/01/23.
18. Kahnberg K, Warfvinge J, Birgersson B. Intraalveolar transplantation. (I). The use of autologous bone transplants in the periapical region. *Int J Oral Surg* 1988;**11**.
19. Hempton T, Dominici J. Contemporary crown-lengthening therapy; a review. *J Am Dent Assoc* 2010;**141**.
20. Lai JY, Silvestri L, Girard B. Anterior esthetic crown-lengthening surgery: a case report. *J Can Dent Assoc* 2001;**67**:600—3. PubMed PMID: 11737985. Epub 2001/12/12.eng.
21. Bajaj P, Chordiya R, Rudagi K, Patil N. Multidisciplinary approach to the management of complicated crown-root fracture: a case report. *J Int Oral Health* 2015;**7**:88—91. PubMed PMID: 25954080. Pubmed Central PMCID: PMC4409806. Epub 2015/05/09.eng.
22. Mohan KP, Ravindra RN, Roopa D, Kishore KK. Atraumatic surgical extrusion using periotome in esthetic zone: a case series. *J Conserv Dent* 2013;**16**:175—9. PubMed PMID: 23716974. Pubmed Central PMCID: PMC3659867. Epub 2013/05/30.eng.
23. Kim SH, Tramontina V, Passanezi E. A new approach using the surgical extrusion procedure as an alternative for the reestablishment of biologic width. *Int J Periodontics Restor Dent* 2004;**24**.
24. Spinas E, Altana M. A new classification for crown fractures of teeth. *J Clin Pediatr Dent* 2002;**26**.
25. Malhotra N, Kundabala M, Acharaya S. A review of root fractures: diagnosis, treatment and prognosis. *Dent Update* 2011;**38**:615.
26. Kelly RD, Addison O, Tomson PL, Krastl G, Dietrich T. Atraumatic surgical extrusion to improve tooth restorability: a clinical report. *J Prosthet Dent* 2016;**115**:649—53. PubMed PMID: 26803176.
27. Juloski J, Radovic I, Goracci C, Vulicevic ZR, Ferrari M. Ferrule effect: a literature review. *J Endod* 2012;**38**:11—9. PubMed PMID: 22152612.
28. Oikarinen K, Stoltze K, Andreasen J. Influence of conventional forceps extraction and extraction with an extrusion instrument on cementoblast loss and external root resorption of replanted monkey incisors. *J Periodontal Res* 1996.
29. Trope M. Root resorption of dental and traumatic origin: classification based on etiology. *Pract Periodontics Aesthet Dent* 1998;**10**:515—22. PubMed PMID: 9655059. Epub 1998/07/09.eng.
30. Oliveira B, Santiiago D, Lins D, Siebra J, Bastos R. Root resorption after dental traumas: classification and clinical, radiographic and histologic aspects. *RSBO* 2011.
31. Andreasen J, Andreasen F, Andersson LDiff id113/. Textbook and color atlas of traumatic injuries to the teeth. Copenhagen: Blackwell Munksgaard; 2007.
32. Farina R, Trombelli L. Wound healing of extraction sockets. *Endod Top* 2013;**25**.

Giornale Italiano di Endodonzia (2018) **32**, 31—35

Available online at www.sciencedirect.com

ScienceDirect

journal homepage: www.elsevier.com/locate/gie

CASE REPORT/CASO CLINICO

Retreatment of a mandibular second premolar with two canals in two roots

Ritrattamento di un secondo premolare mandibolare con due canali in due radici

Chiara Fossati *

Private Practice in Genova, Italy

Received 26 February 2018; accepted 21 March 2018
Available online 11 April 2018

KEYWORDS
Second mandibular premolar;
Uncommon anatomies;
Missed anatomy;
Two roots;
Complex canal system.

Abstract
Aim: To present a case of retreatment in mandibular second premolar with two canals in two roots.
Summary: Locating, cleaning and shaping the entire root canal system may represent a difficult challenge particularly in mandibular premolars, because of their complex canal systems.

For this reason mandibular premolars are often considered the most difficult of all teeth on which to perform successful endodontic treatment. Vertucci stated that the second premolar has one root canal at the apex in 97.5% of the teeth studied and two canals in only 2.5%.[1] The following case report describes the diagnosis and retreatment of a second premolar with two canal in two roots.

Key learning points:(1)The major cause of failure in root canal therapy is the inability to localize and treat all of the canals of the root canal system.(2)Mandibular premolars have complex canal systems.(3)Mandibular premolars have a high risk of missed anatomy.(4)Preoperative radiograph interpretation is essential to evaluate and detect uncommon anatomies.(5)The operating microscope and CBCT interpretation are fundamental in confirming and preventing mistakes about the configuration of mandibular premolars.
© 2018 Società Italiana di Endodonzia. Production and hosting by Elsevier B.V. This is an open access article under the CC BY-NC-ND license (http://creativecommons.org/licenses/by-nc-nd/4.0/).

* Correspondence to: Strada Borgo Tinasso 81, 18038 Sanremo, Italy. Tel.: +39 3334608974.
E-mail: dr.chiara.fossati@gmail.com.
Peer review under responsibility of Società Italiana di Endodonzia.

Production and hosting by Elsevier

https://doi.org/10.1016/j.gien.2018.03.002
1121-4171/© 2018 Società Italiana di Endodonzia. Production and hosting by Elsevier B.V. This is an open access article under the CC BY-NC-ND license (http://creativecommons.org/licenses/by-nc-nd/4.0/).

PAROLE CHIAVE
Secondo premolare mandibolare;
Varianti anatomiche;
Anatomie dimenticate;
Due radici;
sistema canalare complesso.

Riassunto
Obiettivi: Presentare un caso clinico di ritrattamento canalare di un secondo premolare mandibolare con due canali e due radici.
Riassunto: Individuare, sagomare, detergere l'intero sistema radicolare presenta una sfida difficile in ambito endodontico e in particolar modo nei premolari mandibolari per il loro complesso sistema canalare. I premolari mandibolari sono spesso considerati i denti più difficili in cui effettuare una terapia endodontica.

Vertucci riscontrò che i secondi premolari mandibolari hanno una radice e un canale nel 97.5% e due canali in solo il 2.5%.[1]

Il case report seguente descrive la diagnosi e il ritrattamento di un secondo premolare con due canali in due radici.

Punti chiave di apprendimento:1.La maggior causa di fallimento endodontico è l'impossibilità di individuare, trattare tutti i canali del sistema radicolare.2.I premolari mandibolari hanno un complesso sistema endodontico.3.I premolari mandibolari hanno un alto rischio di canali non trattati.4.Le radiografie preoperatorie sono essenziali per valutare e individuare variabili anatomiche.5.Il microscopio operatorio e la CBCT possono essere essenziali per confermare e prevenire errori riguardo alla configurazione radicolare dei premolari mandibolari.
© 2018 Società Italiana di Endodonzia. Production and hosting by Elsevier B.V. This is an open access article under the CC BY-NC-ND license (http://creativecommons.org/licenses/by-nc-nd/4.0/).

Introduction

The main objective of the endodontic therapy is to prevent and, when required, to treat the pulpal and periapical pathology with a proper cleaning, shaping and tridimensional filling.

However, locating, cleaning and shaping the entire root canal system may present a difficult challenge in nonsurgical endodontic treatment because the operator could find aberrant canal configurations, accessory canals, bifurcations, isthmuses, and anastomoses.

The frequency and risk of missed anatomy are strictly linked with the complexity of the root canal system.

Mandibular premolars, because of their complex canal systems, are often considered the most difficult of all teeth on which to perform successful endodontic treatment.[2]

The morphology of the second premolar is simpler than the anatomy of the first premolar. Vertucci found that the second premolar had one root canal at the apex in 97.5% of the teeth studied and two canals in only 2.5%.[1]

Report

A 40-year-old-male, with a non-contributory medical history was referred to my office for endodontic and restorative treatment of 4.5 and 4.6.

Clinical examination of 4.5 and 4.6 showed an inadequate restoration. The percussion was positive on 4.5 and negative on 4.6.

The X-ray exam obtained by using the paralleling technique showed that the previous endodontic treatments were not correct (Fig. 1).

No periapical lesion was present on tooth 4.5 but was present on the distal root of 4.6.

By a careful examination of the right mandibular second premolar, an anatomic variability was found: two canals in two roots.

Both the elements needed a prosthetic restoration and the endodontic retreatment had to be carried out.

After isolating the operative field with the dental dam, the decayed tissue and the previous restoration of 4.5 were removed and an ovoid cavity access was performed with diamond burs and finished with dedicate ultrasonic tips.

The separated lingual and buccal orifices were found by using magnification and co-axial illumination.

The two canals were disinfected with sodium hypochlorite solution (5.25%) and EDTA (17%) and shaped with k-files 0.8 and 10, ProGlider and Protaper Next instruments X1 and X2 (Dentsply Maillefer). The lengths of these canals were measured electronically by using the Morita DentaPort ZX Apex Locator. Periapical X-ray, taken to confirm the working lengths, confirmed the presence of two roots (Fig. 2).

The root canal obturation was performed with two Thermafil 25 and zinc-oxide-eugenol sealer (Kerr Pulp Canal Sealer) (Fig. 3).

The retreatment of 4.6 was performed during a separate clinical session. The pre-existing sealer was removed and the canals were negotiated to full length. The case has been completed using the previous protocol of shaping and cleaning (Figs. 4 and 5).

The residual dental structures were not sufficient for a direct restoration and the teeth, after the build up (Fig. 6), were restored with an indirect cuspal coverage restoration, cemented with an adhesive luting agent.[3]

Discussion and conclusions

Mandibular premolars, because of their complex canal systems, are often considered the most difficult of all teeth on which to perform successful endodontic treatments. For this reason it is mandatory to follow a series of basic principles in case of root canal treatment. A preoperative radiograph, a second angulated preoperative radiograph, an additional

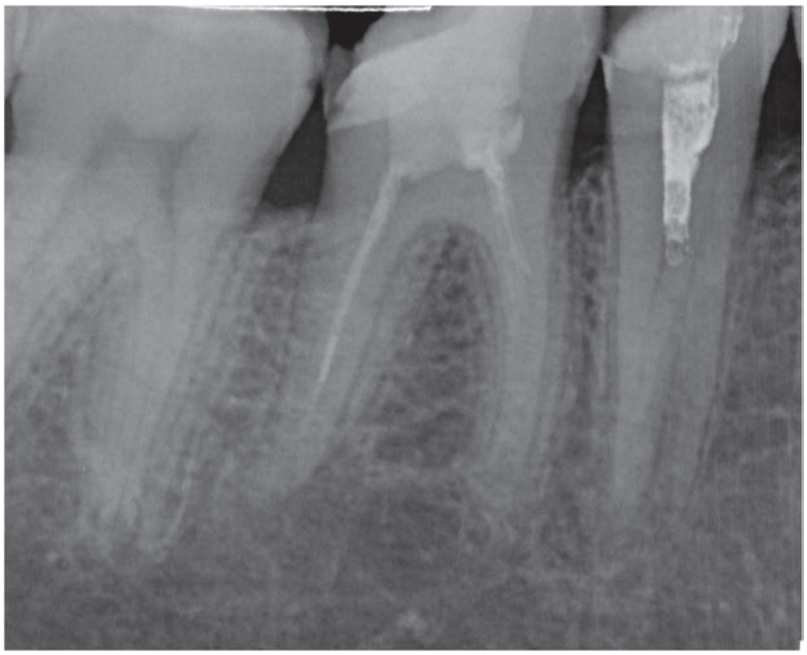

Figure 1 Pre-operative X-ray of 4.5 and 4.6.

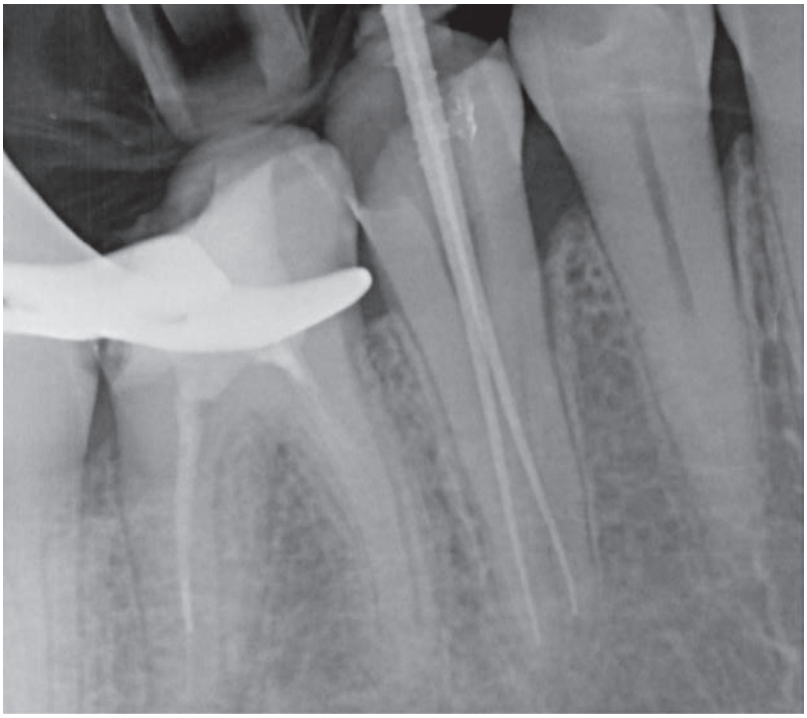

Figure 2 Intra-operative X-ray for working lengths of 4.5.

intra-operative radiograph and their correct interpretation are essential to evaluate and detect uncommon anatomies.[4]

Prior to commencing the root canal treatment, the dental practitioner is not able to precisely determine the number of root canals. Pulp chamber floor and wall anatomy provide a guide to understanding what morphology is actually present.[4]

The operating microscope should be used to facilitate the observation of the bi-trifurcation and the orifice. In some cases CBCT can be useful in understanding and preventing the configuration of mandibular premolars that is not as possibly detailed on a conventional X-ray, but easily spotted on the adequate CBCT slice.[5]

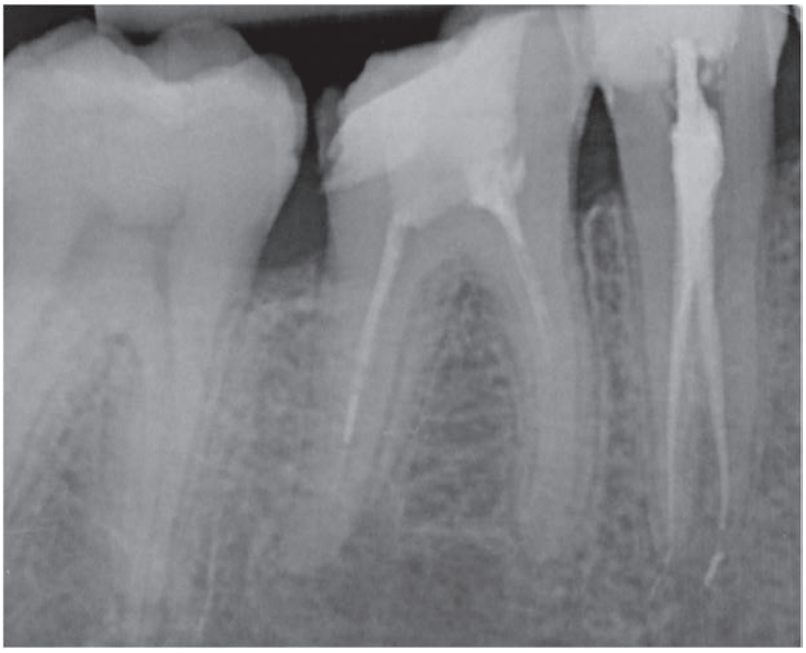

Figure 3 Postoperative X-ray of 4.5.

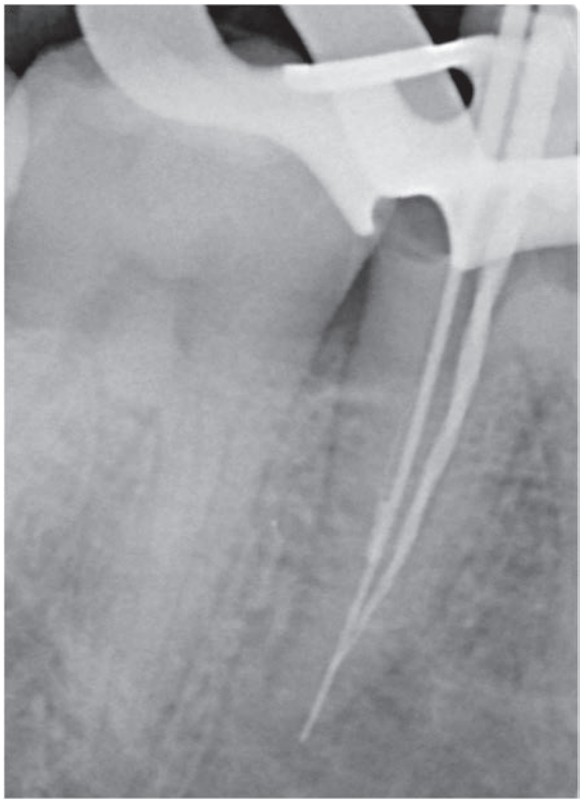

Figure 4 Intra-operative X-ray for working lengths confirmation of DV and DL canals of 4.6.

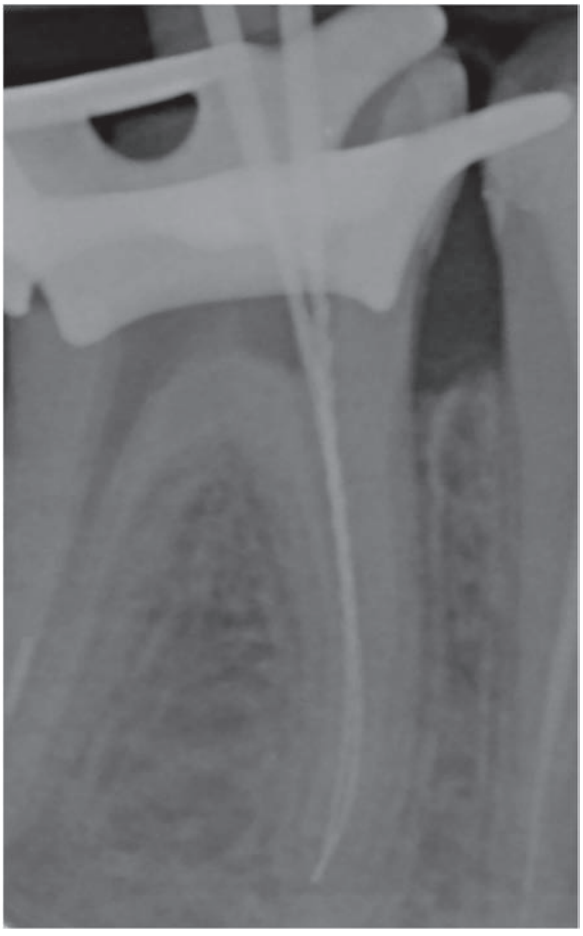

Figure 5 Intra-operative X-ray for working lengths confirmation of ML and MV canals of 4.6.

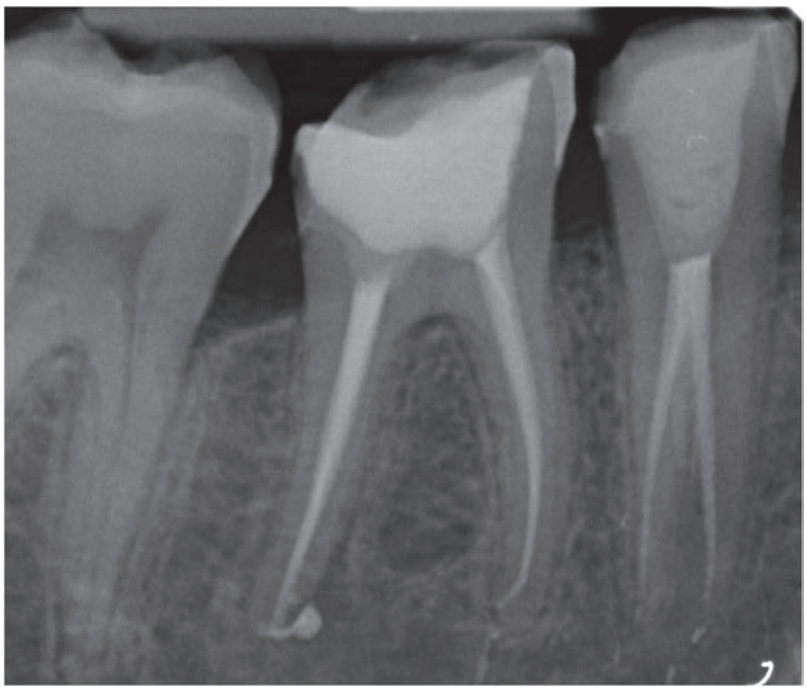

Figure 6 Postoperative X-ray of 4.5 and 4.6 after build up restoration.

Clinical relevance

This case report shows how a correct interpretation of a preoperative X-ray and the knowledge of the root anatomy are fundamental to perform a correct endodontic treatment.

Conflict of interest

The author declares no conflict of interest.

Acknowledgements

A special thanks to the staff of the Studio Associato Ferraris Piccardo for their kindness and to Dr. Andrea Polesel for his constant support.

References

1. Cantatore G, Berutti E, Castellucci A. Missed anatomy: frequency and clinical impact. *Endod Top* 2009;**15**:3—31.
2. Società Italiana di Endodonzia "Manuale di Endodonzia"; 2013.
3. Liebenberg W. Posterior composite resin restorations: operative innovations. *Pract Period Aesthet Dent* 1996;**8**:769—78.
4. Frank J, Vertucci. Root canal morphology and its relationship to endodontic procedures. *Endod Top* 2005;**10**:3—29.
5. Bòveda CDiff id33/, Kishen A. Contracted endodontic cavities: the foundation for less invasive alternatives in the management of apical periodontitis. *Endod Top* 2015;**33**:169—86.

Giornale Italiano di Endodonzia (2018) **32**, 36—41

Available online at www.sciencedirect.com

ScienceDirect

journal homepage: www.elsevier.com/locate/gie

ORIGINAL ARTICLE/ARTICOLO ORIGINALE

35° CONGRESSO NAZIONALE BOLOGNA 2017 — VINCITORE PREMIO RICCARDO GARBEROGLIO

Human Periapical Cysts-Mesenchymal Stem Cells Cultured with Allogenic Human Serum are a "clinical-grade" construct alternative to bovine fetal serum and indicated in the regeneration of endo-periodontal tissues

Le human periapical cysts-mesenchymal stem cells coltivate con siero umano allogenico costituiscono un costrutto ''clinical-grade'' alternativo al siero fetale bovino ed indicato nella rigenerazione dei tessuti endo-parodontali

Marco Tatullo [a,*], Massimo Marrelli [a], Francesca Palmieri [a], Carlo Rengo [b], Francesco Paduano [a], Gianrico Spagnuolo [b]

[a] *Tecnologica Research Institute, Stem Cell Unit, Crotone, Italy*
[b] *Department of Neurosciences, Reproductive and Odontostomatological Sciences, University of Naples "Federico II", Naples, Italy*

Received 17 November 2017; accepted 20 March 2018
Available online 6 April 2018

KEYWORDS
Regenerative medicine;
Stem cells;
Osteogenesis;
Human periapical cyst-MSCs;
Translational research.

Abstract
Aim: Our research investigated the use of human serum (HS) as a safe and clinical-grade culture medium, using a new cell-model: hPCy-MSCs. This article is aimed to concretely applicate the concept of "waste-based regenerative dentistry" to translate it in future endo-periodontal applications.
Methodology: HPCy-MSCs were cultured in 2 different mediums, both containing α-MEM: the 1st with 10% FBS (Control group), and the 2nd with 10% human serum (Test group).

* Corresponding author at: Tecnologica Research Institute, Street Enrico Fermi, 88900 Crotone, Italy. Tel./fax: +39 0962930414.
E-mail: marco.tatullo@tecnologicasrl.com (M. Tatullo).

Peer review under responsibility of Società Italiana di Endodonzia.

Production and hosting by Elsevier

https://doi.org/10.1016/j.gien.2018.03.003

1121-4171/© 2018 Società Italiana di Endodonzia. Production and hosting by Elsevier B.V. This is an open access article under the CC BY-NC-ND license (http://creativecommons.org/licenses/by-nc-nd/4.0/).

Cell proliferation and stemness assays, gene expression, immunophenotypic analysis and osteogenic differentiation were performed to verify our hypothesis. cDNA samples were amplified with qPCR.

Experiments were performed in triplicate and analysed with statistical software.

Results: The hPCy-MSCs cultivated in a medium with HS were morphologically similar to those cultivated with FBS, and showed a significantly higher proliferation rate. Von Kossa's staining revealed that osteoblasts from hPCy-MSCs in HS implemented with osteogenic induction factors, showed a better osteogenic activity, also confirmed by a significant upregulation of osteopotin (OPN) and matrix extracellular phosphoglycoprotein (MEPE).

Conclusions: HPCy-MSCs cultivated in HS showed phenotypic stability and a clear regenerative binding, thus, suggesting these two components as a clinically-grade construct for future endo-periodontal therapies.

© 2018 Società Italiana di Endodonzia. Production and hosting by Elsevier B.V. This is an open access article under the CC BY-NC-ND license (http://creativecommons.org/licenses/by-nc-nd/4.0/).

PAROLE CHIAVE
Medicina rigenerativa;
Cellule staminali;
Osteogenesi;
Human periapical cyst-MSCs;
Ricerca traslazionale.

Riassunto

Obiettivi: La nostra ricerca ha analizzato l'utilizzo del siero umano (HS) come mezzo di coltura sicuro e ''clinical-grade'', per uso clinico, utilizzando un nuovo modello cellulare: le hPC-MSCs. Questo articolo ha lo scopo di applicare concretamente il concetto di ''odontoiatria rigenerativa basata sui rifiuti biologici'', al fine di tradurlo in future applicazioni endo-periodontali.

Materiali e metodi: Le HPCy-MSCs sono state coltivate in 2 mezzi di coltura diversi, entrambi contenenti α-MEM: il primo con 10% di FBS (gruppo di controllo) e il secondo con il 10% di siero umano (gruppo di test).

Sono stati eseguiti saggi di proliferazione cellulare e di staminalità, espressione genica, analisi immunofenotipica e differenziamento osteogenico per verificare la nostra ipotesi di partenza. Campioni di cDNA sono stati amplificati con qPCR.

Gli esperimenti sono stati eseguiti in triplicato e analizzati con software statistici.

Risultati: Le hPC-MSC coltivate in un terreno con HS erano morfologicamente simili a quelle coltivate con FBS e mostravano un tasso di proliferazione significativamente più alto. La colorazione di Von Kossa ha rivelato che gli osteoblasti da hPC-MSC coltivate in HS implementato con fattori di induzione osteogenica hanno mostrato una migliore attività osteogenica, confermata anche da una significativa up-regolazione di osteopotina (OPN) e fosfoglicoproteina della matrice extracellulare (MEPE).

Conclusioni: Le HPCy-MSC coltivate in HS hanno mostrato stabilità fenotipica e un chiaro atteggiamento rigenerativo, suggerendo quindi questo protocollo come un approccio clinicamente valido per le future terapie endo-periodontali.

© 2018 Società Italiana di Endodonzia. Production and hosting by Elsevier B.V. Cet article est publié en Open Access sous licence CC BY-NC-ND (http://creativecommons.org/licenses/by-nc-nd/4.0/)

Introduction

The discovery of human periapical cysts-mesenchymal stem cells (hPCy-MSCs) has, for the first time, introduced dentistry in the concept of ''regenerative waste medicine'', the regenerative medicine obtainable from the reuse of biological waste to exploit it the clinical potential. HPCy-MSCs showed excellent ability to differentiate between osteogenic phenotypes and surprisingly toward the nervous tissue.[1–3]

Stem cell regeneration is, however, limited in clinical practice for the use of fetal bovine serum (FBS), used as a nutritional supplement in culture media. In fact, its xenogenic origin does not make FBS secure in patients applications. Despite several MSCs from different sources,[4] and a number of scaffold[5–12] have been already described and investigated in the literature, the main limitation to clinical applications seems to be the standardization of clinical-grade procedures, to overcome immunological and biological concernings.

In the light of the studies in the literature,[13–16] our research analyzed for the first time human serum (HS) as a safe and ''clinical-grade'' alternative in regenerative medicine, using a new cellular model: hPCy-MSCs, opening innovative scenarios on the concept of ''waste regenerative dentistry'' in future endo-periodontal applications.

Materials and methods

HPCy-MSCs were obtained as described in literature[1,3] and cultured in a medium containing α-MEM with 10% FBS (Gibco) in the Control group, and with 10% human serum (HS, Sigma) in the test group. The HS used in this study (AB plasma) is used as by the supplier protocol.

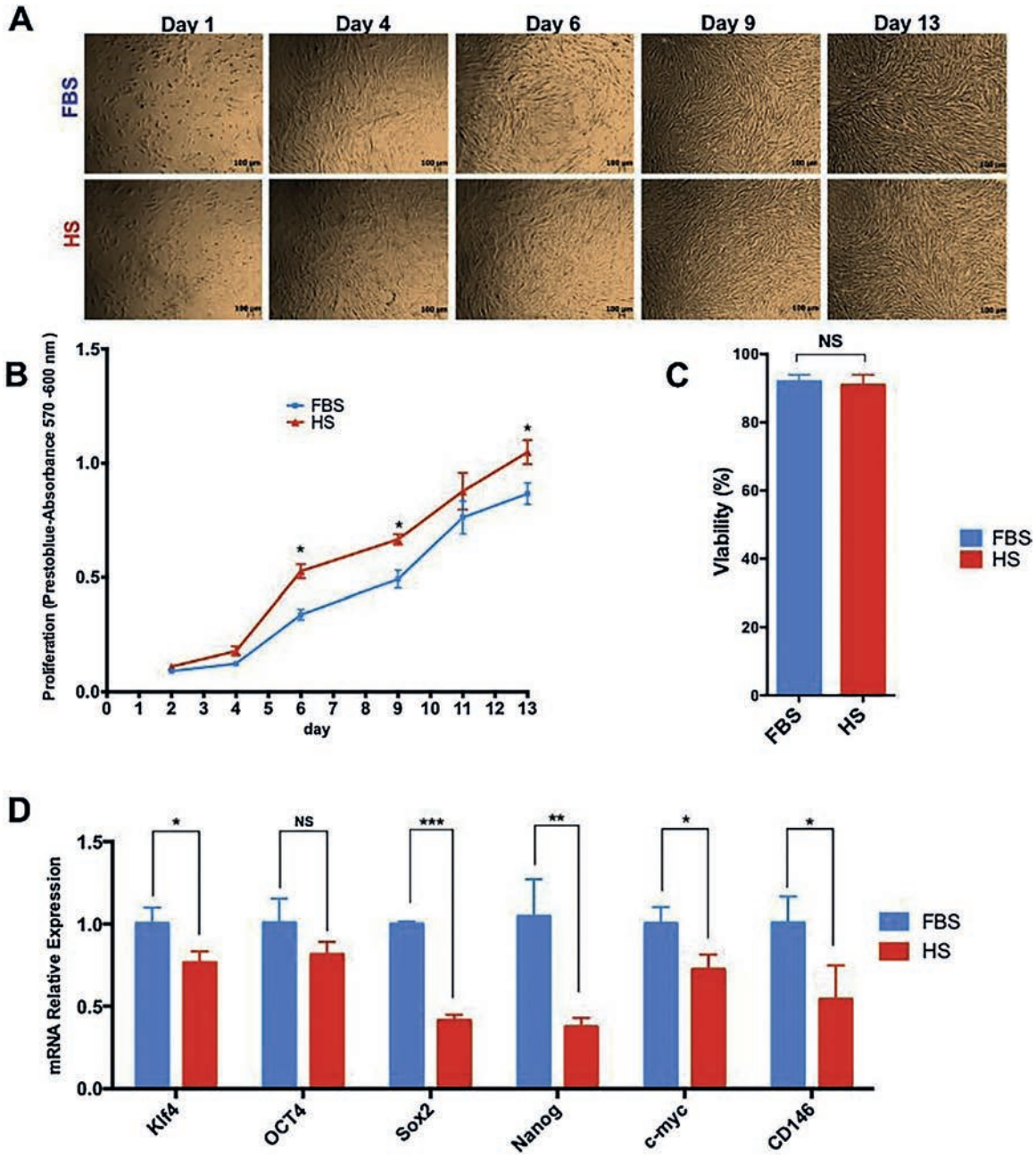

Figure 1 Proliferation, vitality, and expression of stem molecular markers in hPCy-MSCs grown in HS or FBS. (A) Characteristic morphology of hPCy-MSCs cultivated in 10% HS or 10% FBS (days 1—13). (B) Cell growth assay of hPCy-MSCs cultured in 10% HS or 10% FBS. $^{*}P < 0.05$. (C) Cell viability of hPCy-MSCs cultured in 10% HS or 10% FBS. (D) Expression of mRNA for the genetic indications of staminality: Klf4, OCT4, Sox-2, Nanog, c-myc and the CD146 pericitary marker in hPCy-MSCs cultured in 10% HS or 10% FBS analyzed by qRT-PCR. $^{*}P < 0.05$, $^{**}P < 0.01$, $^{***}P < 0.001$, N.S., not significant. FBS, fetal bovine serum; HS, human serum.

Cell proliferation tests, stem cell assays, gene expression, immunophenotypic analysis and osteogenic differentiation tests were performed with quantitative analysis to verify our hypothesis. CDNA samples were amplified with qPCR using sequences of primers.

Experiments were performed in triplicate, and data evaluated with GraphPad Prism software (statistically significant differences with: $^{*}P < 0.05$; $^{**}P < 0.01$; $P < 0.001$; N.S. = not significant).

Results

The hPCy-MSCs cultivated in a medium with HS were morphologically similar to those cultivated with FBS (Fig. 1A); however, hPCy-MSCs showed a significantly higher proliferation rate, from day 6 (Fig. 1B). Under both culturing conditions, the amount of vital hPCy-MSCs was about the same (>95%, Fig. 1C). The expression of the main stemness genes has been verified (Fig. 1D).

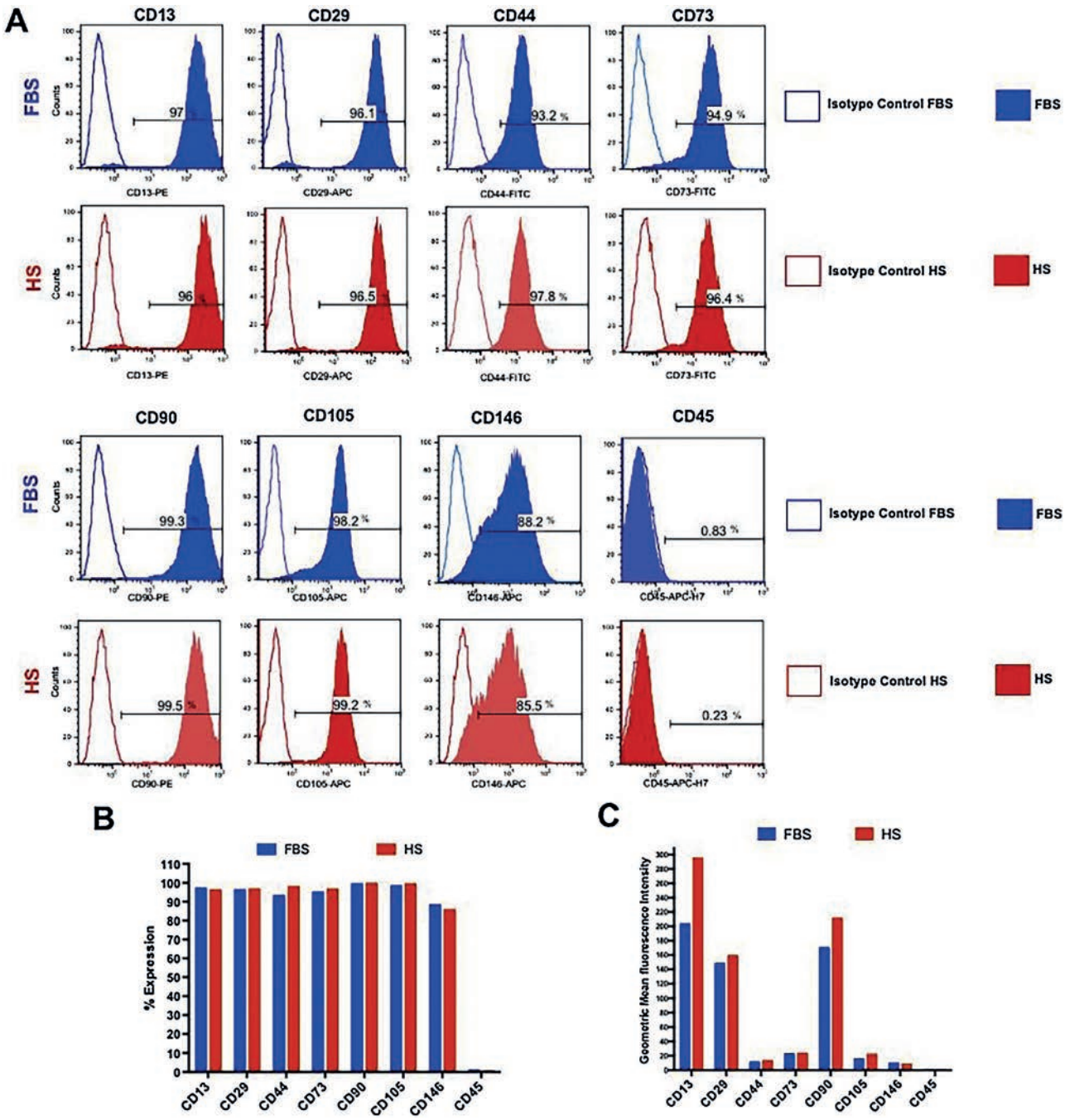

Figure 2 Expression of surface stem markers in hPCy-MSCs cultivated in HS or FBS. (A) Expression of surface stem markers: CD13, CD29, CD44, CD73, CD90, CD105, CD146 and CD45 in hPCy-MSCs cultivated in 10% HS compared with those grown in 10% FBS. The control of the isotype is indicated by the empty histogram, whereas the coloring of the antibodies is indicated by a solid histogram. (B) Percentage data of surface stem markers in hPCy-MSCs cultivated in 10% HS compared with those grown in 10% FBS. (C) Geometric mean fluorescence intensity of surface stem markers in hPCy-MSCs cultivated in 10% HS compared with those grown in 10% FBS. FBS, fetal bovine serum; HS, human serum.

Flow cytometry of phenotypic markers of hPCy-MSCs cultivated in HS and FBS (Fig. 2A) did not show statistically significant differences (Fig. 2B).

Von Kossa's staining revealed that hPCy-MSCs induced towards the osteogenic phenotype in HS, showed a greater differentiation than those cultivated in FBS (Fig. 3A and B). These observations were confirmed by a significant upregulation of osteopotin (OPN) and matrix extracellular phosphoglycoprotein (MEPE) in hPCy-MSCs cultivated in osteogenic and basal media containing HS (Fig. 3C).

Discussion

Patients treated with FBS-grown cells are exposed to a concrete risk of immunogenicity and the risk of transmission

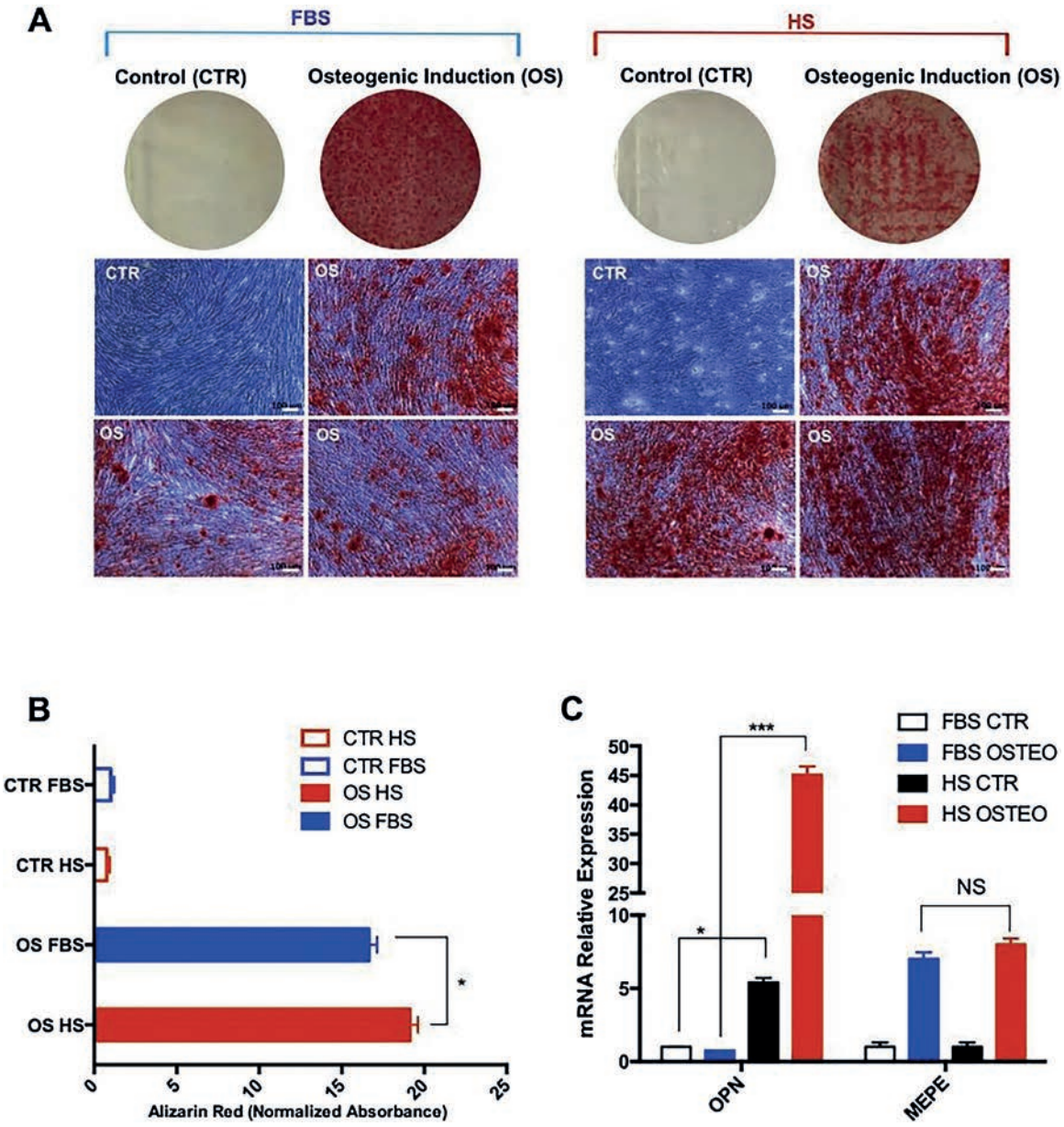

Figure 3 Osteogenic differentiation potential of hPCy-MSCs cultivated in HS or FBS. (A) Osteogenic differentiation of hPCy-MSCs, grown in HS, and compared with those grown in FBS, colored with red Alizarin. (B) Quantification by red blood alizarine test for the production of mineralized matrix in hPCy-MSCs cultivated in HS compared with those grown in FBS. $^{*}P < 0.05$. (C) Expression of osteogenic markers mRNA: OSP and MEPE in hPCy-MSCs cultivated in HS compared to those cultured in FBS after 21 days of differentiation (OS). FBS, fetal bovine serum; HS, human serum; CTR, control; OS, osteogenic differentiation. $^{*}P < 0.05$, $^{***}P < 0.001$, N.S., not significant.

of prion, bacterial or viral pathologies, making FBS dangerous for advanced cell therapy.[13]

For more than 30 years the scientific community has requested the use of alternative supplements to FBS[14] and in 2011 the European Commission, with the technical note EMA/410/01, suggested that animal medicines be avoided.

Recently, some authors have studied HS as an alternative to FBS on stem cell models of dental origin that are alternative to our[15,16]; however, the plasticity of hPCy-MSCs makes them ideal for regeneration to bone-like and neuron-like tissues.

Conclusions

HPCy-MSCs cultivated in HS showed excellent skills towards bone regeneration, also avoiding the risks derived from the use of FBS, thus, suggesting these two components as a clinically-grade construct for future endo-periodontal therapies.

Clinical relevance

Human periapical cysts-mesenchymal stem cells cultured with allogenic human serum are clinically usable, without

to use alternative xenogeneic serum. This ''clinical-grade'' procedure, together with the great plasticity of hPCy-MSCs and the recent experimental results reporting their ability to differentiate towards both bone-like, tooth-like and neuron-like tissues, makes the construct made from such a new MSCs and the ''safe'' culture medium an implantable biological device greatly indicated in the regeneration of endo-periodontal tissues.

Conflict of interest

We disclose no conflict of interest.

References

1. Marrelli M, Paduano F, Tatullo M. Cells isolated from human periapical cysts express mesenchymal stem cell-like properties. *Int J Biol Sci* 2013;**9**:1070—8.
2. Tatullo M, Falisi G, Amantea M, Rastelli C, Paduano F, Marrelli M. Dental pulp stem cells and human periapical cyst mesenchymal stem cells in bone tissue regeneration: comparison of basal and osteogenic differentiated gene expression of a newly discovered mesenchymal stem cell lineage. *J Biol Regul Homeost Agents* 2015;**29**:713—8.
3. Marrelli M, Paduano F, Tatullo M. Human periapical cyst-mesenchymal stem cells differentiate into neuronal cells. *J Dent Res* 2015;**94**:843—52.
4. Paduano F, Marrelli M, Amantea M, Rengo C, Rengo S, Goldberg M, et al. Adipose tissue as a strategic source of mesenchymal stem cells in bone regeneration: a topical review on the most promising craniomaxillofacial applications. *Int J Mol Sci* 2017;**18**.
5. Paduano F, Marrelli M, Alom N, Amer M, White LJ, Shakesheff KM, et al. Decellularized bone extracellular matrix and human dental pulp stem cells as a construct for bone regeneration. *J Biomater Sci Polym Ed* 2017;**28**:730—48.
6. Paduano F, Marrelli M, Palmieri F, Tatullo M. CD146 expression influences periapical cyst mesenchymal stem cell properties. *Stem Cell Rev* 2016;**12**:592—603.
7. Paduano F, Marrelli M, White LJ, Shakesheff KM, Tatullo M. Odontogenic differentiation of human dental pulp stem cells on hydrogel scaffolds derived from decellularized bone extracellular matrix and collagen type I. *PLOS ONE* 2016;**11**:e0148225.
8. Marrelli M, Falisi G, Apicella A, Apicella D, Amantea M, Cielo A, et al. Behaviour of dental pulp stem cells on different types of innovative mesoporous and nanoporous silicon scaffolds with different functionalizations of the surfaces. *J Biol Regul Homeost Agents* 2015;**29**:991—7.
9. Perniconi B, Coletti D, Aulino P, Costa A, Aprile P, Santacroce L, et al. Muscle acellular scaffold as a biomaterial: effects on C2C12 cell differentiation and interaction with the murine host environment. *Front Physiol* 2014;**5**:354.
10. Aulino P, Costa A, Chiaravalloti E, Perniconi B, Adamo S, Coletti D, et al. Muscle extracellular matrix scaffold is a multipotent environment. *Int J Med Sci* 2015;**12**:336—40.
11. Marrelli M, Pujia A, Palmieri F, Gatto R, Falisi G, Gargari M, et al. Innovative approach for the in vitro research on biomedical scaffolds designed and customized with CAD-CAM technology. *Int J Immunopathol Pharmacol* 2016;**29**:778—83.
12. Marrelli M, Maletta C, Inchingolo F, Alfano M, Tatullo M. Three-point bending tests of zirconia core/veneer ceramics for dental restorations. *Int J Dent* 2013;**2013**:831976.
13. Aldahmash A, Haack-Sørensen M, Al-Nbaheen M, Harkness L, Abdallah BM, Kassem M. Human serum is as efficient as fetal bovine serum in supporting proliferation and differentiation of human multipotent stromal (mesenchymal) stem cells in vitro and in vivo. *Stem Cell Rev* 2011;**7**:860—8.
14. Tekkatte C, Gunasingh GP, Cherian KM, Sankaranarayanan K. ''Humanized'' stem cell culture techniques: the animal serum controversy. *Stem Cells Int* 2011;**2011**:504723.
15. Jayme DW, Epstein DA, Conrad DR. Fetal bovine serum alternatives. *Nature* 1988;**334**:547—8.
16. Pisciotta A, Riccio M, Carnevale G, Beretti F, Gibellini L, Maraldi T, et al. Human serum promotes osteogenic differentiation of human dental pulp stem cells in vitro and in vivo. *PLoS ONE* 2012;**7**:e50542.

Giornale Italiano di Endodonzia (2018) **32**, 42—46

Available online at www.sciencedirect.com

ScienceDirect

journal homepage: www.elsevier.com/locate/gie

Cyclic fatigue resistance of Nickel-Titanium reciprocating instruments tested with an innovative kinematics

Impatto di una nuova cinematica sulla resistenza in fatica ciclica di strumenti reciprocanti

Francesco Iacono [a], Chiara Pirani [a,*], Luigi Generali [b], Maria Rosaria Gatto [a], Maria Giovanna Gandolfi [a], Carlo Prati [a]

[a] *School of Dentistry, Endodontic Clinical Section, Master in Clinical Endodontology, Department of Biomedical and Neuromotor Sciences, University of Bologna, Italy*

[b] *Department of Surgery, Medicine, Dentistry and Morphological Sciences with Transplant Surgery, Oncology and Regenerative Medicine Relevance (CHIMOMO), School of Dentistry, Endodontic Section, University of Modena and Reggio Emilia, Modena, Italy*

Received 6 March 2018; accepted 17 March 2018

KEYWORDS
Cyclic fatigue;
Endodontic instrumentation;
Kinematics;
Nickel-titanium instruments;
Reciprocating motion.

Abstract

Aim: To evaluate cyclic fatigue resistance of different Nickel-Titanium instruments tested with an innovative reciprocating kinematics.

Methodology: Eighty Nickel-Titanium reciprocating instruments were tested in cyclic fatigue resistance: WaveOne Primary (n = 20), WaveOne Gold Primary (n = 20), Reciproc R25 (n = 20) and Reciproc Blue R25 (n = 20). The cyclic fatigue of each brand was measured with two different motors and kinematics settings: (1) X-Smart Plus (Denstply Maillefer) used in ''WaveOne All'' or ''Reciproc All'' setting, according to manufacturer's instruction; (2) a 4:1 contra-angle (Cefla, Imola, Italy) with an experimental kinematics (Goldspeed EVOE4 — Cefla, Italy) (EVO) with different rotation angles and based on a sinusoidal acceleration. The time to fracture in an artificial stainless-steel canal (90° angle and a 5-mm radius of curvature) was digitally recorded. Mean life, beta (failure rate) and eta (characteristic life i.e. the number of seconds at which 63.2% of the product has failed) were calculated for each group and compared with Weibull analysis.

* Corresponding author at: Endodontic Clinical Section, Department of Biomedical and Neuromotor Sciences (DIBINEM), University of Bologna, Alma Mater Studiorum, Bologna, Italy. Tel.: +39 051 2088126; fax: +39 051 225208.
E-mail: chiara.pirani4@unibo.it (C. Pirani).

https://doi.org/10.1016/j.gien.2018.03.004
1121-4171/© 2018 Società Italiana di Endodonzia. Production and hosting by Elsevier B.V. This is an open access article under the CC BY-NC-ND license (http://creativecommons.org/licenses/by-nc-nd/4.0/).

Results: Instruments tested with the kinematics EVO presented higher values of eta in all groups. Reciproc Blue showed the highest eta value (233.05) and Wave One Gold the lower failure probability (46.98%). Wave One instruments showed similar fatigue resistance when tested with EVO or X-Smart.
Conclusion: Tested kinematics with different angles and based on sinusoidal reciprocating acceleration had a positive impact on fatigue lifetime of reciprocating instruments. Present findings suggest the possibility of future improvements in the clinical use of reciprocating files.
© 2018 Società Italiana di Endodonzia. Production and hosting by Elsevier B.V. This is an open access article under the CC BY-NC-ND license (http://creativecommons.org/licenses/by-nc-nd/4.0/).

PAROLE CHIAVE
Cinematica;
Fatica ciclica;
Strumenti Nichel-Titanio;
Strumentazione endodontica;
Movimento reciprocante.

Riassunto
Obiettivi dello studio: Scopo dello studio è stato quello di valutare l'impatto di una nuova cinematica con differenti angoli di rotazione e controrotazione sugli strumenti disegnati per il movimento di reciprocazione.
Materiali e Metodi: La fatica ciclica di 80 strumenti NiTi reciprocanti è stata misurata in un canale metallico artificiale con angolo di 90° e con raggio di 5 mm, con diverse cinematiche di reciprocazione.

Sono stati testati 8 gruppi di strumenti (n = 10): Gruppo 1: WaveOne Primary in modalità "WaveOne All" utilizzando il motore X-Smart Plus (Dentsply Maillefer); Gruppo 2: WaveOne Gold Primary (Dentsply Maillefer) in "WaveOne All" con X-Smart Plus; Gruppo 3: Reciproc R25 (VDW) in "Reciproc All" con X-Smart Plus; Gruppo 4 Reciproc Blue (VDW) R25 in "Reciproc All" con X-Smart Plus. Altri 4 gruppi degli stessi strumenti sono stati testati utilizzando la nuova cinematica di reciprocazione (EVO E4, Cefla, Imola, Italy) con angoli differenti e basata sul concetto di accelerazione sinusoidale, utilizzando uno specifico motore sperimentale con un contrangolo 4:1 (CEFLA, Imola, Italy). Gruppo 5: WaveOne Primary in modalità "WaveOne" utilizzando il sistema EVO E4 (Cefla); Gruppo 6: WaveOne Gold Primary in "WaveOne" con EVO E4; Gruppo 7: Reciproc R25 in modalità "Reciproc" con EVO E4; Gruppo 8: Reciproc Blue R25 in "Reciproc" con EVO E4.

L'analisi statistica Weibull è stata utilizzata per calcolare e confrontare la media (*mean life*), beta (*failure rate)* e eta (il numero di secondi cui il 63.2% degli strumenti ha fallito).
Risultati: Gli strumenti testati con cinematica EVO E4 hanno dimostrato un tempo medio (*mean life*) di frattura per fatica ciclica superiore agli strumenti testati con le cinematiche convenzionali di reciprocazione, in ogni gruppo. I Reciproc Blue hanno mostrato i più elevati valori di resistenza (233.05 eta) mentre i WaveOne Gold hanno dimostrato la più bassa probabilità di fallimento (46,98%).
Conclusioni: La nuova cinematica di reciprocazione basata su angoli differenti ed accelerazione sinusoidale ha dimostrato avere un impatto positivo sulla resistenza alla fatica ciclica degli strumenti testati. Inoltre è stato confermato che i nuovi trattamenti termici delle leghe migliorano le proprietà meccaniche degli strumenti. I risultati di questo studio aprono nuovi scenari sulle dinamiche di utilizzo dei sistemi reciprocanti ad oggi disponibili.
© 2018 Società Italiana di Endodonzia. Production and hosting by Elsevier B.V. Cet article est publié en Open Access sous licence CC BY-NC-ND (http://creativecommons.org/licenses/by-nc-nd/4.0/)

Introduction

Over last years, several strategies in endodontic instrumentation have been proposed by manufacturers with the aim to reduce procedural errors and fractures of Nickel-Titanium (NiTi) instruments.[1,2]

The use of different movements and kinematics of the files to shape the canals has been studied from sixties and seventies. Also Professor Francesco Riitano contributed in developing an innovative device to reduce errors and fractures during instrumentation procedures.[3,4]

In 2008 Yared[5] relaunched the reciprocating motion (RM) by proposing the use of a ProTaper F2 used for canal preparation in a clockwise (CW) and counterclockwise (CCW) direction. Thereafter several studies had shown a longer lifespan of NiTi instruments used in RM in comparison with continuous rotation.[6–8] In 2011 Wave One (Denstply Maillefer, Baillagues, Switzerland), and Reciproc (VDW, Munich, Germany) have been launched on the market with the intention to simplify and shorten the endodontic procedures.[9,10] Recently, the heat treatment of M-Wire NiTi alloy induced the development of Gold and Blue alloy and consequently the passage from WaveOne and Reciproc to WaveOne Gold (Denstply Maillefer, Baillagues, Switzerland) and Reciproc Blue (VDW, Munich, Germany).

Manufacturers recommend the use of these instruments with a specific motor and pre-set reciprocation modes.

Nevertheless, several possibilities exist for kinematics of RM, and the performances are consequently influenced.[11,12] For example, decreasing the reciprocation range of the instruments results in increased cyclic resistance with less transportation but in longer preparation time.[13] To date, relatively few studies evaluated the differences between several modified kinematics of reciprocation (different speed and/or angles).[11–13]

Recently a new endodontic motor (Cefla, Imola, Italy) has been engineered with different features in terms of engaging and disengaging rotation angles and introducing the concept of sinusoidal acceleration to every rotation reversal of the reciprocating movement. This motor is part of an innovative dental unit (Cefla, Imola, Italy).

To the best of our knowledge, no research had investigated the influence of this new kinematics on the fatigue resistance of NiTi Files. Therefore the aim of this study was to test the cyclic fatigue of different generations of NiTi designed for the reciprocation, assessing the impact of the new kinematics on their fatigue resistance.

Materials and methods

A sample of 80 NiTi reciprocating instruments was tested: WaveOne Primary ($n = 20$), WaveOne Gold Primary ($n = 20$), Reciproc R25 ($n = 20$) and Reciproc Blue R25 ($n = 20$), Instruments were distributed in 8 experimental groups ($n = 10$) as shown in Table 1.

The cyclic fatigue resistance of each brand was measured with two different motors and kinematics settings as reported in Table 1: (1) X-Smart Plus (Denstply Maillefer, Baillagues, Switzerland) endodontic motor used respectively in "WaveOne All" or "Reciproc All" setting, according to manufacturer's instruction; (2) a 4:1 contra-angle (Cefla, Imola, Italy) with the modified kinematics (Goldspeed EVOE4 – Cefla, Italy) (EVO).

A custom-made device, specifically designed for cyclic fatigue tests, was used (Fig. 1). Instruments were tested in a metal block made from stainless steel AISI 300 with a simulated tapered canal (90° angle of curvature and a-5 mm radius). A slipping plexiglass top face cover allowed visualization of the instruments in the canal. The canal was filled with glycerine, reducing friction and heat release. The electric handpiece was mounted on a mobile apparatus providing a precise and standardized placement of each instrument inside the artificial canal. All the files were reciprocated until the occurrence of the fracture and the time to fracture was visually recorded with a digital stopwatch (3 M ESPE, St. Paul, MN, USA).

Table 1 Group ($n = 10$) of the tested instruments with different motors and kinematics settings.

	Instrument	Motor	Kinematics
Group 1	WaveOne	X-Smart	WaveOne All
Group 2	WaveOne	EVOE4	WaveOne
Group 3	WaveOne Gold	X-Smart	WaveOne All
Group 4	WaveOne Gold	EVOE4	WaveOne
Group 5	Reciproc	X-Smart	Reciproc All
Group 6	Reciproc	EVOE4	Reciproc
Group 7	Reciproc Blue	X-Smart	Reciproc All
Group 8	Reciproc Blue	EVOE4	Reciproc

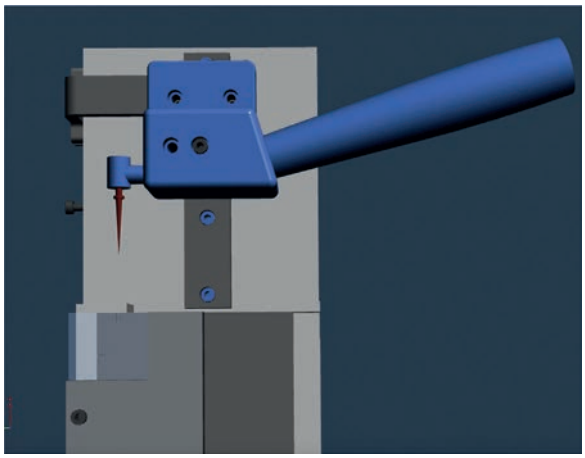

Figure 1 3D reconstruction of the fatigue test device used in the present study.

Mean life, beta (failure rate) and eta (characteristic life i.e. the number of seconds at which 63.2% of the product has failed) were calculated for each group and compared with Weibull analysis.

Results

The mean life, beta (failure rate) and eta (characteristic life i.e. the number of seconds at which 63.2% of the product has failed) were calculated for each group and were compared with Weibull analysis (Table 2). The mean life of instruments tested with the kinematics EVO was generally higher, presenting a greater proportion of instruments with higher values of eta in all groups. Reciproc Blue were significantly the most resistant instruments, irrespective of kinematics, and lasted significantly longer than Reciproc. WaveOne Gold demonstrated a higher resistance than WaveOne with EVO motor, showing also the lowest failure probability (beta) among groups (46.98%). WaveOne instruments showed similar fatigue resistance when tested with EVO or X-Smart Kinematics.

Discussion

In this research the influence of different kinematics on the fatigue life of four different reciprocating instruments was tested. Fatigue resistance of NiTi instruments is associated with the propagation of a superficial crack because of alternating tensile and compressive cycles in curved canal,[14] and is influenced by movement kinematics (continuous or reciprocating motion).[15] RM permits to the instrument to complete one full rotation after more reciprocating cycles (depending on the different angles),[6,11] which means that more time is needed for one entire rotation when compared with continuous rotation. In particular, angles of rotation and contra-rotation, acceleration, deceleration and speed are well-known parameter that may affect the endurance and the preparation time[11–13] of NiTi reciprocating instruments. Findings of the present study demonstrated that kinematics EVO significantly influences the cyclic fatigue resistance of

Table 2 Weibull analysis of fatigue resistance of the tested groups. Mean life, beta (failure rate) and eta (characteristic life, i.e. the number of seconds at which 63.2% of the product has failed) are reported.

Group	Instrument/kinematics	Mean life (s)	beta	eta
Group 1	WaveOne — X Smart	76.482	2.311	85.81
Group 2	WaveOne — EVOE4	81.537	3.666	90.51
Group 3	WaveOne Gold — X-Smart	77.88	8.206	82.38
Group 4	WaveOne Gold — EVOE4	127.71	7.715	136.07
Group 5	Reciproc — X-Smart	126.45	6.181	135.73
Group 6	Reciproc — EVOE4	171.23	2.808	196.70
Group 7	Reciproc Blue — X-Smart	132.73	7.972	136.43
Group 8	Reciproc Blue — EVOE4	215.88	5.651	233.05



Figure 2 ESEM micrograph (1500×) of the middle third of a root canal instrumented with WaveOne.

tested files. In fact, the mean life of instruments tested with the kinematics EVO was higher and with a greater proportion of instruments with higher values of eta in all groups.

The recently engineered EVO motor by Cefla imparts different engaging and disengaging rotational angles (angles of this motion are patent pending and cannot be fully disclosed) and confers a sinusoidal acceleration during every rotation reversal of the reciprocating movement. The rationale behind this kinematics is to generate a smoother transition between rotation and contra-rotation, permitting a more accurate control of the torque and reducing the stress of the instrument through an incremental angular acceleration of the speed. Further investigations should evaluate the impact of this innovative kinematics on the torsional loads which the instruments are subjected during canal instrumentation and the effect of this reciprocating kinematics on root canal dentinal surface through scanning electron microscope (SEM). In fact, several studies[16–18] confirmed SEM as a suitable method for the comparison of dentin surface morphology after instrumentation, as shown in Fig. 2.

According to other studies,[19,20] in the present research the cyclic fatigue resistance of reciprocating instruments was reported as time to fracture (seconds). This to minimize the errors of questionable data available on the pre-set kinematics from those claimed by the manufacturers, mainly in terms of engaging/disengaging angles and rotational speed.[21] Further studies should deeper investigate the parameters of the tested kinematics to better understand the role of different angles and speed on the cyclic life of reciprocating instruments.

As part of this study, Weibull analysis was conducted with respect to ''life data'', measured in hours, miles, cycles or any other metric, defining the period of successful operation of a particular product.[22,23] This type of analysis focuses on information related to extreme-value distribution and the lower values that may be more crucial for clinicians and has been already used as an adequate model for evaluating the cyclic fatigue resistance of NiTi files.[24,25]

Another interesting aspect of the present study is the comparison of NiTi instruments subjected to different thermomechanical treatments. Is it well known that one of the most successful strategy to improve the mechanical properties of NiTi files is to optimize the microstructure of NiTi alloys through different thermomechanical processes.[24] This determines the characteristics of the microstructural phases and adjusts the transition temperatures of the alloy.[26–30] WaveOne files have been enhanced from M-wire to Gold alloy treatment.[31,32] In this *in vitro* research the comparison between WaveOne Gold and WaveOne resulted in a statistically higher fatigue resistance of WaveOne Gold only with EVO, while no significant differences were found with X-Smart. Even the heat treatment of Reciproc has been changed from M-wire to Blue alloy. According to the literature[33–35] our findings suggested an improved fatigue resistance of the new Reciproc Blue instruments that resulted the most resistant files irrespective of the tested kinematics.

Conclusions

The findings of this *in vitro* research showed the positive impact of new kinematics on fatigue life of reciprocating instruments, suggesting the possibility of future improvements in the clinical use of reciprocating files. Further study should deeper evaluate the kinematics evaluating also the impact of the sinusoidal reciprocating motion on the instruments during canal instrumentation.

Clinical relevance

Present results demonstrated that innovative kinematics has a positive impact on fatigue life of reciprocating instruments, thus suggesting new scenario in the clinical use of NiTi reciprocating files.

Conflict of interest

The authors declare not to have any conflict of interest

References

1. Peters OA. Current challenges and concepts in the preparation of root canal systems: a review. *J Endod* 2004;**30**:559—67.
2. Parashos P, Messer HH. Rotary NiTi instrument fracture and its consequences. *J Endod* 2006;**32**:1031—43.
3. Bassi E, Riitano F. Andodontic instrument for concurrent programmed boring, spraying and cleansing of dental root channels. Patent US3747216; 1973.
4. Riitano F. Anatomic endodontic technology (AET) — a crown-down root canal preparation technique: basic concepts, operative procedure and instruments. *Int Endod J* 2005;**38**:575—87.
5. Yared G. Canal preparation using only one Ni-Ti rotary instrument: preliminary observations. *Int Endod J* 2008;**41**:339—44.
6. You SY, Bae KS, Baek SH, et al. Lifespan of one nickel-titanium rotary file with reciprocating motion in curved root canals. *J Endod* 2010;**36**:1991—4.
7. De-Deus G, Moreira EJ, Lopes HP, Elias CN. Extended cyclic fatigue life of F2 Pro-Taper instruments used in reciprocating movement. *Int Endod J* 2010;**43**:1063—8.
8. Pirani C, Ruggeri O, Cirulli PP, Pelliccioni GA, Gandolfi MG, Prati C. Metallurgical analysis and fatigue resistance of WaveOne and ProTaper Nickel-Titanium instruments. *Odontology* 2014;**102**:211—6.
9. Çapar ID, Ertas H, Ok E, Arslan H, Ertas ET. Comparative study of different novel nickel-titanium rotary systems for root canal preparation in severely curved root canals. *J Endod* 2014;**40**:852—6.
10. Generali L, Righi E, Todesca MV, Consolo U. Canal shaping with WaveOne reciprocating files: influence of operator experience on instrument breakage and canal preparation time. *Odontology* 2014;**102**:217—22.
11. Gambarini G, Rubini AG, Al Sudani D, Gergi R, Culla A, De Angelis F, et al. Influence of different angles of reciprocation on the cyclic fatigue of nickel-titanium endodontic instruments. *J Endod* 2012;**38**:1408—11.
12. Arslan H, Alsancak M, Doğanay E, Karatas E, Çapar D, Ertas H. Cyclic fatigue analysis of Reciproc R25® instruments with different kinematics. *Aust Endod J* 2016;**42**:22—4.
13. Saber Sel D, Abu El Sadat SM. Effect of altering the reciprocation range on the fatigue life and the shaping ability of WaveOne nickel-titanium instruments. *J Endod* 2013;**39**:685—8.
14. Sattapan B, Nervo GJ, Palamara JE, et al. Defects in rotary nickel-titanium files after clinical use. *J Endod* 2000;**26**:161—5.
15. Plotino G, Ahmed HMA, Grande NM, Cohen S, Bukiet F. Current assessment of reciprocation in endodontic preparation: a comprehensive review. Part II: properties and effectiveness. *J Endod* 2015;**41**:1939—50.
16. Prati C, Seleghini M, Ferrieri P, Mongiorgi R. Scanning electron microscopic evaluation of endodontic procedures on dentin morphology of human teeth. *J Endod* 1994;**20**:174—8.
17. Pirani C, Feletti G, Cretti R, Acquaviva GL, Marchionni S, Prati C. SEM evaluation of root canal dentin morphology after Ni-Ti instrumentation. *J Appl Biomater Biomech* 2009;**7**:116—22.
18. Bürklein S, Hinschitza K, Dammaschke T, Schäfer E. Shaping ability and cleaning effectiveness of two single-file systems in severely curved root canals of extracted teeth: Reciproc and WaveOne versus Mtwo and ProTaper. *Int Endod J* 2011;**45**:449—61.
19. Kim HC, Yum J, Kwak SW, Cheung GSP, Ko DH, Chung SM, et al. Cyclic fatigue and torsional resistance of two new nickel—titanium instruments used in reciprocation motion: Reciproc versus WaveOne. *J Endod* 2012;**38**:541—4.
20. Pedullà E, Grande NM, Plotino G, Palermo F, Gambarini G, Rapisarda E. Cyclic fatigue resistance of two reciprocating nickel—titanium instruments after immersion in sodium hypochlorite. *Int Endod J* 2013;**46**:155—9.
21. Fidler A. Kinematics of 2 reciprocating endodontic motors: the difference between actual and set values. *J Endod* 2014;**40**:990—4.
22. Weibull W. A statistical distribution function of wide applicability. *J Appl Mech* 1951;**128**:293—7.
23. Life data analysis, http://www.weibull.com/basics/lifedata.htm (accessed 2.3.18).
24. Arias A, Perez-Higueras JJ, de la Macorra JC. Differences in cyclic fatigue resistance at apical and coronal levels of Reciproc and Waveone new files. *J Endod* 2012;**38**:1244—8.
25. Perez-Higueras JJ, Arias A, de la Macorra JC, Peters OA. Differences in cyclic fatigue resistance between ProTaper Next and ProTaper universal instruments at different levels. *J Endod* 2014;**40**:1477—81.
26. Shen Y, Zhou HM, Zheng YF, Campbell L, Peng B, Haapasalo M. Metallurgical characterization of controlled memory wire nickel-titanium rotary instruments. *J Endod* 2011;**37**:1566—71.
27. Pereira ES, Peixoto IF, Viana AC, Oliveira II, Gonzalez BM, Buono VT, et al. Physical and mechanical properties of a thermomechanically treated NiTi wire used in the manufacture of rotary endodontic instruments. *Int Endod J* 2012;**45**:469—74.
28. Hieawy A, Haapasalo M, Zhou H, Wang ZJ, Shen Y. Phase transformation behavior and resistance to bending and cyclic fatigue of ProTaper Gold and ProTaper universal instruments. *J Endod* 2015;**4**:1134—8.
29. Iacono F, Pirani C, Generali L, Bolelli G, Sassatelli P, Lusvarghi L, et al. Structural analysis of HyFlex EDM instruments. *Int Endod J* 2017;**50**:303—13.
30. Iacono F, Pirani C, Generali L, Sassatelli P, Nucci C, Gandolfi MG, et al. Wear analysis and cyclic fatigue resistance of electro discharge machined NiTi rotary Instruments. *Giornale Italiano di Endodonzia* 2016;**30**:64—8.
31. Webber J. Shaping canals with confidence: WaveOne GOLD single-file reciprocating system. *Roots* 2015;**1**:34—40.
32. Özyürek T. Cyclic fatigue resistance of Reciproc, WaveOne, and WaveOne gold nickel-titanium instruments. *J Endod* 2016;**42**:1536—9.
33. Gündogar, Özyürek. Cyclic fatigue resistance of OneShape, HyFlex EDM, WaveOne Gold, and Reciproc blue nickel-titanium instruments. *J Endod* 2017;**43**:1192—6.
34. Keskin C, Inan U, Demiral M, Keleş A. Cyclic fatigue resistance of Reciproc Blue, Reciproc, and Waveone gold reciprocating instruments. *J Endod* 2017;**43**:1360—3.
35. De-Deus G, Silva EJ, Vieira VT, Belladonna FG, Elias CN, Plotino G, et al. Blue thermomechanical treatment optimizes fatigue resistance and flexibility of the reciproc files. *J Endod* 2017;**43**:462—6.

Giornale Italiano di Endodonzia (2018) **32**, 47—50

Available online at www.sciencedirect.com

ScienceDirect

journal homepage: www.elsevier.com/locate/gie

POSTER SESSION/SESSIONE POSTER

Removal of fiber posts during endodontic retreatments using ultrasonic tips: A comparison between two different endodontic fiber posts

Ritrattamento di denti trattati endodonticamente e ricostruiti con perni in fibra: Tecniche di rimozione, vantaggi e limiti

Lorenza Capriotti*, Katia Greco, Gaetano Paolone, Maria Teresa Sberna, Giuseppe Cantatore

Università degli Studi Vita-Salute San Raffaele, Milano, Italy

Received 27 February 2018; accepted 17 April 2018

KEYWORDS
Fiber post;
Retreatment;
Ultrasonic tips;
Temperature increase;
Thermographic measurements.

Abstract
Aim: The purpose of this study was to evaluate temperature changes generated on radicular surface of extracted monoradicular teeth during ultrasonic removal of fiber posts.
Methodology: Forty intact monoradicular teeth, with not less than 15 mm root canal length, with mature apex and without root fractures, were selected. After root canal instrumentation and obturation of teeth, dowel space preparation was obtained at 9 mm length. Samples were randomly divided into two groups according to the type of fiber post used: the first group received quartz fiber posts D.T. Light Post n. 0.5; the second group cemented silica fiber post TECHOLE S with central hole. Removal technique was performed with microblades ultrasonic tips, in particular Start-X #3. Operative protocol provided succession of dry use of ultrasonic inserts for a period of 25 s, air cooling for 25 s and water cooling for 25 s, until posts entire removal. Thermographic measurements were recorded taking photography and videos using Thermal Imaging Camera FLIR-One.
Results: Results show that dry use leads to rapid increase in root surface temperature beyond critical limit, while both air cooling and water one decreases it to lower value for both of groups. The best results were obtained by water cooling.

* Corresponding author at: Via Antonio Orsini 1, Ascoli Piceno 63100 (AP), Italy.
E-mail: lorenzacapriotti@gmail.com (L. Capriotti).
Peer review under responsibility of Società Italiana di Endodonzia.

Production and hosting by Elsevier

https://doi.org/10.1016/j.gien.2018.04.002
1121-4171/© 2018 Società Italiana di Endodonzia. Production and hosting by Elsevier B.V. This is an open access article under the CC BY-NC-ND license (http://creativecommons.org/licenses/by-nc-nd/4.0/).

Conclusions: Air or water cooling seems to be essential during the use of ultrasonic tips to reduce the risk of periodontal tissue and bone damage due to an excessive temperature raise. It's necessary to increase the samples number to conduct statistical analyses.
© 2018 Società Italiana di Endodonzia. Production and hosting by Elsevier B.V. This is an open access article under the CC BY-NC-ND license (http://creativecommons.org/licenses/by-nc-nd/4.0/).

PAROLE CHIAVE
Perni in fibra;
Ritrattamento;
Punte ultrasoniche;
Aumento temperatura;
Misurazioni termografiche.

Riassunto
Obiettivi: Lo scopo di questo lavoro è quello di valutare su denti estratti le variazioni di temperatura che si sviluppano lungo la superficie radicolare durante la rimozione ultrasonica di due tipologie di perni endocanalari in fibra.
Materiali e metodi: Sono stati selezionati 40 denti integri monoradicolari, con lunghezza canalare minima di 15 mm, apice maturo e assenza di fratture radicolari. Dopo preparazione ed otturazione canalare, è stato preparato un "dowel space" della profondità costante di 9 mm. I campioni sono stati divisi in due gruppi: nel gruppo A sono stati cementati perni in fibra di quarzo D.T. Light Post n. 0.5; nel gruppo B perni cavi in fibra di silice TECHOLE S. La procedura abrasiva dei perni è stata effettuata con punte ultrasoniche multilama StartX #3, alternando 25 secondi di lavoro a secco, con raffreddamento ad aria e con raffreddamento ad acqua fino alla completa rimozione del perno ed effettuando le misurazioni termografiche tramite Termocamera ad infrarossi Flir-One.
Risultati: Il lavoro a secco ha mostrato un brusco innalzamento della temperatura sulla superficie radicolare in entrambi i gruppi, mentre entrambe le tipologie di raffreddamento sono state efficaci nel mantenere bassi valori di temperatura. Il raffreddamento ad acqua ha ottenuto i risultati migliori.
Conclusioni: Risulta di primaria importanza la fase di raffreddamento durante l'uso degli inserti ultrasonici per evitare un eccessivo aumento della temperatura con la possibilità di indurre danni al tessuto parodontale circostante e all'osso alveolare. È necessario aumentare il numero dei campioni per ottenere risultati con possibili differenze statisticamente significative tra i due gruppi.
© 2018 Società Italiana di Endodonzia. Production and hosting by Elsevier B.V. Cet article est publié en Open Access sous licence CC BY-NC-ND (http://creativecommons.org/licenses/by-nc-nd/4.0/)

Introduction

When an endodontic retreatment of an element restored with fiber post is needed, it will be necessary to remove the post to complete "disassembling phases"; during this phase, however, an increase in the temperature of the root surface can occur, that could be a detrimental effect on the cells of the periodontal ligament and the alveolar bone.

The purpose of the study is to evaluate, through a thermographic analysis, if the temperature variations, that occur on the root surface of extracted teeth during the removal of two types of fiber posts with dedicated ultrasonic tips, go beyond physiologically values consented from the hard tissues surrounding the dental element.

Materials and methods

Forty single-rooted teeth (27 premolars, 8 incisors, 5 canines) with a root canal length greater than 15 mm, mature root apex and no signs of infractions or fractures on the root surface, were selected. Pulp chambers were opened and probing, pre-flaring and shaping of all the samples were performed with Protaper Universal from S1 to F2; later, the obturation of the canals was carried out with System B technique and Top Seal endodontic cement.

All clinical crowns were transversely sectioned at 1 mm from the cemento-enamel junction; then, a constant depth of 9 mm Post Space was performed with calibrated drill D.T. Light Universal #0.5. The samples were divided into two groups of 20 elements each:

- Group A: quartz fiber post (D.T. LIGHT-POST #0.5) cementation with dual Core-X Flow cement (Fig. 1A—H).
- Group B: silica fiber posts with central hole (TECHOLE S) cementation with NEW TECHCEM dual self-adhesive cement (Fig. 2A—H).

The removal due to wear of fiber post was performed with ultrasonic tips Start-X # 3, until their total removal, alternating:

- 25 s of dry work;
- 25 s of work with air cooling of Stropko syringe;
- 25 s of work with water cooling by waterport of ultrasonic tip.

During the procedure, the thermographic measurements were performed by means of Flir-One Infrared Thermal Imaging Camera, recording the highest and lowest values of the temperature reached on the root surface for all the phases of the working protocol and taking thermographic images after each phase.

Results

Dry use of ultrasonic inserts led to a more abrupt temperature raising on the root surface up to a maximum value of 46.6 °C (Fig. 3). Higher values of temperature were recorded during dry use in group A, with a difference of 4.1 °C compared to Group B. Air cooling using Stropko syringe, although

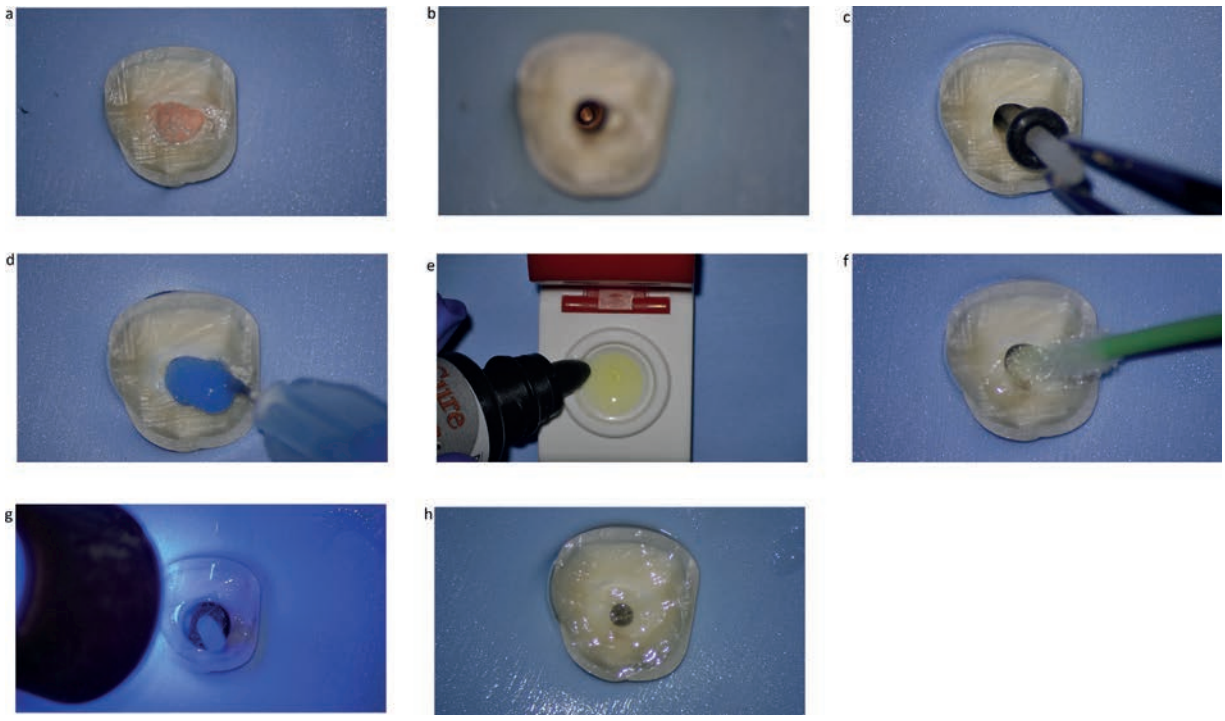

Figure 1 Cementation phases of quartz D.T. Light Post (Group A).

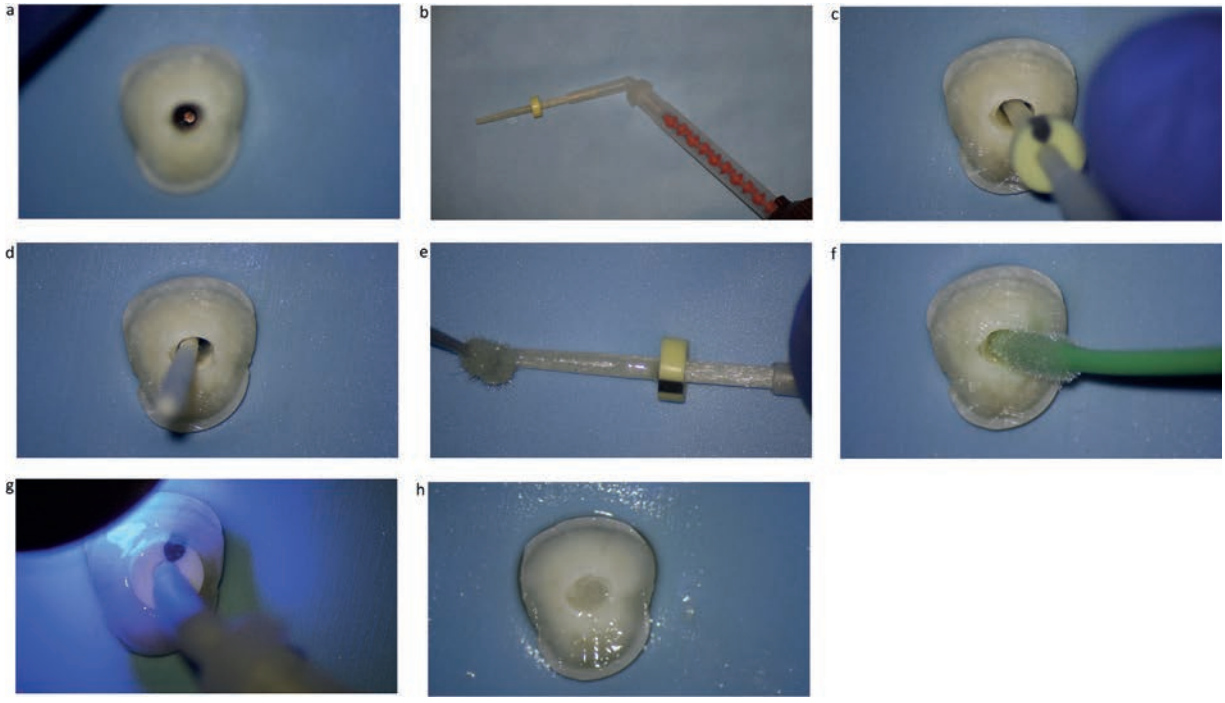

Figure 2 Cementation phases of silica TECHOLE Post (Group B).

effective in both groups, was most significant in Group B, while water cooling appeared to be equivalent in both groups. However, the best results were obtained with the use of water cooling in both group: the water, that come from the tip itself, thanks to the presence of waterport in the ultrasonic Start-X tips, is able to effectively cool the insert during the phases of work.

Discussion

During the retreatment of teeth reconstructed with fiber posts, the removal by wear of the post with dedicated ultrasound tips can cause an increase in the external temperature of the root surface with more or less severe com-



Figure 3 Termographic image of the value of the maximum temperature reached.

plications for the periodontal ligament. In particular, it would seem to play a decisive role the dry or under-cooling use of dedicated ultrasonic tips. Dry use of ultrasonic tips would seem to cause an increase in the values of the external root temperature beyond the allowed physiological limits and would seem to be more relevant in the case of removal of high density fiber posts (DT LIGHT-POST), compared to the removal of hollow posts (TECHOLE). Although the air-cooled procedure was effective, the most suitable procedure would seem to be water-based to maintain the ''working'' temperature within the physiological body temperature range. This procedure, in fact, would record temperatures closer to those of body temperature regardless of the type of post used.

Conclusions

In a case of endodontic retreatment it would be preferable to use ultrasonic inserts with ''waterport'' because, among the many advantages, it would effectively lower the temperature on the tip and on the work area, safeguarding the health of the tooth-ligament-alveolar bone complex.

Clinical relevance

The cooling of the ultrasonic tips would be fundamental for the protection of the tooth support tissues during the fiber posts removal.

Conflict of interest

The authors declare that they have no conflict of interest.

Acknowledgement

The authors thank Prof. Enrico Gherlone for his assistance in this study.

Further reading

1. Basrani B, Haapasalo M. Update on endodontic irrigating solutions. *Endod Top* 2012;27:74—102.2. Dineshkumar MK, Vinothkumar TS, Arathi G, Shanthisree P, Kandaswamy D. Effect of ethylene diamine tetraacetic acid, MTADTM, and HEBP as a final rinse on the microhardness of root dentin. *J Conserv Dent* 2012;15(2):170—173.3. Cantatore G, Malagnino VA, Passariello P. Indagine al SEM di 2 differenti metodiche di detersione canalare. *G It Endo* 1994;4(8):151—156.4. Meredith N, Sherriff M, Setchell DJ, Swanson SA. Measurement of the microhardness and Young's modulus of human enamel and dentine using an indentation technique. *Arch Oral Biol* 1996;41:539—45.5. Libman WJ, Nicholls JI. Load fatigue of teeth restored with cast posts and cores and complete crowns. *Int J Prosthodont* 1995;8:155—61.

LETTERA DEL PRESIDENTE

Carissimi Soci,
il tempo scorre veloce e sono qui a scriverVi questa mia lettera per il Primo numero del Giornale Italiano di Endodonzia del 2018: il secondo e ultimo anno di mandato come Presidente SIE.

Come preannunciato nella mia prima lettera, è stato un anno davvero denso di lavoro per noi del **Consiglio Direttivo**: abbiamo lavorato a stretto contatto e portato a termine tutti gli obiettivi prefissati dall'inizio del mio incarico.

- Tutti le **Manifestazioni Regionali** hanno avuto un vistoso incremento del numero dei partecipanti nel 2017 e ancor di più in tutti gli eventi svolti nella prima metà del 2018. Un successo dovuto all'instancabile lavoro svolto dai Segretari Regionali e dai loro Coordinatori, che ringrazio per l'attenzione a loro dedicata.

- Gli **Endodontic Courses,** nella doppia versione basica e advance e distribuiti su tutto il territorio, oramai non hanno neanche più bisogno di presentazioni: il loro format conosciuto e il programma accattivante attirano i partecipanti che si muovono da tutta Italia e fanno a gara per prenderVi parte.

- **Il Closed Meeting** dedicato ai Soci Attivi, tenutosi a Rimini nel 2017, avendo una posizione favorevole, ha visto la partecipazione di più di 100 persone ed è stato meta di tre giorni di grande lavoro da parte di tutte le commissioni dedite ad approntare il Congresso e la programmazione SIE del 2018.

- In ultimo lasciatemi spendere due parole sul grande successo avuto dal **35° Congresso Nazionale** tenutosi a Bologna dal 9 all'11 Novembre 2017 dal titolo *"ENDODONZIA TRA FONDAMENTI E INNOVAZIONI"* che ha visto la partecipazione di quasi 1100 persone. Ottima organizzazione e feedback positivissimi dalle 25 aziende sponsor che hanno supportato l'evento.

Il Corso Pre-Congresso "L'ENDODONZIA CHIRURGICA", tenuto da tre altissime personalità della scuola torinese, ha visto una platea di più di 520 odontoiatri e studenti di Endodonzia attenti e partecipi per tutto il pomeriggio di Giovedì. Le importanti **Relazioni** di altissimo livello susseguite nella Sala Auditorium per tutto il Congresso, **le Tavole Cliniche SIE e le Tavole Cliniche Sponsorizzate**, **le Master Clinician Session Live, i Premi Garberoglio, Riitano, Lavagnoli e Poster e poi tutti gli Eventi Sociali** hanno fatto si che il nostro Congresso si confermasse, una volta di più, di grande spessore e di impatto per la nostra disciplina.

Per tutto questo permettetemi di ringraziare ancora una volta il Segretario, Roberto Fornara, che nel Suo primo anno di mandato ha gestito la Segreteria in maniera esemplare, facendo solo gli interessi della SIE e svolgendo a parer mio un egregio lavoro.

Il Consiglio Direttivo ed io personalmente, nei primi mesi del 2018 abbiamo lavorato all'**Accreditamento** della nostra Società a livello ministeriale e per questo ringrazio il CIC per il lavoro svolto in questi ultimi anni. Un' importantissima funzione per l'accreditamento delle Società Scientifiche la sta svolgendo la CAO Nazionale: ringrazio Pippo Renzo per il lavoro svolto in questi anni, ma permettetemi di augurare il buon lavoro a Raffaele Iandolo la cui sensibilità nei confronti della nostra società è a me ben nota.

Un'altra innovazione del prossimo biennio sarà l'accorpamento di tutte Sezioni Regionali sotto la guida di quattro **Macro-Aree,** dandone la responsabilità del coordinamento a partire dal 2019 a quattro bravi colleghi ai quali auguro un sereno e proficuo lavoro:

Area NORD-OVEST: Val D'Aosta, Piemonte, Liguria, Toscana e Sardegna - COORDINATORE: Davide Castro

Area NORD-EST: Lombardia, Emilia-Romagna e Triveneto - COORDINATORE: Stefano Gaffuri

Area CENTRO: Lazio, Marche, Abruzzo e Umbria - COORDINATORE: Luigi Scagnoli

Area SUD: Puglia, Campania, Sicilia, Basilicata, Calabria, Molise - COORDINATORE: Giorgio Vittoria

Infine, si avvicina il nostro **III Congresso Internazionale**, previsto dall'8 al 10 Novembre 2018 e che avrà come titolo: **"Endodontics: clinical solutions".**

La disponibilità di Enrico Gherlone e la grande conoscenza dei luoghi da parte di Maria Teresa Sberna ci permetterà di godere di una delle migliori location della città di Milano: *il San Raffaele Congress Center.*

Nella prossima lettera Vi renderò partecipi del programma e delle novità relative alla realizzazione del Congresso.

Vi saluto tutti con grande affetto

Il Presidente SIE
Francesco Riccitiello

STRUTTURA SOCIETARIA

COORDINATORE CULTURALE

Dott. Mauro Rigolone
Via Giovine Italia,18
13100 Vercelli (VC)
Tel. 0161-503450
Fax 0161-503450
e-mail: studiorigolone@hotmail.com

COORDINATORE DELLE SEZIONI REGIONALI

Dott. Cristian Coraini
Piazza Repubblica, 32
20124 Milano (MI)
Tel. 02-781924
Cell 327-0444922
e-mail: cristian.coraini@fastwebnet.it

SEGRETARI REGIONALI 2017/2018

SAE Abruzzo
dott. Lucio Daniele
Viale Corrado IV, 6
67100 L'Aquila (AQ)
tel. 0862-25469
fax 0862-422309
cell. 333-7696075
drlucio@tiscali.it

SEB Basilicata
dott. Eduardo Veralli
Via XX Settembre,19
85100 Potenza (PO)
tel. 0971-22170
cell. 338-7028109
eduardo@studioveralli.191.it

SEC Campania
dott.ssa Paola Carratù
Via Belvedere, 222
80127 Napoli (NA)
tel. 081-642373
cell. 349-3884875
paolacarratu@gmail.com

SERE Emilia Romagna
dott. Luca Venuti
Via Carlo Jussi, 79
40068 San Lazzaro di Savena (BO)
tel. 051-321489
cell. 338-2249860
lucavenuti@fastwebnet.it

SER Lazio
dott.ssa Alessandra D'Agostino
Via Bellini, 5
03043 Cassino (FR)
tel. 0776-312378
cell. 328-3071792
alessandradagostino74@gmail.com

SEL Liguria
dott. Luca Ivaldi
Via Leopardi,18
15011 Acqui Terme (AL)
cell. 347-3032513
l.ivaldi@libero.it

SLE Lombardia
dott. Stefano Gaffuri
Via Napoleone, 50
25039 Travagliato (BS)
tel. 030-6864844
fax 030-6866189
cell. 335-5866543
info@gaffurigalvaniodontoiatri.it

SME Marche
dott. Stefano Vecchi
Via Cappannini, 39/d
60030 Serra dè Conti (AN)
tel. e fax 0731-878355
cell. 335-5631486
vecchistefano@interfree.it

SPE Piemonte e Valle d'Aosta
dott. Davide Fabio Castro
Via Oioli, 6B
28013 Gattico (NO)
tel. 0331-735276
cell. 338-7075126
davidefabio.castro@gmail.com

SEP Puglia
dott. Giuseppe Squeo
Via G. Murat, 98
70123 Bari (BA)
tel. 080-9189351
cell. 347-6296042
giuseppesqueo2@virgilio.it

SES Sardegna
dott.ssa Claudia Dettori
Via Tolmino, 7
09122 Cagliari (CA)
tel. 070-743758
fax 070-490329
claudia.dettori@gmail.com

SSE Sicilia
dott. Alfio Pappalardo
Via Canfora, 50
95128 Catania (CT)
tel. e fax 095-442934
alfiopappalardo@tiscali.it

STE Triveneto
dott. Alberto Mazzocco
Via Cà di Cozzi, 41/a
37124 Verona (VR)
tel. e fax 045-8344430
cell. 349-2504726
mazzocco.alberto@gmail.com

STRUTTURA SOCIETARIA

SOCI ONORARI

Borsotti Prof. Gianfranco
Bresciano Dott. Bartolo
Cavalleri Prof. Giacomo
Mantero Prof. Franco
Pecora Prof. Gabriele
Perrini Dott. Nicola
Vignoletti Dott. Gianfranco

SOCI ATTIVI

Agresti Dott. Daniele
Altamura Dott. Carlo
Amato Prof. Massimo
Ambu Dott. Emanuele
Amoroso D'Aragona Dott.ssa Eva
Ascione Dott.ssa Maria Rosaria
Autieri Dott. Giorgio
Badino Dott. Mario
Barattolo Dott. Raniero
Barboni Dott.ssa Maria Giovanna
Becciani Dott. Riccardo
Beccio Dott. Roberto
Bertani Dott. Pio
Berutti Prof. Elio
Bianco Dott. Alessandro
Bonaccorso Dott. Antonino Maria
Bonacossa Dott. Lorenzo
Bonelli Bassano Dott. Marco
Borrelli Dott. Marino
Boschi Dott. Maurizio
Bottacchiari Dott. Renato Stefano
Botticelli Dott. Claudio
Brenna Dott. Franco
Buda Dott. Massimo
Cabiddu Dott. Mauro
Calapaj Dott. Massimo
Calderoli Dott. Stefano
Campo Dott.ssa Simonetta
Canonica Dott. Massimo
Cantatore Prof. Giuseppe
Capelli Dott. Matteo
Cardinali Dott. Filippo
Cardosi Carrara Dott. Fabrizio
Carmignani Dott. Enrico
Carratù Dott.ssa Paola
Carrieri Dott. Giuseppe
Cascone Dott. Andrea
Cassai Dott. Enrico
Castellucci Dott. Arnaldo
Castro Dott. Davide Fabio
Cavalli Dott. Giovanni
Cecchinato Dott. Luigi
Cerutti Prof. Antonio
Ciunci Dott. Renato Pasquale
Colla Dott. Marco
Conconi Dott. Marcello
Coraini Dott. Cristian
Cortellazzi Dott. Gianluca
Cotti Prof.ssa Elisabetta
Cozzani Dott.ssa Marina
D'Agostino Dott.ssa Alessandra
Daniele Dott. Lucio
Del Mastro Dott. Giulio
Dettori Dott.ssa Claudia
Di Ferrante Dott. Giancarlo
Di Giuseppe Dott. Italo
Donati Dott. Paolo
Dorigato Dott.ssa Alessandra
Fabbri Dott. Massimiliano
Fabiani Dott. Cristiano
Faitelli Dott.ssa Emanuela
Fassi Dott. Angelo
Favatà Dott. Massimo
Fermani Dott. Giorgio
Ferrari Dott. Paolo
Ferrini Dott. Francesco
Foce Dott. Edoardo
Forestali Dott. Marco
Fornara Dott. Roberto
Fortunato Prof. Leonzio
Franchi Dott.ssa Irene
Franco Dott. Vittorio
Fuschino Dott. Ciro
Gaffuri Dott. Stefano
Gagliani Prof. Massimo
Gallo Dott. Roberto
Gallottini Prof. Livio
Gambarini Prof. Gianluca
Generali Dott. Paolo
Gesi Dott. Andrea
Giacomelli Dott.ssa Grazia
Giovarruscio Dott. Massimo
Gnesutta Dott. Carlo
Gnoli Dott.ssa Rita
Gorni Dott. Fabio
Greco Dott.ssa Katia
Gullà Dott. Renato
Hazini Dott. Abdol Hamid
Iacono Dott. Francesco
Iandolo Dott. Alfredo
Ivaldi Dott. Luca
Kaitsas Prof. Vassilios
Kaitsas Dott. Roberto
Lamorgese Dott. Vincenzo
Lendini Dott. Mario
Maggiore Dott. Francesco
Malagnino Prof. Vito Antonio
Malagnino Dott. Giovanni Pietro
Malentacca Dott. Augusto
Malvano Dott. Mariano
Mancini Dott. Manuele
Mancini Dott. Mario
Mancini Dott. Roberto
Manfrini Dott.ssa Francesca
Mangani Prof. Francesco
Martignoni Dott. Marco
Mazzocco Dott. Alberto
Migliau Dott. Guido
Monza Dott. Daniele
Mori Dott. Massimo
Multari Dott. Giuseppe
Mura Dott. Giovanni
Natalini Dott. Daniele
Negro Dott. Alfonso Roberto
Olivi Dott. Giovanni
Ongaro Dott. Franco
Orsi Dott.ssa Maria Veronica
Padovan Dott. Piero
Palazzi Dott. Flavio
Palmeri Dott. Mario
Pansecchi Dott. Davide
Papaleoni Dott. Matteo
Pappalardo Dott. Alfio
Parente Dott. Bruno
Pasqualini Dott. Damiano
Piferi Dott. Marco
Pilotti Dott. Emilio
Pirani Dott.ssa Chiara
Pisacane Dott. Claudio
Polesel Prof. Andrea
Pollastro Dott. Giuseppe
Pongione Dott. Giancarlo
Pontoriero Dott.ssa Denise
Portulano Dott. Francesco
Pracella Dott. Pasquale
Preti Dott. Riccardo
Pulella Dott. Carmelo
Puttini Dott.ssa Monica
Raffaelli Dott. Renzo
Raia Dott. Roberto
Rapisarda Prof. Ernesto
Re Prof. Dino
Rengo Prof. Sandro
Riccitiello Prof. Francesco
Ricucci Dott. Domenico
Rieppi Dott. Alberto
Rigolone Dott. Mauro
Rizzoli Dott. Sergio
Roggero Dott. Emilio
Russo Dott. Ernesto
Santarcangelo Dott. Filippo Sergio
Sbardella Dott.ssa Maria Elvira
Sberna Dott.ssa Maria Teresa
Scagnoli Dott. Luigi
Schianchi Dott. Giovanni
Schirosa Dott. Pier Luigi
Serra Dott. Stefano
Simeone Prof. Michele
Smorto Dott.ssa Natalia
Sonaglia Dott. Angelo
Squeo Dott. Giuseppe
Storti Dott.ssa Paola
Strafella Dott. Roberto
Stuffer Dott. Franz
Taglioretti Dott. Vito
Taschieri Dott. Silvio
Tavernise Dott. Salvatore
Tiberi Dott. Claudio
Tocchio Dott. Carlo
Tonini Dott. Riccardo
Tosco Dott. Eugenio
Tripi Dott.ssa Valeria Romana
Uberti Dott.ssa Manuela
Uccioli Dott. Umberto
Vecchi Dott. Stefano
Venturi Dott. Giuseppe
Venturi Dott. Mauro
Venuti Dott. Luca
Veralli Dott. Eduardo
Vittoria Dott. Giorgio
Volpi Dott. Luca Fedele
Zaccheo Dott. Francesco
Zerbinati Dott. Massimo
Zilocchi Dott. Franco
Zuffetti Dott. PierFrancesco

SOCI AGGREGATI

Bugea Dott. Calogero
Cuppini Dott.ssa Elisa
D'Alessandro Dott. Alfonso
Giovinazzo Dott. Luca
Messina Dott. Giovanni
Milani Dott. Stefano
Paone Dott. Pasquale
Reggio Dott.ssa Lucia
Zaccheo Dott. Fabrizio

SOCI SCOMPARSI

Ricordiamo con affetto e gratitudine i Soci scomparsi:

Attanasio Dott. Salvatore
Socio Attivo
Castagnola Prof. Luigi
Socio Onorario
De Fazio Prof. Pietro
Socio Attivo
Dolci Prof. Giovanni
Socio Onorario
Duillo Dott. Sergio
Socio Onorario
Garberoglio Dott. Riccardo
Socio Onorario
Lavagnoli Dott. Giorgio
Socio Onorario
Pecchioni Prof. Augusto
Socio Onorario
Riitano Dott. Francesco
Socio Onorario
Spina Dott. Vincenzo
Socio Onorario
Zerosi Prof. Carlo
Socio Onorario

CONSIGLIO DIRETTIVO SIE BIENNIO 2017-2018

Past President
Bertani Dott. Pio

Presidente
Riccitiello Prof. Francesco

Presidente Eletto
Franco Dott. Vittorio

Vice Presidente
Sberna Dott.ssa Maria Teresa

Segretario
Fornara Dott. Roberto

Tesoriere
Cardinali Dott. Filippo

Coordinatore Culturale
Rigolone Dott. Mauro

Coordinatore della Comunicazione
Di Giuseppe Dott. Italo

Revisori dei Conti
Greco Dott.ssa Katia
Rieppi Dott. Alberto

COME DIVENTARE SOCIO ATTIVO / AGGREGATO

Scaricabile dal sito www.endodonzia.it

SOCIO AGGREGATO

Per avere lo status di Socio Aggregato si dovrà presentare la documentazione descritta nel sito www.endodonzia.it che sarà valutata dalla Commissione Accettazione Soci. La documentazione che verrà presentata dovrà mostrare con rigore, attraverso casi clinici, l'interessamento del candidato alla disciplina endodontica.
Un meccanismo a punti è stato introdotto per valutare l'ammissibilità del candidato allo "status" di Socio Aggregato: i punti saranno attribuiti in base al tipo di documentazione presentata. Possono accedere alla qualifica di Socio Aggregato tutti i Soci Ordinari della SIE, in regola con le quote associative degli ultimi TRE anni, che completino e forniscano la documentazione alla Segreteria Nazionale (Via Pietro Custodi 3, 20136 Milano) entro i termini che verranno indicati all'indirizzo web: www.endodonzia.it
La domanda dovrà essere firmata da un Socio Attivo il quale dovrà aver esaminato e approvato la documentazione. Quest'ultimo è responsabile della correttezza clinica e formale della documentazione presentata.

DOCUMENTAZIONE PER DIVENTARE SOCIO AGGREGATO

Qualsiasi Socio Ordinario, con i requisiti necessari, può presentare la documentazione per ottenere la qualifica di Socio Aggregato. Un meccanismo a punti è stato introdotto per valutare il candidato: un minimo di 80 punti è richiesto per divenire Socio Aggregato.
La documentazione clinica per ottenere la qualifica di Socio Aggregato dovrà presentare almeno sei casi, di cui non più di tre senza lesione visibile nella radiografia preoperatoria e non più di uno di Endodonzia Chirurgica Retrograda.
Nella domanda non potranno essere presentati casi la cui somma superi i 120 punti per la qualifica di Socio Aggregato.
L'aspirante Socio Aggregato potrà presentare la documentazione clinica in più volte, con un minimo di 40 punti per presentazione, in un arco massimo di cinque anni. Il mancato rinnovo della quota associativa, anche per un solo anno, annulla l'iter di presentazione dei casi.

SOCIO ATTIVO

Per avere lo status di Socio Attivo si dovrà presentare la documentazione descritta nel sito www.endodonzia.it che sarà valutata dalla Commissione Accettazione Soci. La documentazione che verrà presentata dovrà mostrare con rigore, attraverso documentazione scientifica e casi clinici, l'interessamento del candidato alla disciplina endodontica.
Un meccanismo a punti è stato introdotto per valutare l'ammissibilità del candidato allo "status" di Socio Attivo: i punti saranno attribuiti in base al tipo di documentazione clinica e scientifica presentata. Possono accedere alla qualifica di Socio Attivo tutti i Soci Ordinari della SIE, in regola con le quote associative degli ultimi TRE anni, che completino e forniscano la documentazione alla Segreteria Nazionale (Via Pietro Custodi 3, 20136 Milano) entro i termini che verranno indicati all'indirizzo web: www.endodonzia.it
La domanda di ammissione allo "status" di Socio Attivo rivolta al Presidente della SIE dovrà essere firmata da un Socio Attivo il quale dovrà aver esaminato e approvato la documentazione. Quest'ultimo è responsabile della correttezza clinica e formale della documentazione presentata.

DOCUMENTAZIONE PER DIVENTARE SOCIO ATTIVO

Qualsiasi Socio Ordinario, con i requisiti necessari, può presentare la documentazione per ottenere la qualifica di Socio Attivo. Il Socio Aggregato che volesse presentare la documentazione scientifica e clinica ad integrazione di quella clinica già approvata dalla CAS per lo status di socio Aggregato, potrà farlo già dall'anno successivo all'ottenimento della sua qualifica.
Un meccanismo a punti è stato introdotto per valutare il candidato a Socio Attivo. Un minimo di 200 punti è richiesto per divenire Socio Attivo.
Nella domanda non potranno essere presentati casi la cui somma superi i 240 punti per la qualifica di Socio Aggregato. La documentazione clinica per ottenere la qualifica di Socio Attivo dovrà presentare almeno sei casi, di cui non più di tre senza lesione visibile nella radiografia preoperatoria e non più di uno di Endodonzia Chirurgica Retrograda.
La documentazione scientifica non potrà presentare più di 2 articoli come coautore.

MODALITÀ DI DOCUMENTAZIONE DEI CASI CLINICI

Per avere i criteri e le modalità per la valutazione dei casi clinici idonei ad accedere alle qualifiche di Socio Aggregato e di Socio Attivo sono espressi nell'apposita sezione del Regolamento della Società Italiana di Endodonzia (SIE) all'indirizzo web: www.endodonzia.it

CRITERI DI VALUTAZIONE

I casi clinici verranno valutati nel loro complesso, coerentemente con gli scopi e fini della SIE, e devono essere presentati dai Candidati considerando non solo l'aspetto clinico, ma anche quello formale della documentazione presentata.
La documentazione scientifica verrà valutata considerando la classificazione ANVUR delle Riviste Scientifiche, i documenti scientifici dovranno essere tutti di pertinenza endodontica.

ADEMPIMENTI DEL CANDIDATO

La domanda di ammissione allo "status" di Socio Aggregato/Attivo, rivolta al Presidente della SIE, dovrà pervenire, insieme alla documentazione di seguito elencata, alla Segretaria della SIE con un anticipo di 20 giorni sulle date di riunione della CAS,

sufficiente per poter organizzare il materiale dei candidati. Le date di scadenza saranno rese note sul sito. La domanda dovrà essere firmata da un Socio Attivo il quale dovrà aver esaminato e approvato la documentazione. Quest'ultimo è responsabile della correttezza clinica e formale della documentazione presentata.

PRESENTAZIONE DEI CASI ALLA COMMISSIONE

La presenza del Candidato è obbligatoria durante la riunione della CAS; è altresì consigliabile la presenza del Socio presentatore.

LA COMMISSIONE ACCETTAZIONE SOCI

La CAS (Commissione Accettazione Soci) è formata 5 Membri di indiscussa esperienza clinica, 4 Soci Attivi con almeno 5 anni di anzianità in questo ruolo eletti ad ogni scadenza elettorale dall'Assemblea dei Soci Attivi ed Onorari e uno dei Past President della Società incaricato dal CD ad ogni riunione. Compito della CAS è quello di esaminare e valutare la documentazione presentata dagli aspiranti Soci Aggregati e Soci Attivi. Per rispetto del lavoro dei Candidati e per omogeneità di giudizio, in ogni riunione verranno valutati non più di 5 candidati a Socio Attivo. Resta libero, invece, il numero dei candidati a Socio Aggregato valutabili in una singola riunione della CAS. Il Consiglio Direttivo (CD) incaricando la Commissione Accettazione Soci (CAS) la rende responsabile dell' applicazione delle regole descritte nell' articolo 2 del regolamento. Il giudizio della CAS è insindacabile.

MEMBRI DELLA COMMISSIONE ACCETTAZIONE SOCI 2018

Past President della Società
Dott. Mario Mancini
Dott. Franco Ongaro
Dott. Andrea Polesel
Dott. Pier Luigi Schirosa

ONE CURVE, IL DNA DELL'ENDODONZIA

One Curve è lo strumento unico per la sagomatura canalare progettato per rispondere al meglio a tutte le esigenze cliniche.

L'innovativo trattamento termico del Nichel-Titanio rende lo strumento molto più flessibile e riduce significativamente il rischio di frattura, rendendo più semplice e sicura la preparazione del canale. È inoltre possibile precurvare lo strumento per permettere un accesso facilitato anche ai canali complessi e una migliore eliminazione delle interferenze.

Insieme al movimento di rotazione continua, la sezione variabile conferisce un'ottima efficacia di taglio così come una centratura perfetta nel canale e una buona messa in sicurezza della zona apicale.

L'utilizzo di un unico strumento monouso riduce inoltre il rischio di contaminazione crociata e agevola il lavoro del personale assistente grazie all'eliminazione delle procedure di sterilizzazione.

One Curve è uno strumento affidabile, sicuro e performante, come è tradizione degli strumenti NiTi Micro-Mega. Adatto sia agli utilizzatori più esperti, sia a chi si approccia per la prima volta allo strumento unico, One Curve garantisce un'elevata qualità della preparazione canalare, migliorando le possibilità di disinfezione e consentendo un'adeguata chiusura tridimensionale del canale.



DENTALICA
www.dentalica.com

DISTRIBUTORE ESCLUSIVO PER L'ITALIA
DENTALICA S.p.A. – Via Rimini, 22 – 20142 Milano
T 02.895981 – F 02.89504249 – info@dentalica.com – www.dentalica.com

NUMERO VERDE
800 70 71 72

I coni master di gutta-percha con tecnologia Conform Fit™ a conicità variabile.



La precisa corrispondenza di forme e dimensioni ottimizza il trattamento
Una delle maggiori sfide nell'otturazione canalare è ottenere un appropriato tug back apicale. Per raggiungere la lunghezza di lavoro, è necessario procedere all'eliminazione dei detriti ed all'irrigazione. Tuttavia, a dispetto di queste precauzioni, l'abilità a raggiungere la lunghezza di lavoro è fortemente influenzata dalla sagomatura del canale e dalla compatibilità tra la gutta-percha e la strumentazione usate. In caso contrario si può incorrere nella falsa sensazione di un'aderenza sicura.

Aderenza apicale superiore con il tug back desiderato
I coni master di guttaperca con tecnologia Conform Fit prodotti da Dentsply Sirona sono i primi ad avere una conicità variabile per adattarsi con precisione agli strumenti corrispondenti.
L'avanzata formulazione micronizzata utilizza una moderna tecnica di produzione per creare una forma e un adattamento con il 40% in più di conformità rispetto alla guttaperca tradizionale.
Il conseguente adattamento apicale migliorato permette di avvertire la precisa risposta di tug back a differenza della guttaperca tradizionale, che sembra adattarsi perfettamente, ma in realtà può non corrispondere all'esatta misura dell'apice.

Priva di lattice, può essere usata a temperature di lavoro inferiori
Studiata per ottenere un'otturazione completa, la formula micronizzata offre caratteristiche termiche avanzate che permettono una migliore fluidità ed il trasferimento del calore fino a 4 mm. Questa formulazione migliorata continua ad assicurare l'ottimale radiopacità e la facilità di ritrattamento.
Mentre la guttaperca tradizionale è realizzata in lattice di gomma naturale, quella prodotta con l' esclusiva formulazione di Dentsply Sirona è priva di lattice per una migliore sicurezza del paziente.

Una soluzione globale
I coni master di guttaperca con tecnologia Conform Fit™ fanno parte di una soluzione globale che facilita l'operatività grazie al preciso adattamento. Forniti di una pratica linguetta identificativa per una facile gestione, i coni master sono disponibili per i sistemi WaveOne Gold®, Protaper Gold® e Protaper Next®.

WaveOne® Gold

ProTaper Gold®

ProTaper Next®

Per saperne di più visita il sito www.dentsplysirona.com o contatta Simit Next al numero 0376.267811

THE DENTAL SOLUTIONS COMPANY™

Dentsply Sirona | Simit® NEXT Endodonzia & Conservativa

VDW®

Endo
Easy
Efficient

EDDY® è il sistema sonico d'irrigazione canalare sicuro, efficace e clinicamente testato.

Numerosi studi clinici e più di due anni di utilizzo nella pratica quotidiana hanno dimostrato che l'attivazione sonica dell'irrigante con la punta EDDY® della VDW deterge in modo sicuro ed efficace anche i canali radicolari più curvi.

La punta EDDY® per l'attivazione sonica dell'irrigante risolve i problemi dei sistemi ultrasonici e dell'irrigazione manuale. Realizzata in poliammide, effettua un movimento oscillatorio di elevata ampiezza nel canale radicolare generato dall'aria compressa ad alta frequenza, dai 5.000 ai 6.000 Hz. Questo movimento tridimensionale innesca la cavitazione e il microstreaming dei liquidi che rendono la detersione più efficiente anche nei canali laterali, nelle ramificazioni apicali e negli istmi.
La punta EDDY® in poliammide, inoltre, è più morbida della dentina e particolarmente delicata e flessibile, rispetta l'anatomia del canale ed evita il rischio di creare gradini o perforazioni.
Un ulteriore vantaggio di EDDY® consiste nel notevole risparmio di tempo - richiede solo un massimo di 30 secondi per intervallo durante la preparazione - e assicura una maggiore efficienza rispetto all'irrigazione manuale con cannule.

Studi clinici dimostrano il successo del trattamento a lungo termine

Diversi studi clinici (Neuhaus et al., Urban et al.) hanno confrontato le prestazioni di EDDY® rispetto agli altri metodi di irrigazione e hanno dimostrato che produce risultati eccezionali: rimuove il biofilm batterico nei canali con anatomie complesse tanto efficacemente quanto l'irrigazione ultrasonica passiva, risultando più delicata sulle pareti canalari grazie alla morbidezza e flessibilita della poliammide. Sia l'attivazione sonica che ultrasonica rafforzano le proprietà degli irriganti di dissoluzione del tessuto. Infine, è stato dimostrato che EDDY® rimuove depositi e detriti di idrossido di calcio in modo più efficace rispetto all'irrigazione manuale.
Essendo una punta monouso di dimensioni universali, EDDY® può essere facilmente ed efficacemente integrata nella pratica clinica quotidiana, grazie alla sua compatibilità con la maggior parte degli Airscaler disponibili sul mercato.

EDDY®

Movimento oscillante della punta in poliammide EDDY®

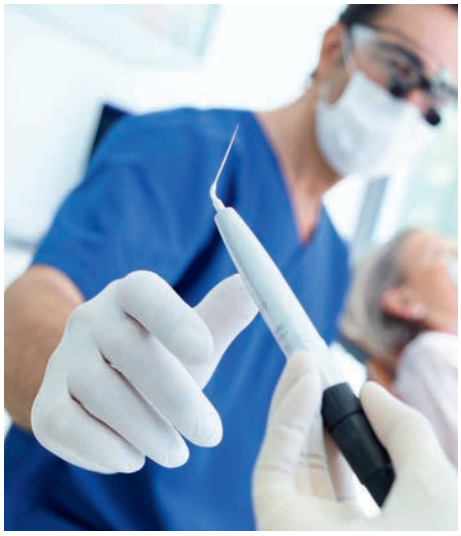

EDDY® su Airscaler sonico

Per maggiori informazioni consultare il sito web https://www.vdw-dental.com/en/products/detail/eddy/

Nuove tecniche in odontoiatria: l'ozonoterapia

L'ozonoterapia rientra nella categoria dei nuovi protocolli in odontoiatria e trova applicazione già in molti ambiti del settore odontoiatrico.

L'ozono medicale ha proprietà antibatteriche, antivirali, antifungine; in gas o disciolto nell'acqua rappresenta una tecnica dolce che ha proprietà analgesiche, antinfiammatorie, antibatteriche, antimicotiche, immunomodulanti.

Casi e studi clinici ne dimostrano l'efficacia in chirurgia orale e mucogengivale, in implantologia, in ortodonzia, nella terapia parodontale non chirurgica, nel trattamento di pazienti con protesi fisse e mobili, nell'igiene orale. Ed i benefici non sono da meno: l'ozono riduce il dolore postoperatorio e l'edema, velocizza la guarigione, abbassa la carica batterica.

A dosaggi e formulazioni predeterminati l'ozono è completamente innocuo, inodore, insapore e assolutamente privo di effetti collaterali.

Benché gli ambiti dove ha fin'ora trovato maggiore sviluppo siano la chirurgia orale, il post operatorio e la parodontologia, la compravata azione di abbattimento della carica batterica ne promette **interessanti applicazioni in endodonzia**. Alcuni lavori comparativi, sia in vitro che in vivo*, evidenziano che l'ozono è un valido ausilio, da solo o in aggiunta a soluzioni più tradizionali, per una **efficace disinfezione del canale radicolare**.

Due le formulazioni ed i dispositivi proposti da Sweden & Martina: **OzoneDta**, emette ozono in forma gassosa ed è particolarmente indicato per i trattamenti in aree poco estese; è programmato con concentrazioni di ozono e tempi predeterminati e corredato con sonde di vetro di varie tipologie per trattamenti orali in tutta sicurezza. **Aquolab**, l'irrigatore orale a base di ozono disciolto nell'acqua, è particolarmente indicato per i trattamenti più soft, in aree estese e nel mantenimento.

** Kist, Kollmuss M, Jung J, Hickel R, Huth KC,Comparison of ozone gas and sodium hypoclorite/chlorhexidine two-visit disinfection protocols in treating apical periodontitis: a randomized controlled clinical trial, Clinical oral Investig. 2017 May*
Noagales, Ferreira, Montemor, Rodriguez, Lage-Marques, Antoniazzi, Ozone Therapy as an adjuvant for endodontic protocols: microbilogical ex vivo study and citotoxicity analyses, J Appl Oral Sci 2016)
Halbauer, Prskalo, Janković, Tarle, Pandurić, Lalenić, Efficacy of ozone on microorganisms in the tooth root canal, Coll Antropol 2013 Mar

Ritrattamenti endodontici con Komet ReStart

RIMOZIONE RAPIDA UTILIZZANDO SOLO 2 STRUMENTI

Il trattamento endodontico primario non sempre porta ad un esito positivo. Nei casi di fallimento del trattamento primario, una delle possibili opzioni terapeutiche è il ritrattamento endodontico che ha la finalità di migliorare la terapia iniziale, sagomando, detergendo e otturando le porzioni non trattate in prima battuta. Il ritrattamento, che ha una percentuale di successo che si attesta attorno all'80%, prevede la rimozione del materiale da otturazione canalare. Una volta rimossi tutti gli ostacoli coronali, il primo passaggio è ridisegnare la cavità d'accesso; questo aiuterà a reperire tutti gli imbocchi canalari rendendo più agevole l'utilizzo degli strumenti endodontici. Dopo aver reperito tutti gli imbocchi canalari, si inizierà a rimuovere il materiale da otturazione canalare esistente che può essere:

Guttaperca
La guttaperca è il materiale da otturazione canalare più utilizzato dai clinici, il metodo migliore per rimuoverla è sfruttare l'azione meccanica degli strumenti rotanti in Ni-Ti. Quando la sola azione meccanica non riesce a rimuovere tutta la guttaperca ci si può avvalere di solventi.

Cementi canalari
I cementi endodontici sono ancora utilizzati da soli o in associazione con la guttaperca. La loro rimozione si esegue con lo stesso metodo usato per la guttaperca. Generalmente i cementi sono più teneri rispetto alla guttaperca, quindi la loro rimozione è meno indaginosa.

Otturatori con carrier
Gli otturatori con carrier possono creare qualche problema in più rispetto alla guttaperca dal punto di vista della rimozione, dato che il carrier è tradizionalmente costituito da un polimero biocompatibile più duro e non sensibile ai solventi. Esiste però una scanalatura disegnata lungo il carrier che, se ingaggiata da uno strumento, permette di sfilarlo dalla guttaperca, rendendo la procedura più rapida. Il metodo più indicato per rimuovere un otturatore con carrier è l'utilizzo di strumenti in Ni-Ti specifici.

ENDO RE-START KOMET ha sviluppato per la succitata casistica dei ritrattamenti ortogradi gli Endo ReStart, un sistema di strumenti rotanti in Nichel-Titanio costituito di soli 2 files:
1. Opener di conicità 010 e diametro in punta 030;
2. File di conicità 05 e diametro in punta 025, disponibile nelle lunghezze di 21mm e 25mm. L'Opener Endo ReStart lavora in modo efficace e sicuro nel primo tratto coronale del canale, mentre i Files Endo ReStart lavorano nel terzo medio e apicale, asportando Guttaperca e Cemento residui presenti all'interno dei canali radicolari. Entrambi gli strumenti possiedono una particolare geometria delle lame taglienti, pensata per garantire sempre un ottimo controllo dello strumento.

La punta dell'Opener Endo ReStart è parzialmente attiva, per entrare facilmente nel materiale da otturazione e preparare la strada al File Endo ReStart. La punta del File Endo ReStart è di tipo raschiante e il passo aumentato delle spire lungo la parte lavorante dello strumento aumenta l'efficienza e l'asportazione verso coronale del materiale. Una volta esaurita la fase della rimozione dei vecchi materiali di otturazione, l'operatore dovrà procedere al ritrattamento propriamente detto, utilizzando la tecnica di sagomatura più appropriata, come ad esempio l'F06 SkyTaper.

Dr Giuseppe Squeo

TriAuto ZX2

Massima precisione e sicurezza per il canale radicolare.

MORITA

Il nuovo sistema endodontico aumenta l'efficienza e la sicurezza.

In Endodonzia la necessità di lavorare su strutture minuscole, in spazi molto limitati ed anche le particolari situazioni Anatomiche coinvolte pongono richieste straordinarie alle competenze del dentista, richiedendo sforzi speciali per garantire la sicurezza dei pazienti. Pioniere nel campo della Endodonzias, Morita ha sempre offerto soluzioni di alta qualità per i dentisti per molti decenni, puntando all'efficienza, comfort e sicurezza. Un esempio di questo è il nuovo **TriAuto ZX2**, un motore endo cordless, con localizzatore apicale integrato che ora include una funzionalità innovativa per una maggiore sicurezza: la funzione ottimale glide path (OGP) mira a procedure ancora più precise all'interno del canale radicolare e guida i dentisti e i pazienti al successo del trattamento, "seguendo percorsi sicuri.

L'Endodonzia ha svolto un ruolo fondamentale in più di 100 anni di storia di Morita. Già nel 1991, è stato introdotto il primo Apex Locator del mondo che ha utilizzato le misure di impedenza, il Root ZX. Il passo successivo in questo sviluppo è stato il sistema modulare DentaPort ZX che grazie alla possibilità di integrazione con il Motore Endo, ha facilitato la preparazione del canale radicolare.

Con il ZX2 TriAuto, Morita ora presenta un nuovo motore endo con localizzatore apicale integrato. Il successore del TriAuto ZX, è l'unico sistema endodontico sul mercato che combina entrambe le funzioni in un unico manipolo.

Un **display LCD** Mostra misure precise e fornisce un feedback perfetto dall'interno del canale radicolare. Oltre a questo), il ZX2 TriAuto presenta due caratteristiche di sicurezza innovative -quali l'Optimum Torque reverse (OTR) e l'Optimum Glide Path (OGP)

La **funzione OTR** consente di cambiare la direzione di rotazione del file quando viene superato il livello massimo di coppia. Combinata con la piccolissima rotazione angolare, il rischio di rotture di file e microfessure è minimizzato. Inoltre, il sistema conserva il canale radicolare originale e assicura la rimozione affidabile dei detriti.

La nuova **funzione OGP** semplifica la creazione del percorso canalare, rendendolo veloce e sicuro, e automatico. In più, il motore può realizzare la pervietà apicale usando una lima # 20 o più piccola. Possono essere utilizzati Niti file di dimensioni # 20 o più piccoli e file in acciaio dalla dimensione # 15. La funzione OGP in combinazione con quella OTR permette allo strumento endodontico di essere portato alla lunghezza di lavoro più velocemente di quanto precedentemente possibile, senza blocco o formazione di scalini. Inoltre, TriAuto ZX2 conserva la struttura del dente naturale e rende il trattamento ancora più economico a causa di un ridotto consumo di file.

Il display LCD mostra tutti i parametri importanti a colpo d'occhio, fornendo il controllo completo durante il trattamento.

Un'altra caratteristica chiave del sistema endodontico è la **piccola testina** ed il **basso peso** (140 g), che permettono una migliore vista del campo di trattamento. Il fatto di essere **cordless** migliora significativamente la flessibilità di trattamento e ottimizza il flusso di lavoro. Il funzionamento semplice ed intuitivo e le funzioni automatizzate garantiscono risultati affidabili in ogni momento. La maggiore efficienza riduce anche la durata del trattamento, fornendo tempo supplementare per il risciacquo e la disinfezione del canale radicolare.

9-11 NOVEMBRE 2017, BOLOGNA

35° Congresso Nazionale SIE "Endodonzia tra fondamenti e innovazioni"

Palazzo della Cultura e dei Congressi - Piazza della Costituzione 4/A - Bologna

Resoconto a cura dott. Italo di Giuseppe, Coordinatore della Comunicazione SIE

Nelle giornate di Giovedì, Venerdì e Sabato 9-10-11 Novembre, presso il Palazzo della Cultura e dei Congressi di Bologna, si è svolto il 35° Congresso Nazionale della Società Italiana di Endodonzia SIE, sul tema: "Endodonzia tra fondamenti e innovazioni".

Il Congresso è stato accreditato ECM da CIC Provider e patrocinato dalle Università degli Studi di Parma, Ferrara, Modena e Reggio Emilia e dall'Università degli Studi di Bologna – Alma Mater Studiorum, dall'OMCeO Bologna e da FNOMCeO Federazione Nazionale degli Ordini dei Medici Chirurghi e degli Odontoiatri, da ANDI Nazionale, AIO Nazionale, dal Collegio dei Docenti Universitari di Discipline Odontostomatologiche e dal Comune di Bologna.

L'evento, supportato da ben 24 Aziende Sponsor, ha catalizzato l'attenzione di oltre mille partecipanti tra Odontoiatri e studenti, che, per tre giorni, hanno popolato la splendida struttura del Palazzo della Cultura e dei Congressi, già sede del Congresso Nazionale organizzato nel 2015.

I lavori hanno avuto inizio Giovedì mattina con l'ultimo appuntamento del **Corso di formazione teorico-pratico in Endodonzia, dal titolo: "Aspetti endodontici e parodontali del dente compromesso";** molti dei 106 iscritti ai vari corsi regionali con sede a Bologna, Bolzano, Brescia e Roma hanno potuto seguire, all'interno della Sala Europa, le suggestive relazioni messe a punto per loro dai Dottori Cristian Coraini e Claudio Pisacane. Al termine dei lavori si è svolta la cerimonia di consegna degli attestati, con foto di rito, alla presenza del presidente SIE Prof. Francesco Riccitiello e del segretario SIE Dott. Roberto Fornara.

Nel pomeriggio dello stesso giorno, davanti a ben 518 partecipanti, si è svolto il **Corso Pre-Congresso dal titolo: "L'ENDODONZIA CHIRURGICA",** durante il quale si sono alternati 3 relatori, che hanno deliziato con le loro immagini cliniche, i numerosi intervenuti: ha iniziato il Prof. Damiano Pasqualini, seguito dal Prof. Elio Berutti e, per ultimo, dal Dott. Mauro Rigolone.

IL PROF. DAMIANO PASQUALINI DURANTE IL CORSO PRE-CONGRESSO

IL CENTRO CONGRESSI

I lavori del 35° CONGRESSO Nazionale (Venerdì e Sabato) si sono svolti contemporaneamente su 2 sale: la splendida **Sala Europa e la Sala Italia,** riservata, quest'ultima, alle fasi finali dei premi *Riccardo Garberoglio* (Venerdì mattina), *Giorgio Lavagnoli* (Venerdì pomeriggio) e *Francesco Riitano* (Sabato mattina).

Nella sala Europa, Venerdì 10 mattina, dopo il consueto saluto delle Autorità, il numerosissimo pubblico ha potuto seguire le prime due sessioni, all'interno delle quali hanno brillantemente relazionato il **Prof. Francesco Riccitiello, il Dott. Domenico Ricucci e il Prof. Carlo Prati** (Interazione tra organo pulpare e materiali), e in seguito, il **Dott. Lucio Daniele, la Dott.ssa Denise Pontoriero e il Prof. Vasilios Kaitsas insieme con il Dott. Mario Mancini** (L'outcome in Endodonzia).

Dopo la pausa, dalle 14.00 alle 15.00, presso il foyer Italia, si è svolta un'interessante **Poster Session** e, sempre in sala Europa, sponsorizzate da Dentalica Micromega e Dentsply Sirona, si sono tenute **2 seguitissime Master Clinician Session** che hanno visto protagonisti, anche di una dimostrazione live, i Professori Livio Gallottini e Ghassan Yared.

A conclusione della prima giornata di lavori, dalle 17.00 alle 19.00, presso l'ergonomica area espositiva, con grandissimo successo di pubblico, sono andate in scena ben **14 Tavole Cliniche**. La formula delle tavole cliniche è sempre più apprezzata dai congressisti, che riescono costruttivamente ad interagire con il relatore, contestualmente all'esposizione della materia trattata.

VITA SOCIETARIA

Anche quest'anno, inoltre, diverse **Tavole Cliniche Sponsorizzate** da Dentsply Sirona, Simit Dental, J. Morita Europe GMBH, Komet Italia, Novaxa/Acteon, Dentalica/Micromega, che si sono tenute nelle giornate di Venerdì e Sabato, sempre presso l'area espositiva, hanno arricchito il paniere dell'offerta culturale a disposizione dei numerosissimi intervenuti.

La **Cena Sociale** del Venerdì sera ha concluso una giornata di intensi lavori nel luminosissimo ed elegantissimo "La Porta Restaurant" dove è stato dato il benvenuto **tra i Soci Attivi** ai dottori **Irene Franchi, Francesco Iacono, Chiara Pirani** e tra i **Soci Aggregati a Calogero Bugea** e a **Lucia Reggio.**

I lavori del Sabato mattina, presso la **Sala Europa**, hanno visto lo svolgimento delle ultime due sessioni, nelle quali una platea ancora molto gremita di partecipanti hanno potuto apprezzare le suggestive relazioni dei **Dott. Alberto Rieppi, Dott. Roberto Fornara e Dott. Fabio Gorni insieme con il Dott. Luigi Scagnoli** (La gestione dei casi complessi) e di seguito quelle dei **Prof.ri Francesco Mangani, Enrico Gherlone e Marco Ferrari** (Il restauro post-endodontico).

Infine, come ultimo atto di un Congresso ricco di contenuti, si è proceduto all'**assegnazione dei premi Riccardo Garberoglio, Giorgio Lavagnoli, Francesco Riitano**, e a quella per il miglior **Poster**:

- il *Premio Riccardo Garberoglio* è andato al lavoro dal titolo:

"Le Human Periapical Cysts-Mesenchymal Stem Cells coltivate con siero umano allogenico costituiscono un costrutto "clinical-grade" alternativo al siero fetale bovino ed indicato nella rigenerazione dei tessuti endo-parodontali"

degli autori: Marco Tatullo*, Massimo Marrelli, Francesca Palmieri, Carlo Rengo, Francesco Paduano, Gianrico Spagnuolo.

- *il Premio Giorgio Lavagnoli* è stato assegnato alla relazione dal titolo:

"Autotrapianto autologo. Qual è il limite delle nostre possibilità conservative?"

degli autori: Stefano Milani*, Paolo Generali.

- *Premio Francesco Riitano* è andato alla relazione dal titolo:

"Impatto di una nuova cinematica sulla resistenza in fatica ciclica di strumenti reciprocanti"

degli autori: Francesco Iacono*, Chiara Pirani, Luigi Generali (UNIMORE), Carlo Prati.

- *Premio Sessione Poster* è stato consegnato alla relazione dal titolo:

"Ritrattamento di denti trattati endodonticamente e ricostruiti con perni in fibra: tecniche di rimozione, vantaggi e limiti"

degli autori: Lorenza Capriotti*, Katia Greco, Gaetano Paolone, Maria Teresa Sberna, Giuseppe Cantatore.

La lunga maratona di tre giorni si concludeva con l'intervento del Presidente Prof. Francesco Riccitiello, che ad un pubblico rimasto incredibilmente numeroso fino alla fine, ha dato i sentiti ringraziamenti della SIE ed un arrivederci al San Raffaele di Milano, in occasione del III Congresso Internazionale, previsto l'8, 9 e 10 Novembre 2018, e che avrà per titolo:" Endodontics: clinical solutions"

IL PROF. ELIO BERUTTI DURANTE IL CORSO PRE-CONGRESSO

IL DOTT. MAURO RIGOLONE DURANTE IL CORSO PRE-CONGRESSO

VITA SOCIETARIA

I RELATORI DEL CORSO PRE-CONGRESSO CON IL PRESIDENTE SIE

L'ASSEMBLEA DEI SOCI

L'ASSEMBLEA DEI SOCI

LA CERIMONIA DI APERTURA LAVORI E SALUTO AUTORITÀ

IL PRESIDENTE SIE PROF. FRANCESCO RICCITIELLO E I PRESIDENTI DI SESSIONE DR MARIA TERESA SBERNA E PROF. SANDRO RENGO

LA PLATEA DELL'EUROPA AUDITORIUM DI BOLOGNA

LA PLATEA DELL'EUROPA AUDITORIUM DI BOLOGNA

LA SESSIONE PREMI SIE

VITA SOCIETARIA

LA SESSIONE PREMI SIE

LA COMMISSIONE CULTURALE E I RELATORI DEL PREMIO LAVAGNOLI

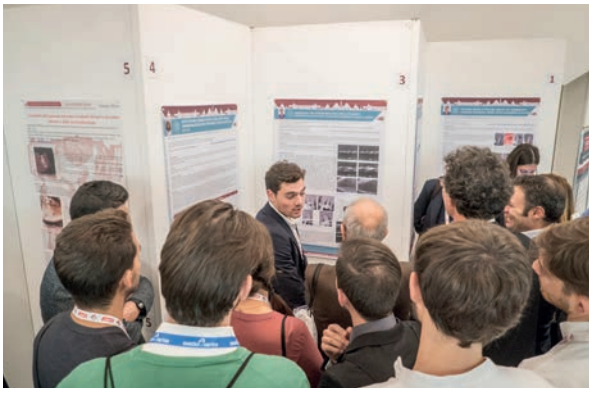

LA SESSIONE POSTER

LA SESSIONE POSTER

MASTER CLINICIAN SESSION SPONSORIZZATA

MASTER CLINICIAN SESSION SPONSORIZZATA

TAVOLE CLINICHE SIE POMERIDIANE

TAVOLE CLINICHE SIE POMERIDIANE

VITA SOCIETARIA

TAVOLE CLINICHE SPONSORIZZATE

TAVOLE CLINICHE SPONSORIZZATE

TAVOLE CLINICHE SPONSORIZZATE

TAVOLE CLINICHE SPONSORIZZATE

LA CENA SOCIALE SIE

I NUOVI SOCI ATTIVI, IL PAST PRESIDENT DR PIO BERTANI E I SOCI DELLA SERE

DR GIANFRANCO VIGNOLETTI SOCIO ONORARIO

PROF GIACOMO CAVALLERI SOCIO ONORARIO

VITA SOCIETARIA

SINTESI DEL SEMINARIO ENDODONTICO REGIONALE SARDO SES

Valutazione clinica e terapeutica dei casi complessi in campo endodontico

24 febbraio 2018 - Dott.ssa Claudia Dettori

Il 24 febbraio 2018 nella Sala Congressi della Facoltà di Medicina dell'Università di Cagliari si è svolto il seminario della Sezione Endodontica Sarda (SES). I partecipanti, tra i quali numerosi giovani, sia studenti che neo-laureati, e professionisti affermati, hanno manifestato grande interesse per i temi trattati nell'arco dell'intera giornata, decretando il successo della nostra manifestazione regionale.

I relatori hanno sviluppato in maniera egregia ed esaustiva gli argomenti proposti, interagendo attivamente con un pubblico attento e determinato nell'apprendere gli attuali orientamenti nel trattamento endodontico dei casi complessi, con un'attenzione particolare per il paziente compromesso dal punto di vista sistemico.

Il Dr. Filippo Cardinali ha dato inizio ai lavori della mattina affrontando con competenza clinica e scientifica una tematica importante, quella relativa alla gestione delle complessità riscontrabili nelle fasi iniziali di un trattamento endodontico.

La sottoscritta ha preso in esame le problematiche correlate al trattamento del paziente compromesso dal punto di vista sistemico e la sempre più crescente necessità di disporre di protocolli operativi adeguati.

La mattina si è conclusa con la relazione sulla valutazione clinica e le strategie operative nei casi complessi, durante la quale il Dr. Stefano Serra ha fornito importanti spunti di riflessione circa la pianificazione clinica e terapeutica in campo endodontico, Nella prima parte della sessione pomeridiana i Dr. Andrea Deidda, Paolo Montisci, Corrado Sergi e Nicola Peddis hanno proceduto alla presentazione di una serie di casi clinici trattati con differenti sistemi NiTi e nei quali la complessità delle procedure non era addebitabile esclusivamente alle difficoltà anatomiche dell'elemento trattato, ma, il più delle volte, alle problematiche sistemiche dell'organismo ospite.

In un gran numero di casi, la messa a punto di un piano di trattamento delle patologie del distretto oro-dentale non può prescindere da un approccio multidisciplinare. Ciò allo scopo di disporre di tutti gli strumenti necessari ad un inquadramento delle stesse da un punto di vista diagnostico e, quindi, terapeutico. Nell'ambito di questa tematica i colleghi specialisti in Otorinolaringoiatria e, più precisamente, il Prof. Roberto Puxeddu ha affrontato in maniera chiara ed esaustiva le problematiche relative alle implicazioni ORL nella gestione del paziente endodontico.

Il Dr. Mauro Cabiddu ha preso in esame l'otturazione endodontica e l'evoluzione del sistema carrier-based e ha concluso la giornata coinvolgendo i partecipanti, ancora numerosi, in una discussione su un'ampia casistica clinica. Ringrazio tutti coloro che hanno contribuito al successo dell'evento.

Grazie a tutti i Relatori.

Un grazie di cuore ad Elisabetta Cotti, parte attiva nella gestione del seminario e indispensabile per le sue competenze organizzative e scientifiche.

Grazie alla SIE e, in particolare, a Cristian Coraini, Roberto Fornara, Mauro Rigolone e tutti i segretari regionali che mi hanno sostenuto e incoraggiato.

Grazie agli sponsor e all'AIO. Grazie a Sonia Rojas e Mara Pinna per il loro prezioso aiuto nelle attività di segreteria.

Infine un ringraziamento sincero a Gaia che mi ha supportato e sopportato durante tutte le fasi organizzative pre e post-congressuali.

VITA SOCIETARIA

IL DR CARDINALI RELATORE DELL'EVENTO CON LA COMMISSIONE DI PRESIDENZA

I DR SERGI, DEIDDA E PEDDIS RELATORI OSPITI DELL'EVENTO

I DR SERGI, DEIDDA E PEDDIS RELATORI OSPITI DELL'EVENTO

IL DR PUXEDDU RELATORE OSPITE DELL'EVENTO

VITA SOCIETARIA

SINTESI DELLA GIORNATA ENDODONTICA REGIONALE MARCHIGIANA/ABRUZZESE SME/SAE

Endodonzia: tecniche di base e gestione dei casi complessi

3 marzo 2018 - Dott. Stefano Vecchi e Dott. Lucio Daniele

Il giorno 03 marzo 2018 si è svolta presso l'Università Politecnica delle Marche, nella Facoltà di Medicina e Chirurgia, la Giornata Endodontica Marchigiana/Abruzzese che ha visto per la prima volta le due regioni adriatiche unite per un bel confronto sull'endodonzia.

Una giornata all'insegna della condivisione che ha visto l'affluenza di 140 colleghi da Marche, Abruzzo e Umbria. Hanno partecipato studenti, giovani odontoiatri e anche operatori più esperti, questo a rimarcare l'interesse di tutti per questo tipo di disciplina.

La giornata, dal titolo "Endodonzia: tecniche di base e gestione dei casi complessi", si è svolta nella prestigiosa cornice dell'Auditorium Montessori. Il tema proposto è stato magistralmente trattato dai dottori Vittorio Franco, Roberto Fornara, Roberto Mancini ed Eugenio Tosco con tre relazioni al mattino, dove sono state discusse le complicanze endodontiche senza perdere di vista la diagnosi ed il relativo piano di trattamento.

Nel pomeriggio si è poi proseguito con 5 tavole cliniche tenute dai dottori Eugenio Tosco (con una relazione del Dott. Mario Mancini che non ha potuto partecipare in quanto influenzato), Filippo Cardinali, Marco Forestali, Daniele Natalini e Lucio Daniele che hanno riscosso un grande successo, stimolando interesse e condivisione da parte di tutti i colleghi. Ci auguriamo che tutto ciò sia servito a confrontarsi e ad attingere informazioni utili per la pratica clinica quotidiana.

Durante la mattinata, in un'aula adiacente a quella principale si è tenuto anche un "corso satellite" gratuito dedicato alle Assistenti, in quanto l'evoluzione della moderna endodonzia, il cambiamento dello strumentario, delle metodiche operative e l'utilizzo dei sistemi ingrandenti, sono tematiche che non coinvolgono solo il medico bensì tutto il team odontoiatrico.

Quello che ci piace sottolineare è quanto sia stato gratificante condividere tutta l'organizzazione dell'evento con gli altri soci attivi regionali, formando un'unica ed affiatata squadra. Per dirla citando Gaber "Sarei certo di cambiare la mia vita, se potessi cominciare a dire noi."

È stato bello accogliere il Presidente Eletto Dott. Vittorio Franco e il Segretario Nazionale Dott. Roberto Fornara che, a loro volta, hanno rimarcato il loro impegno per una SIE unita e vicina a tutti i colleghi.

Un ringraziamento particolare va ai numerosi Sponsor ed Espositori che ci hanno sostenuto ed hanno fatto sentire la loro vicinanza alle nostre sezioni regionali.

Un'ulteriore riconoscenza la dobbiamo alle aziende locali che con generosità ci hanno consentito gratuitamente di omaggiare tutti i relatori con prodotti tipici artigianali marchigiani ed abruzzesi, fiore all'occhiello delle nostre regioni.

I SEGRETARI REGIONALI SME DR STEFANO VECCHI E SAE DR LUCIO DANIELE

IL SEGRETARIO SME, I PRESIDENTI DI SESSIONE E IL DR ROBERTO FORNARA RELATORE

VITA SOCIETARIA

TAVOLA CLINICA SPONSORIZZATA

TAVOLA CLINICA SIE POMERIDIANA

IL SEGRETARIO REGIONALE SME E IL DR FILIPPO CARDINALI

VITA SOCIETARIA

SINTESI DELLA GIORNATA ENDODONTICA REGIONALE LAZIALE SER

Casi Complessi: diagnosi, terapie a confronto e relativi limiti

24 marzo 2018 - Dott.ssa Alessandra D'Agostino

Il 24 marzo 2018 si è svolta la Giornata Regionale Endodontica SER, presso la facoltà di odontoiatria e protesi dentaria "La Sapienza" di Roma. L'affluenza all'evento è stata al disopra delle aspettative, circa 140 colleghi con gran sorpresa provenienti anche dalle regioni Campania e Molise. La giornata è stata aperta dalle autorità: Dott. Migliano Presidente AIO, Dott.ssa Santaniello Presidente ANDI e Dott. Pollifrone presidente CAO, i quali hanno elogiato la SIE come una delle più prestigiose e attive in termini congressuali e di organizzazione eventi ed hanno ringraziato per aver chiesto loro il patrocinio. L'argomento della Giornata: "Casi Complessi: diagnosi, terapie a confronto e relativi limiti" è stato trattato brillantemente da esperti Relatori di chiara fama Nazionale ed Internazionale. Nella mattinata si sono susseguiti il Prof. Gambarini, il Dott. Kaitsas, il Dott. Schianchi, il Dott. Uccioli, il Dott. Di Giuseppe, il Prof. Cantatore e il Dott. Malentacca. Durante la pausa lunch i partecipanti hanno avuto modo di assistere a 4 tavole cliniche sponsorizzate, alcune con parte pratica. Nel pomeriggio i lavori sono ripresi con il Prof. Bossù e il Dott. Di Giorgio, il Dott. Mancini, il Dott. Scagnoli ed infine un ospite che esula dall'Endodonzia ma comunque attinente all'odontoiatria, un consulente esperto in comunicazione che ha aggiornato la platea sui nuovi orientamenti degli studi odontoiatrici. Un ringraziamento particolare va sicuramente ai Main e Gold Sponsor Annuali della SIE che hanno supportato la Giornata ma soprattutto agli Sponsor locali che hanno creduto nel nostro evento. Personalmente sono stata molto soddisfatta della riuscita dell'Evento e per la numerosa affluenza: vedere colleghi che a pomeriggio inoltrato ancora si dimostravano curiosi e ben disposti ad ascoltare i nostri Relatori, mi ha confermato le ottime scelte fatte per il Programma Scientifico e sono stata ancor più gratificata quando nei giorni successivi, ho ricevuto messaggi di complimenti per la qualità degli argomenti trattati e di ringraziamento da parte di colleghi e sponsor locali.

IL SALUTO DELLE AUTORITÀ

LA PLATEA

VITA SOCIETARIA

TAVOLA CLINICA SPONSORIZZATA

AREA EXPO

TAVOLA CLINICA SPONSORIZZATA

VITA SOCIETARIA

SINTESI DELLA GIORNATA ENDODONTICA REGIONALE PIEMONTESE SPE

Endodonzia a 360°: problemi, errori e soluzioni multidisciplinari

7 aprile 2018 - Dott. Davide Fabio Castro

La Giornata Endodontica Regionale SPE 2018 si è svolta sabato 7 Aprile presso la Dental School del Lingotto a Torino.

Il prof. Stefano Carossa, direttore della Dental School, il Dr. Virginio Bobba, Presidente Andi Torino ed il Dr. Giulio Del Mastro, Presidente Aio Torino hanno presenziato all'evento sul palco delle autorità. Il Segretario Regionale della SIE, Dr. Davide Castro, ha focalizzato l'evento sull'approccio clinico multidisciplinare con un confronto diretto tra l'Endodonzia e le altre specializzazioni. Oltre ai numerosi sponsor a supporto della manifestazione si è potuta constatare un'ottima affluenza con una partecipazione di 140 iscritti, prevalentemente dal Piemonte e dalla Lombardia. L'Aula Magna era gremita di odontoiatri giovani e meno giovani che hanno dimostrato grande interesse per gli argomenti trattati interagendo sovente con i Relatori.

Durante il light lunch anche le tavole cliniche sponsorizzate da Dentsply-Sirona, Simit Next e Sweden & Martina sono state testimoni di un'affluente partecipazione.

Nel pomeriggio la relazione finale sui contenziosi medico legali ha suscitato un interessante dibattito ponendo le basi per un ulteriore approfondimento futuro.

La giornata congressuale ha dimostrato un alto livello scientifico creando una grande occasione di confronto tra differenti generazioni alla luce di protocolli clinici sempre più affidabili e predicibili.

IL DR MARIO ALOVISI DURANTE LA RELAZIONE

IL SEGRETARIO SPE DR DAVIDE CASTRO E IL RELATORE OSPITE DR WALTER STABLUM

VITA SOCIETARIA

I DOTTORI PAOLA FRANCO E FABRIZIO SANNA CON IL SEGRETARIO SPE

IL SEGRETARIO SPE IL DR MARIO LENDINI E IL DR GIANLUCA ROGGERO

LA PLATEA

TAVOLA CLINICA SPONSORIZZATA

TAVOLA CLINICA SPONSORIZZATA

VITA SOCIETARIA

SINTESI DEL SEMINARIO ENDODONTICO REGIONALE TRIVENETO STE

Attualità in Endodonzia

21 aprile 2018 - Dott. Alberto Mazzocco

Si è concluso il seminario della sezione triveneta della Società di Endodonzia, a Trieste. L'incontro, organizzato dal segretario regionale, Dott. Alberto Mazzocco, è stato proposto con un inusuale format: teoria e pratica in diretta. Nella prima parte, più tradizionale, il Dott. Antonino Bonaccorso, socio attivo di Merano, e il suo parodontologo, Dott. Paolo Ghensi hanno discusso con grande maestria il difficile argomento delle lesioni endoparodontali, abbinando alla letteratura, un'ottima clinica a supporto dei percorsi diagnostici terapeutici proposti. La seconda parte è stata condotta dal prof. Daniele Angerame, insieme al suo gruppo di lavoro, dedicata al topic caldo del momento, i materiali bioceramici, in cui sono state date le informazioni necessarie per iniziare ad implementare nelle clinica quotidiana dei materiali che stanno dimostrando risultati interessanti. La terza parte ha visto, per la prima volta nella sezione regionale, 5 master clinician, in cui i soci attivi hanno mostrato in diretta, sotto microscopio, trattando endodonticamente un dente estratto, il proprio modo di lavorare quotidiano. Il live è iniziato con il Dott. Alberto Mazzocco, che ha preparato prima un simulatore in resina, e poi un dente estratto con sistematica mtwo e otturazione canalare mediante tecnica dell'onda continua, seguito dal Dott. Alberto Rieppi che ha trattato un dente estratto con Hyflex e Thermafil. Dopo il pranzo, il live è continuato, con il Dott. Franco Ongaro con protaper next e bioroot rcs, per finire con il Dott. Marco Colla e il prof. Angerame che hanno preparato due denti estratti con strumentazione reciprocante, waveone gold e reciproc rispettivamente, chiusi con compattazione verticale classica. Grande successo nostantante qualche deluso tra il pubblico, che sperava in qualche strumento canalare rotto in diretta…!

LA PLATEA

IL SEGRETARIO STE DR ALBERTO MAZZOCCO DURANTE LA MASTER CLINICIAN SESSION

VITA SOCIETARIA

IL DR ALBERTO RIEPPI DURANTE LA MASTER CLINICIAN SESSION

IL DR FRANCO ONGARO DURANTE LA MASTER CLINICIAN SESSION

IL DR MARCO COLLA DURANTE LA MASTER CLINICIAN SESSION

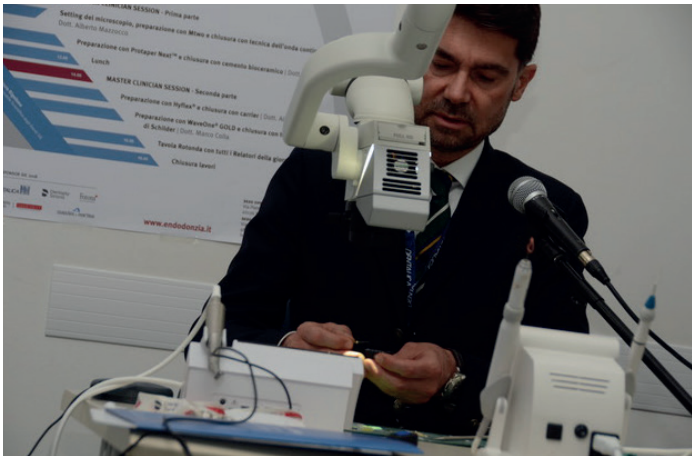

IL PROF. DANIELE ANGERAME DURANTE LA MASTER CLINICIAN SESSION

I RELATORI E I PRESIDENTI DI SEDUTA

VITA SOCIETARIA

SINTESI DELLA GIORNATA ENDODONTICA REGIONALE SICILIANA SSE

Il trattamento endodontico: le regole del successo, i motivi degli insuccessi

5 maggio 2018 - Dott. Alfio Pappalardo

Sono stati oltre duecento i partecipanti alla Giornata Endodontica Regionale SSE che si è svolta nella splendida cornice di Catania sabato 5 maggio, attratti da un programma scientifico di assoluta rilevanza e ricco di spunti interessanti, frutto dell'impegno di Soci Attivi amanti dell'Endodonzia.

L'affluenza alla Giornata ha superato le aspettative degli organizzatori, indice di apprezzamento per questo genere di iniziative. Il nostro intento, spiega il segretario regionale della SSE, Alfio Pappalardo, è stato quello di fornire in modo semplice e chiaro, tutti gli aggiornamenti necessari ad un miglioramento della nostra disciplina endodontica quotidiana.

Prestigiosi relatori si sono alternati nel corso della giornata, il professor Vito Malagnino ha aperto i lavori parlandoci di Microscopia e Ni-Ti nell'Endodonzia quotidiana, successivamente il dottor Roberto Fornara ha presentato la sua relazione parlando dell'imaging tridimensionale in Endodonzia, a seguire, il dottor Italo Di Giuseppe ha trattato il ruolo primario della detersione meccanica. Al professor Ernesto Rapisarda e al dottor Eugenio Pedullà il compito di illustrare le novità in tema di strumentazione endodontica, la frattura degli strumenti è stata trattata dal dottor Giovanni Messina.

La sessione pomeridiana è stata introdotta dal dottor Ciro Fuschino parlando di Endodonzia con E maiuscola, la dottoressa Denise Pontoriero e il dottor Enrico Carmignani hanno presentato una completa relazione sull'approccio clinico nel razionale del trattamento.

Il razionale nei trattamenti endodontici complessi è stata la relazione affrontata dal dottor Mario Palmeri, infine il dottor Massimo Calapaj ha chiuso le relazioni pomeridiane esibendo casi di chirurgia endodontica.

Un elogio va fatto anche alla SIE Nazionale per l'impegno nell'avvicinare i giovani odontoiatri all'arte endodontica e per essere un punto di riferimento certo per la crescita professionale ed individuale di ogni Odontoiatria che aderisce a questa Società.

Inoltre, desidero ringraziare per la preziosa collaborazione l'Università degli studi di Catania, Messina e Palermo, le associazioni di categoria AIO, ANDI, COI-AIG e tutto il Direttivo dell'Ordine dei Medici di Catania, infine, un ringraziamento a tutti gli sponsor che ci hanno consentito di poter svolgere al meglio il nostro lavoro.

LA PLATEA

TUTTI I RELATORI DELLA GIORNATA SSE

IL SEGRETARIO SSE DR ALFIO PAPPALARDO CON LE AUTORITÀ

GIORNALE ITALIANO DI ENDODONZIA

INSTRUCTION AUTHOR

CONTENT OF AUTHOR GUIDELINES:

1. ***General***
2. ***Ethical Guidelines***
3. ***Manuscript Submission Procedure***
4. ***Manuscript Types Accepted***
5. ***Manuscript Format and Structure***
6. ***After Acceptance***
7. ***Open Access***
8. ***Creative Commons Attribution-NonCommercial-NoDerivs (CC BY-NC-ND)***
9. ***Author Rights***

The journal to which you are submitting your manuscript employs a plagiarism detection system. By submitting your manuscript to this journal you accept that your manuscript may be screened for plagiarism against previously published works.

1. GENERAL

Giornale Italiano di Endodonzia publishes original scientific articles, reviews, clinical articles and case reports in the field of Endodontology. Scientific contributions dealing with health, injuries to and diseases of the pulp and periradicular region, and their relationship with systemic well-being and health. Original scientific articles are published in the areas of biomedical science, applied materials science, bioengineering, epidemiology and social science relevant to endodontic disease and its management, and to the restoration of root-treated teeth. In addition, review articles, reports of clinical cases, book reviews, summaries and abstracts of scientific meetings and news items are accepted.

Please read the instructions below carefully for details on the submission of manuscripts, the journal's requirements and standards as well as information concerning the procedure after a manuscript has been accepted for publication in *Giornale Italiano di Endodonzia*. Authors are encouraged to visit GIE web site **gi-endodonzia.com** for further information on the preparation and submission of articles and figures.

2. ETHICAL GUIDELINES

Giornale Italiano di Endodonzia adheres to the below ethical guidelines for publication and research.

2.1. Authorship and Acknowledgements

Authors submitting a paper do so on the understanding that the manuscript has been read and approved by all authors and that all authors agree to the submission of the manuscript to the *Giornale Italiano di Endodonzia*.

Giornale Italiano di Endodonzia adheres to the definition of authorship set up by The International Committee of Medical Journal Editors (ICMJE). According to the ICMJE, authorship criteria should be based on 1) substantial contributions to conception and design of, or acquisiation of data or analysis and interpretation of data, 2) drafting the article or revising it critically for important intellectual content and 3) final approval of the version to be published. Authors should meet conditions 1, 2 and 3.

It is a requirement that all authors have been accredited as appropriate upon submission of the manuscript. Contributors who do not qualify as authors should be mentioned under Acknowledgements.

Acknowledgements:
Under acknowledgements please specify contributors to the article other than the authors accredited. Please also include specifications of the source of funding for the study and any potential conflict of interests if appropriate.

2.2. Ethical Approvals

Experimentation involving human subjects will only be published if such research has been conducted in full accordance with ethical principles, including the World Medical Association Declaration of Helsinki (version 2008) and the additional requirements, if any, of the country where the research has been carried out.

Manuscripts must be accompanied by a statement that the experiments were undertaken with the understanding and written consent of each subject and according to the above mentioned principles. A statement regarding the fact that the study has been independently reviewed and approved by an ethical board should also be included. Editors reserve the right to reject papers if there are doubts as to whether appropriate procedures have been used.

When experimental animals are used the methods section must clearly indicate that adequate measures were taken to minimize pain or discomfort. Experiments should be carried out in accordance with the Guidelines laid down by the National Institute of Health (NIH) in the USA regarding the care and use of animals for experimental procedures or with the European Communities Council Directive of 24 November 1986 (86/609/EEC) and in accordance with local laws and regulations.

All studies using human or animal subjects should include an explicit statement in the Material and Methods section identifying the review and ethics committee approval for each study, if applicable. Editors reserve the right to reject papers if there is doubt as to whether appropriate procedures have been used.

2.3 Clinical Trials

Clinical trials should be reported using the guidelines available at www.consort-statement.org.
A CONSORT checklist and flow diagram (as a Figure) should also be included in the submission material.

The *Giornale Italiano di Endodonzia* encourages authors submitting manuscripts reporting from a clinical trial to register the trials in any of the following free, public clinical trials registries: www.clinicaltrials.gov, http://clinicaltrials.ifpma.org/clinicaltrials/, http://isrctn.org/. The clinical trial registration number and name of the trial register will then be published with the paper.

2.4 Systematic Reviews

Systematic reviews should be reported using the PRISMA guidelines available at http://prisma-statement.org/. A PRISMA checklist and flow diagram (as a Figure) should also be included in the submission material.

2.5 Conflict of Interest and Source of Funding

Giornale Italiano di Endodonzia requires that all sources of institutional, private and corporate financial support for the work within the manuscript must be fully acknowledged, and any potential conflicts of interest noted. Grant or contribution numbers may be acknowledged, and principal grant holders should be listed. Please include the information under Acknowledgements.

2.6 Appeal of Decision

The decision on a paper is final and cannot be appealed.

2.7 Permissions

If all or parts of previously published illustrations are used, permission must be obtained from the copyright holder concerned. It is the author's responsibility to obtain these in writing and provide copies to the Publishers.

3. MANUSCRIPT SUBMISSION PROCEDURE

Manuscripts should be submitted electronically by e-mail:
editor.giornale@endodonzia.it

3.1. Manuscript Files Accepted

Manuscripts should be uploaded as Word (.doc) or Rich Text Format (.rft) files (not write-protected) plus separate figure files. GIF, JPEG, PICT or Bitmap files are acceptable for submission, but only high-resolution TIF or EPS files are suitable for printing.

The text file must contain the abstract, main text, references, tables, and figure legends, but no embedded figures or Title page. The Title page should be provided as a separate file.
In the main text, please reference figures as for instance 'Figure 1', 'Figure 2' etc to match the tag name you choose for the individual figure files uploaded. Manuscripts should be formatted as described in the Author Guidelines below.

3.2. Blinded Review

Manuscript that do not conform to the general aims and scope of the journal will be returned immediately without review.
All other manuscripts will be reviewed by experts in the field (generally two referees).
Giornale Italiano di Endodonzia aims to forward referees´ comments and to inform the corresponding author of the result of the review process.

Manuscripts will be considered for fast-track publication under special circumstances after consultation with the Editor.

Giornale Italiano di Endodonzia uses double blinded review. The names of the reviewers will thus not be disclosed to the author submitting a paper and the name(s) of the author(s) will not be disclosed to the reviewers.

To allow double blinded review, please submit your main manuscript and title page as separate files.

3.3. E-mail Confirmation of Submission

After submission you will receive an e-mail to confirm receipt of your man-

uscript. If you do not receive the confirmation e-mail after 24 hours, please send an e-mail once again to editor.giornale@endodonzia.it or contact segreteria.sie@me.com.

3.4. Submission of Revised Manuscripts

All the revised manuscripts will be sent to the author; to submit a revised masucript please re-contact the e-mail address of the journal: editor.giornale@endodonzia.it.

4. MANUSCRIPT TYPES ACCEPTED

Original Scientific Articles: must describe significant and original experimental observations and provide sufficient detail so that the observations can be critically evaluated and, if necessary, repeated. Original Scientific Articles must conform to the highest international standards in the field.

Review Articles: are accepted for their broad general interest; all are refereed by experts in the field who are asked to comment on issues such as timeliness, general interest and balanced treatment of controversies, as well as on scientific accuracy. Reviews should generally include a clearly defined search strategy and take a broad view of the field rather than merely summarizing the authors´ own previous work. Extensive or unbalanced citation of the authors´ own publications is discouraged.

Mini Review Articles: are accepted to address current evidence on well-defined clinical, research or methodological topics. All are refereed by experts in the field who are asked to comment on timeliness, general interest, balanced treatment of controversies, and scientific rigor. A clear research question, search strategy and balanced synthesis of the evidence is expected. Manuscripts are limited in terms of word-length and number of figures.

Clinical Articles: are suited to describe significant improvements in clinical practice such as the report of a novel technique, a breakthrough in technology or practical approaches to recognised clinical challenges. They should conform to the highest scientific and clinical practice standards.

Case Reports: illustrating unusual and clinically relevant observations are acceptable but they must be of sufficiently high quality to be considered worthy of publication in the Journal. On rare occasions, completed cases displaying non-obvious solutions to significant clinical challenges will be considered. Illustrative material must be of the highest quality and healing outcomes, if appropriate, should be demonstrated.

5. MANUSCRIPT FORMAT AND STRUCTURE

5.1. Format

Language: The language of publication is English. It is preferred that manuscript is professionally edited. All services are paid for and arranged by the author, and use of one of these services does not guarantee acceptance or preference for publication

Presentation: Authors should pay special attention to the presentation of their research findings or clinical reports so that they may be communicated clearly. Technical jargon should be avoided as much as possible and clearly explained where its use is unavoidable. Abbreviations should also be kept to a minimum, particularly those that are not standard. The background and hypotheses underlying the study, as well as its main conclusions, should be clearly explained. Titles and abstracts especially should be written in language that will be readily intelligible to any scientist.

Abbreviations: Giornale Italiano di Endodonzia adheres to the conventions outlined in Units, Symbols and Abbreviations: A Guide for Medical and Scientific Editors and Authors. When non-standard terms appearing 3 or more times in the manuscript are to be abbreviated, they should be written out completely in the text when first used with the abbreviation in parenthesis.

5.2. Structure

All manuscripts submitted to Giornale Italiano di Endodonzia should include Title Page, Abstract, Main Text, References and Acknowledgements, Tables, Figures and Figure Legends as appropriate

Title Page: The title page should bear: (i) Title, which should be concise as well as descriptive; (ii) Initial(s) and last (family) name of each author; (iii) Name and address of department, hospital or institution to which work should be attributed; (iv) Running title (no more than 30 letters and spaces); (v) No more than six keywords (in alphabetical order); (vi) Name, full postal address, telephone, fax number and e-mail address of author responsible for correspondence.

Abstract for Original Scientific Articles should be no more than 250 words giving details of what was done using the following structure:

- **Aim:** Give a clear statement of the main aim of the study and the main hypothesis tested, if any.
- **Methodology:** Describe the methods adopted including, as appropriate, the design of the study, the setting, entry requirements for subjects, use of materials, outcome measures and statistical tests.
- **Results:** Give the main results of the study, including the outcome of any statistical analysis.
- **Conclusions:** State the primary conclusions of the study and their implications. Suggest areas for further research, if appropriate.

Abstract for Review Articles should be non-structured of no more than 250 words giving details of what was done including the literature search strategy.

Abstract for Mini Review Articles should be non-structured of no more than 250 words, including a clear research question, details of the literature search strategy and clear conclusions.

Abstract for Case Reports should be no more than 250 words using the following structure:

- **Aim:** Give a clear statement of the main aim of the report and the clinical problem which is addressed.
- **Summary:** Describe the methods adopted including, as appropriate, the design of the study, the setting, entry requirements for subjects, use of materials, outcome measures and analysis if any.
- **Key learning points:** Provide up to 5 short, bullet-pointed statements to highlight the key messages of the report. All points must be fully justified by material presented in the report.

Abstract for Clinical Articles should be no more than 250 words using the following structure:

- **Aim:** Give a clear statement of the main aim of the report and the clinical problem which is addressed.
- **Methodology:** Describe the methods adopted.
- **Results:** Give the main results of the study.
- **Conclusions:** State the primary conclusions of the study.

Main Text of Original Scientific Article should include Introduction, Materials and Methods, Results, Discussion and Conclusion.

Introduction: should be focused, outlining the historical or logical origins of the study and gaps in knowledge. Exhaustive literature reviews are not appropriate. It should close with the explicit statement of the specific aims of the investigation, or hypothesis to be tested.

Material and Methods: must contain sufficient detail such that, in combination with the references cited, all clinical trials and experiments reported can be fully reproduced.

(i) Clinical Trials should be reported using the CONSORT guidelines available at www.consort-statement.org. A CONSORT checklist and flow diagram (as a Figure) should also be included in the submission material.

(ii) Experimental Subjects: experimentation involving human subjects will only be published if such research has been conducted in full accordance with ethical principles, including the World Medical Association Declaration of Helsinki (version 2008) and the additional requirements, if any, of the country where the research has been carried out. Manuscripts must be accompanied by a statement that the experiments were undertaken with the understanding and written consent of each subject and according to the above mentioned principles. A statement regarding the fact that the study has been independently reviewed and approved by an ethical board should also be included. Editors reserve the right to reject papers if there are doubts as to whether appropriate procedures have been used.

When experimental animals are used the methods section must clearly indicate that adequate measures were taken to minimize pain or discomfort. Experiments should be carried out in accordance with the Guidelines laid down by the National Institute of Health (NIH) in the USA regarding the care and use of animals for experimental procedures or with the European Communities Council Directive of 24 November 1986 (86/609/EEC) and in accordance with local laws and regulations.

All studies using human or animal subjects should include an explicit statement in the Material and Methods section identifying the review and ethics committee approval for each study, if applicable.

Editors reserve the right to reject papers if there is doubt as to whether appropriate procedures have been used.

(iii) Suppliers: Suppliers of materials should be named and their location (Company, town/city, state, country) included.

Results: should present the observations with minimal reference to earlier literature or to possible interpretations. Data should not be duplicated in Tables and Figures.

Discussion: may usefully start with a brief summary of the major findings, but repetition of parts of the abstract or of the results section should be avoided. The Discussion section should progress with a review of the methodology before discussing the results in light of previous work in the field. The Discussion should end with a brief conclusion and a comment on the potential clinical relevance of the findings. Statements and interpretation of the data should be appropriately supported by original references.

Conclusion: should contain a summary of the findings.

Main Text of Review Articles should be divided into Introduction, Review and Conclusions. The Introduction section should be focused to place the subject matter in context and to justify the need for the review. The Review section should be divided

into logical sub-sections in order to improve readability and enhance understanding. Search strategies must be described and the use of state-of-the-art evidence-based systematic approaches is expected. The use of tabulated and illustrative material is encouraged. The Conclusion section should reach clear conclusions and/or recommendations on the basis of the evidence presented.

Main Text of Mini Review Articles should be divided into Introduction, Review and Conclusions. The Introduction section should briefly introduce the subject matter and justify the need and timeliness of the literature review. The Review section should be divided into logical sub-sections to enhance readability and understanding and may be supported by up to 5 tables and figures. Search strategies must be described and the use of state-of-the-art evidence-based systematic approaches is expected. The Conclusions section should present clear statements/recommendations and suggestions for further work. The manuscript, including references and figure legends should not normally exceed 4000 words.

Main Text of Clinical Reports and Clinical Articles should be divided into Introduction, Report, Discussion and Conclusion,. They should be well illustrated with clinical images, radiographs, diagrams and, where appropriate, supporting tables and graphs. However, all illustrations must be of the highest quality

Acknowledgements: *Giornale Italiano di Endodonzia* requires that all sources of institutional, private and corporate financial support for the work within the manuscript must be fully acknowledged, and any potential conflicts of interest noted. Grant or contribution numbers may be acknowledged, and principal grant holders should be listed. Acknowledgments should be brief and should not include thanks to anonymous referees and editors.

5.3. References

It is the policy of the Journal to encourage reference to the original papers rather than to literature reviews. Authors should therefore keep citations of reviews to the absolute minimum.

We recommend the use of a tool such as EndNote or Reference Manager for reference management and formatting. EndNote reference styles can be searched for here: www.endnote.com/support/enstyles.asp. Reference Manager reference styles can be searched for here: www.refman.com/support/rmstyles.asp

In the text: a number in order of citation is the reference inside the manuscript; example (1)
Reference list: All references should be brought together at the end of the paper in numerical order and should be in the following form.
- Names and initials of up to six authors. When there are seven or more, list the first three and add et al.
- Full title of paper followed by a full stop (.)
- Title of journal abbreviated (es. Journal of Endodontics : J Endod)
- Year of publication followed by ;
- Volume number
- Issue number in parenthesis (es.: (5)) followed by :
- First and last pages

Examples of correct forms of reference follow:

Standard journal article
(1) Somma F, Cammarota G, Plotino G, Grande NM, Pameijer CH. The effectiveness of manual and mechanical instrumentation for the retreatment of three different root canal filling materials. J Endod 2008;34(4):466–9.

Corporate author
British Endodontic Society - Guidelines for root canal treatment. Giornale Italiano di Endodonzia 1979 ; 16: 192-5.

Journal supplement
Frumin AM, Nussbaum J, Esposito M () Functional asplenia: demonstration of splenic activity by bone marrow scan (Abstract). Blood 1979; 54 (Suppl. 1): 26a.

Books and other monographs

Personal author(s)
Gutmann J, Harrison JW Surgical Endodontics, 1st edn Boston, MA, USA: Blackwell Scientific Publications, 1991.

Chapter in a book
Wesselink P Conventional root-canal therapy III: root filling. In: Harty FJ, ed. Endodontics in Clinical Practice, (1990) , 3rd edn; pp. 186-223. London, UK: Butterworth.

Published proceedings paper
DuPont B Bone marrow transplantation in severe combined immunodeficiency with an unrelated MLC compatible donor. In: White HJ, Smith R, eds. Proceedings of the Third Annual Meeting of the International Society for Experimental Rematology; (1974), pp. 44-46. Houston, TX, USA: International Society for Experimental Hematology.

Agency publication
Ranofsky AL Surgical Operations in Short-Stay Hospitals: United States-1975 (1978). DHEW publication no. (PHS) 78-1785 (Vital and Health Statistics; Series 13; no. 34.) Hyattsville, MD, USA: National Centre for Health Statistics.8

Dissertation or thesis
Saunders EM In vitro and in vivo investigations into root-canal obturation using thermally softened gutta-percha techniques (PhD Thesis) (1988). Dundee, UK: University of Dundee.

URLs
Full reference details must be given along with the URL, i.e. authorship, year, title of document/report and URL. If this information is not available, the reference should be removed and only the web address cited in the text.
Smith A Select committee report into social care in the community [WWW document]. (1999) URL http://www.dhss.gov.uk/reports/report015285.html
[accessed on 7 November 2003]

5.4. Tables, Figures and Figure Legends

Tables: Tables should be double-spaced with no vertical rulings, with a single bold ruling beneath the column titles. Units of measurements must be included in the column title.
Figures: All figures should be planned to fit within either 1 column width (8.0 cm), 1.5 column widths (13.0 cm) or 2 column widths (17.0 cm), and must be suitable for photocopy reproduction from the printed version of the manuscript. Lettering on figures should be in a clear, sans serif typeface (e.g. Helvetica); if possible, the same typeface should be used for all figures in a paper. After reduction for publication, upper-case text and numbers should be at least 1.5-2.0 mm high (10 point Helvetica). After reduction, symbols should be at least 2.0-3.0 mm high (10 point). All half-tone photographs should be submitted at final reproduction size. In general, multi-part figures should be arranged as they would appear in the final version. Reduction to the scale that will be used on the page is not necessary, but any special requirements (such as the separation distance of stereo pairs) should be clearly specified.

Unnecessary figures and parts (panels) of figures should be avoided: data presented in small tables or histograms, for instance, can generally be stated briefly in the text instead. Figures should not contain more than one panel unless the parts are logically connected; each panel of a multipart figure should be sized so that the whole figure can be reduced by the same amount and reproduced on the printed page at the smallest size at which essential details are visible.

Figures should be on a white background, and should avoid excessive boxing, unnecessary colour, shading and/or decorative effects (e.g. 3-dimensional skyscraper histograms) and highly pixelated computer drawings. The vertical axis of histograms should not be truncated to exaggerate small differences. The line spacing should be wide enough to remain clear on reduction to the minimum acceptable printed size.

Figures divided into parts should be labelled with a lower-case, boldface, roman letter, a, b, and so on, in the same typesize as used elsewhere in the figure. Lettering in figures should be in lower-case type, with the first letter capitalized.
Units should have a single space between the number and the unit, and follow SI nomenclature or the nomenclature common to a particular field. Thousands should be separated by a thin space (1 000). Unusual units or abbreviations should be spelled out in full or defined in the legend. Scale bars should be used rather than magnification factors, with the length of the bar defined in the legend rather than on the bar itself. In general, visual cues (on the figures themselves) are preferred to verbal explanations in the legend (e.g. broken line, open red triangles etc.).

Figure legends: Figure legends should begin with a brief title for the whole figure and continue with a short description of each panel and the symbols used; they should not contain any details of methods.

Permissions: If all or part of previously published illustrations are to be used, permission must be obtained from the copyright holder concerned. This is the responsibilty of the authors before submission.

Preparation of Electronic Figures for Publication: Although low quality images are adequate for review purposes, print publication requires high quality images to prevent the final product being blurred or fuzzy.
Submit EPS (lineart) or TIFF (halftone/photographs) files only. MS PowerPoint and Word Graphics are unsuitable for printed pictures. Do not use pixel-oriented programmes. Scans (TIFF only) should have a resolution of 300 dpi (halftone) or 600 to 1200 dpi (line drawings) in relation to the reproduction size (see below). EPS files should be saved with fonts embedded (and with a TIFF preview if possible).
For scanned images, the scanning resolution (at final image size) should be as follows to ensure good reproduction: lineart: >600 dpi; half-tones (including gel photographs): >300 dpi; figures containing both halftone and line images: >600 dpi.

6. AFTER ACCEPTANCE

Upon acceptance of a paper for publication, the manuscript will be forwarded to the Production Editor who is responsible for the production of the journal.

6.1. Figures

Hard copies of all figures and tables are required when the manuscript is ready for publication. These will be requested by the Editor when required. Each Figure copy should be marked on the reverse with the figure number and the corresponding author's name.

6.2 Proof Corrections
The corresponding author will receive an email alert containing a link to a web site.
A working email address must therefore be provided for the corresponding author. The proof can be downloaded as a PDF (portable document format) file from this site. Acrobat Reader will be required in order to read this file. This software can be downloaded (free of charge) from the following Web site: www.adobe.com/products/acrobat/readstep2.html.
This will enable the file to be opened, read on screen, and printed out in order for any corrections to be added.
Further instructions will be sent with the proof. Hard copy proofs will be posted if no e-mail address is available; in your absence, please arrange for a colleague to access your e-mail to retrieve the proofs.
Proofs must be returned to the Production Editor within five days of receipt, even if there are no corrections.
Elsevier may proceed with publication of the article if no response is received.
As changes to proofs are costly, we ask that you only correct typesetting errors.
Excessive changes made by the author in the proofs, excluding typesetting errors, will be charged separately.
Other than in exceptional circumstances, all illustrations are retained by the publisher.
Please note that the author is responsible for all statements made in his work, including changes made by the copy editor.

7. OPEN ACCESS

Every peer-reviewed research article appearing in this journal will be published open access. This means that the article is universally and freely accessible via the internet in perpetuity, in an easily readable format immediately after publication. The author does not have any publication charges for open access. The Società Italiana di Endodonzia will pay to make the article open access. A CC user license manages the reuse of the article (see http://www.elsevier.com/openaccesslicenses). All articles will be published under the following license:

8. Creative Commons Attribution-NonCommercial-NoDerivs (CC BY-NC-ND)

For non-commercial purposes, lets others distribute and copy the article, and to include in a collective work (such as an anthology), as long as they credit the author(s) and provided they do not alter or modify the article

9. AUTHOR RIGHTS

As an author you (or your employer or institution) have certain rights to reuse your work. For more information on author rights please see http://www.elsevier.com/copyright.

ISTRUZIONI AGLI AUTORI

Il Giornale Italiano di Endodonzia è una pubblicazione esclusivamente disponibile in formato elettronico e rappresenta l'organo ufficiale della Società Italiana di Endodonzia.

Si appoggia, per la sua diffusione ad Elsevier e gli articoli in esso pubblicati sono reperibili su Scopus.

La cadenza di pubblicazione è semestrale: **Giugno/Novembre.**

Per quanto attiene le norme editoriali per la pubblicazione di articoli aventi come tema l'Endodonzia in senso lato si pregano gli autori di riferirsi al documento in inglese reperibile sul sito www.gi-endodonzia.com.

Articoli in lingua italiana saranno pubblicabili, ma si darà preferenza a contributi in lingua inglese che potrebbero avere una risonanza internazionale ben più ampia.

La Società Italiana di Endodonzia si farà carico di rivedere la forma dei contributi in lingua inglese attraverso un sistema di controllo specifico.