Production and hosting by Elsevier

ISSN 1121 – 4171

2 | November 2015 | Vol. 29 |

# GIORNALE ITALIANO DI ENDODONZIA

Società Italiana di Endodonzia



Available online at www.sciencedirect.com

ScienceDirect

# SIROLaser Blue. L'UNICO CON 3 LUNGHEZZE D'ONDA, PER POSSIBILITÀ ILLIMITATE!

SIROLaser Blue stabilisce un nuovo standard nell'odontoiatria laser. E' infatti il primo laser dentale con una lunghezza d'onda di 445 nm (luce blu), grazie a cui è possibile operare senza toccare i tessuti e con una precisione, efficacia e pulizia mai viste prima. Grazie a due ulteriori lunghezze d'onda nella gamma rossa a 660 nm e infrarossa a 970 nm, dispone di una flessibilità di utilizzo insuperabile: biostimolazione, endodonzia, parodonto, afte, herpes, ecc. Per i vostri pazienti SIROLaser Blue significa trattamento indolore e atraumatico, con una dose minore di anestesia, la sicurezza dei puntali monouso e l'affidabilità del marchio Sirona.
**Sarà una buona giornata. Con Sirona.**

**LUCE BLU A 445 NM**

**per una precisione di taglio insuperabile, senza contatto coi tessuti.**

**NEW**

**3 LUNGHEZZE D'ONDA**

**tecnologia multi diodo: un apparecchio - 3 lunghezze d'onda per una flessibilità di utilizzo insuperabile.**

**DESIGN**

**ergonomico ed intuitivo: nuovo manipolo laser in acciaio e puntali monouso garantiscono il massimo comfort operativo e la migliore igiene.**


Relatore:
**Prof. Mauro Labanca**

Partecipa alla Conferenza Teorica - WorkShop Pratico

**La chirurgia in odontoiatria tra tradizione ed innovazione**

**Venerdì 23 Ottobre 2015**

Per maggiori informazioni visita il sito www.simiteducation.it/chirurgia
Tel.: 0376 267811 - info@simitdental.it

SIMIT DENTAL

The Dental Company

sirona.

DENTSPLY MAILLEFER

# wave•one® GOLD

Distributore Esclusivo SIMIT DENTAL

Affronta il canale
con **sicurezza**

## RESTODONTICS TOUR
RESTORATIVE ENDODONTICS

conferenza teorica

## Dall'endodonzia al restauro coronale: soluzione semplice ed integrata a 360°

**Prof. Giuseppe Cantatore**
**Firenze - Sabato 28 Novembre 2015**
Univ. Degli Studi di Firenze

Quota di partecipazione: Odontoiatri € **122,00** iva inclusa
**RICEVI IN OMAGGIO L'EQUIVALENTE VALORE IN MERCE:**
n.1 Blister di Protaper Next da n.3 strumenti (X1-X2-X3 25 mm)
n.1 Conf. di SDR da 15 compula (0,25 gr. cad.)


Iscrizioni e Segreteria organizzativa: Simit Dental Srl - Tel.: **0376.267832** *(Sig.ra Elisa Baggio)* - email: **education@simitdental.it**

SIMIT DENTAL · For better dentistry DENTSPLY · DENTSPLY MAILLEFER · Italian Dental Journal

iscrizioni online: **www.simiteducation.it/restodontics**

GIORNALE ITALIANO DI ENDODONZIA

Organo Ufficiale della SIE – Società Italiana di Endodonzia

# EDITORIAL BOARD

# RECIPROC®

*one file endo*

## Efficienza e Semplicità

### La preparazione del canale con un solo strumento

- SEMPLICE DA USARE ▸ Meno fasi di lavoro e nessuna sequenza da ricordare
- SICURO ▸ Minori rischi di frattura e avvitamento anche in canali curvi e stretti
- MONOUSO ▸ Conveniente perché elimina le fasi di pulizia e sterilizzazione

Per maggiori informazioni sul sistema RECIPROC® visita il sito

▸ www.dentsply.it

For better dentistry

DENTSPLY

Numero Verde 800-310333

DENTSPLY Italia S.r.l.
Piazza dell'Indipendenza, 11B · 00185 Roma · Fax 06 72640394
infoweb.italia@dentsply.com · www.dentsply.it


# Performance meets Mobility

- Innovativo micromotore endodontico cordless con movimento continuo e reciprocante
- Manipolo maneggevole, ergonomico, perfettamente bilanciato
- Gestione semplice ed intuitiva grazie alla App per iPad Apple

L'applicazione VDW.CONNECT è compatibile con iPad mini e iPad con Bluetooth 4.0 e aggiornamento iOS 8.0 e successivi.
Apple, il logo Apple, App Store e iPad sono marchi registrati Apple Inc.

**SENZA APP/iPad**
l'unico motore cordless per il sistema reciprocante
RECIPROC®

**CON LA APP**
per i sistemi alternati e rotanti più diffusi

Numero Verde 800-310333

DENTSPLY Italia S.r.l.
Piazza dell'Indipendenza, 11B · 00185 Roma · Fax 06 72640394
infoweb.italia@dentsply.com · www.dentsply.it

For better dentistry
DENTSPLY

2

November 2015 | Vol. 29

GIORNALE ITALIANO DI ENDODONZIA

Organo Ufficiale della SIE – Società Italiana di Endodonzia

Società Italiana di Endodonzia



SIE - Società Italiana di Endodonzia
Via P. Custodi 3 – 20136 Milano
Tel. 02 8376799
Fax. 02 89424876
segreteria.sie@me.com
segreteria.sie@pec.segreteriasie.it
www.journals.elsevier.com/giornale-italiano-di-endodonzia/

# TABLE OF CONTENTS



>

EDITORIAL OFFICE

E-mail: editor.giornale@endodonzia.it
Website: www.journals.elsevier.com/giornale-italiano-di-endodonzia/

Managing Director
Pio Bertani

Editorial Director
Vittorio Franco

OPERATIONS

Journal Manager
Justyna Kasprzycka
giendo@elsevier.com

PUBLISHING

Publishing Support Manager
Ponni Brinda Rajan
p.rajan@elsevier.com

***Giornale Italiano di Endodonzia*** was founded in 1987 and is the official journal of the Italian Society of Endodontics (SIE). It is a peer-reviewed journal publishing original articles on clinical research and/or clinical methodology, case reports related to Endodontics. The Journal evaluates also contributes in restorative dentistry, dental traumatology, experimental pathophysiology, pharmacology and microbiology dealing with Endodontics. Giornale Italiano di Endodonzia is indexed in Scopus and Embase and published online only on ScienceDirect. SIE members can access the journal through the website: www.journals.elsevier.com/giornale-italiano-di-endodonzia/



REGISTRATION Court of Milan n ° 89, 3 March 2009

# TABLE OF CONTENTS



ELSEVIER | Production and hosting by Elsevier

Giornale Italiano di Endodonzia - full text available on ScienceDirect©

Volume 29 | n. 2 | November 2015

Amsterdam • Boston • Jena • London • New York • Oxford • Paris • Philadelphia • San Diego • St. Louis

MICRO MEGA

Your Endo Specialist™


# Lasciati guidare

Dal 1905 MICRO-MEGA è sinonimo di qualità ed eccellenza in ambito endodontico. L'ampia gamma di strumenti e il nuovo motore con rilevatore apicale integrato ti accompagnano in ogni passo del trattamento, dalla preparazione del canale all'otturazione.

**MICRO-MEGA, il giusto riferimento per chi ricerca la perfezione.**

Thinking ahead. Focused on life.

MORITA

# Endodonzia per i più esigenti

**Diagnosticare, Informare, Trattare, Curare, Guarire**

Il motore endodontico TriAuto mini di Morita racchiude tutte le funzioni nel suo sottile manipolo garantendo la massima sicurezza per l'utilizzatore e il paziente. Durante il trattamento TriAuto mini dimostra un'elevata flessibilità grazie alla sua modularità: undici velocità, modifica delle funzioni con la pressione di un tasto, sicurezza grazie a sei posizioni di salvataggio e display con tutte le informazioni rilevanti. L'aspetto migliore: è possibile utilizzarlo anche in combinazione con il localizzatore apicale Root ZX mini per misurare e preparare velocemente il canale radicolare.
Maggiori offerte e dettagli sono disponibili all'indirizzo: **www.jmoritaitalia.com**

Giornale Italiano di Endodonzia (2015) **29**, 37

Società Italiana di Endodonzia

Disponibile online all'indirizzo www.sciencedirect.com

ScienceDirect

journal homepage: www.elsevier.com/locate/gie

EDITORIALE/EDITORIAL

# Cone Beam TC: una doppia preoccupazione

## *Cone Beam TC: a double concern*

L'avvento della tecnologia digitale, attraverso le sistematiche tipo Cone Beam TC, ha trasformato la diagnostica odontoiatrica e, in particolare, quella della disciplina endodontica.

L'entusiasmo per la metodologia ha così generato, spesso celata, una doppia problematica: da un lato l'inadeguatezza di molti di noi nel formulare una diagnosi precisa, dall'altro ha portato a minimizzare, e può darsi che lo sia, il rischio radiogeno che, sebbene molto ben documentato nella misura, rimane sicuramente più alto rispetto a quello della sola esposizione per un radiogramma endorale.

Volendo usare un paradosso, ancora una volta il progresso porta con sè soluzioni e preoccupazioni. In aggiunta, diagnosticare con precisione le patologie periapicali, spesso subdole e poco visibili con le radiografie bidimensionali, non ci sottrae, infatti, dal valutare, a posteriori, con i medesimi mezzi la loro evoluzione o la loro guarigione.

Si arriverebbe quindi a sostituire un esame, la cui minima invasività può essere certificata sulla base di molti studi, con uno più rischioso, da un punto di vista radiogeno, per i pazienti.

Quale soluzione?

La tecnologia le porterà certamente nel prossimo futuro; al momento attuale, forse, attenersi a criteri clinico-radiologici tradizionali nei casi più conclamati potrebbe essere una soluzione valida e con un carico di preoccupazioni ridotte.

P.S. La Società Europea di Endodonzia (ESE) sulla CBCT ha recentemente messo in linea un documento che potrebbe essere utile a riguardo:
http://onlinelibrary.wiley.com/store/10.1111/iej.12267/asset/iej12267.pdf?v=1&t=ica734u3&s=f5abc6fe51ea6a3f4aa7ef94c72ccee3298f4c06

The new digital technologies, such as Cone Beam TC, transformed the diagnostic process in dentistry and, particularly, in endodontics.

This radiographic device generated a huge enthusiasm and a double concern: the former, a diffuse feeling to be inadequate in the whole diagnostic process, the latter, to minimize the risk connected with the radiation amount, even if well documented in its safeness, that is higher if compared to the one of a single intra-oral radiogram.

Using a paradox, once again the progress brings with it solutions and concerns.

In addition, a precise diagnosis of the periapical pathosis, frequently misdiagnosed using the intraoral radiograms alone, compel us to follow the same procedure for follow-ups, exposing the patient to further over-amount of radiations.

Which is the solution?

Technology will bring us it in the next future; up to now, perhaps, a strict clinical-radiological surveillance with traditional methods could be the safest track to follow to limit our concerns.

P.S. The European Society of Endodontology (ESE) on the topic CBCT has recently published online a useful document:
http://onlinelibrary.wiley.com/store/10.1111/iej.12267/asset/iej12267.pdf?v=1&t=ica734u3&s=f5abc6fe51ea6a3f4aa7ef94c72ccee3298f4c06

*Editor-in-Chief*
Massimo Gagliani
*Giornale Italiano di Endodonzia*
*E-mail*: editor.giornale@endodonzia.it

Disponibile online il 26 settembre 2015

Peer review under responsibility of Società Italiana di Endodonzia.

Production and hosting by Elsevier

http://dx.doi.org/10.1016/j.gien.2015.08.001

Giornale Italiano di Endodonzia (2015) **29**, 38—50

Available online at www.sciencedirect.com

ScienceDirect

journal homepage: www.elsevier.com/locate/gie

FOCUS

# Endodontic applications of cone beam computed tomography: case series and literature review

*Applicazioni della tomografia computerizzata a fascio conico in Endodonzia: casi clinici e revisione della letteratura*

**Francesc Abella*, Kala Morales, Iván Garrido, Javier Pascual, Fernando Duran-Sindreu, Miguel Roig**

*Department of Restorative Dentistry and Endodontics, Universitat Internacional de Catalunya, Sant Cugat del Vallès, Barcelona, Spain*

Received 22 July 2015; accepted 28 July 2015
Available online 26 September 2015

**KEYWORDS**
Cone beam computed tomography;
Decision-making;
Diagnosis;
Endodontics;
Periapical lesions;
Root canal treatment.

**Abstract** Cone beam computed tomography (CBCT) is a relatively new method that produces three-dimensional (3D) information of the maxillofacial skeleton, including the teeth and their surrounding tissue, with a lower effective radiation dose than traditional CT scans. Specific endodontic applications for CBCT are being identified as the use of this technology becomes more common. CBCT has great potential to become a valuable tool for diagnosing and managing endodontic problems, as well as for assessing root fractures, apical periodontitis, resorptions, perforations, root canal anatomy and the nature of the alveolar bone topography around teeth. This article aims to review cone beam technology and its advantages over CT scans and conventional radiography, to illustrate current and future clinical applications in endodontic practice, and to highlight areas of further research of CBCT in endodontics. Specific case examples illustrate how treatment planning has changed with the images obtained with CBCT technology compared with only periapical radiography.


* Corresponding author at: Universitat Internacional de Catalunya, Dentistry Faculty, C/ Josep Trueta s/n, 08195 Sant Cugat del Vallès, Spain. Tel.: +34 504 2000; fax: +34 504 2031.
*E-mail:* franabella@uic.es (F. Abella).
Peer review under responsibility of Società Italiana di Endodonzia.

Production and hosting by Elsevier

http://dx.doi.org/10.1016/j.gien.2015.08.002
1121-4171/

**PAROLE CHIAVE**
Tomografia computerizzata a fascio conico;
Processo decisionale;
Diagnosi;
Endodonzia;
Lesioni periapicali;
Trattamento endodontico.

**Riassunto** La tomografia computerizzata a fascio conico (CBCT) è un metodo relativamente nuovo che produce informazioni tridimensionali (3D) dello scheletro maxillofacciale, compresi i denti e il loro tessuto circostante, con una dose di radiazione inferiore rispetto alle TC tradizionali. La CBCT può essere utilliazzata in Endodonzia per specifiche applicazioni e l'utilizzo di questa tecnologia si sta diffondendo sempre di più. La CBCT ha un grande potenziale per diventare uno strumento prezioso per la diagnosi e la gestione dei problemi endodontici, nonché per valutare le fratture radicolari, la presenza di lesioni periapicali, riassorbimenti, perforazioni, anatomie canalari particolari e la natura della topografia dell'osso alveolare intorno ai denti. Questo articolo si propone di rivedere la tecnologia a fascio conico ei suoi vantaggi rispetto alla TC e radiologia tradizionale, per illustrare le sue applicazioni cliniche attuali e future in endodonzia, e per evidenziare le aree di ulteriore ricerca che potranno caratterizzare la CBCT in endodonzia. Specifici casi clinici illustreranno inoltre come la pianificazione del trattamento sia cambiato grazie alle immagini ottenute con la tecnologia CBCT rispetto alla sola radiografia periapicale.


## Introduction

Breakthroughs in diagnostic radiology over the last 30 years have led to the development of new technologies with applications in dentistry. The development of hardware and software has facilitated new approaches to dentomaxillofacial treatment and treatment planning. One such advance is cone beam computed tomography (CBCT).

CBCT imaging is a relatively new method of visualizing an individual tooth or the dentition in relation to the surrounding skeletal tissues that creates three-dimensional (3D) images of the area of interest.[1,2] This imaging technique is an increasingly used diagnostic tool in endodontic practice.[3]

In contrast to traditional radiographic methods, which reproduce the 3D anatomy as a two-dimensional (2D) image, CBCT allows the observation of an individual tooth or teeth in any view, rather than in predetermined 'default' views.[4] Thus, CBCT has the potential to improve diagnosis, treatment planning, and the assessment of the outcome of endodontic treatment. The disadvantage of CBCT is its use of ionizing radiation, which means that clinicians must consider the ALARA principle (as low as reasonably achievable) when using the technique and any other imaging modalities. It is important to appraise the effective radiation dose associated with various imaging modalities, their resolution, and the information they provide to the clinician.[5]

The European Society of Endodontology recommended that CBCT imaging should only be considered if the additional information provided by the reconstructed 3D images would aid diagnosis and/or enhance the management of a tooth with an endodontic problem.[6] However, the endodontic literature (and all other dental disciplines) is replete with case reports and *ex-vivo* studies, whereas the number of well-designed clinical trials validating the use of CBCT in endodontics is small, which makes a meta-analysis impossible. The aim of this review, therefore, is to present the pertinent literature, highlighting the relative advantages and disadvantages of CBCT, and to discuss its application in the diagnosis, treatment planning and outcome of endodontic treatment.

## Cone beam computed tomography

The first prototype CBCT scanner was developed in 1982 for angiographic applications.[7] A CBCT scanner for dentomaxillofacial use was developed in the late 1990s and, since the very first report,[8] use of this technique has become widespread in dentistry. Using CBCT, a 3D volume of data is acquired in the course of a single sweep of the scanner. The technique is contingent upon a simple, direct relationship between the sensor and the source, which rotates synchronously 180–360° around the patient's head. The X-ray beam, which is cone-shaped (hence the name of the technique), captures a cylindrical or spherical volume of data, described as the field of view (FOV).[9] CBCT devices are divided into four subcategories:[10] dentoalveolar (FOV $<$ 8 cm); maxillomandibular (FOV 8–15 cm); skeletal (FOV 15–21 cm); and head and neck (FOV $>$ 21 cm).

### Effective radiation dose

One of the major advantages of CBCT over computed tomography (CT) is the significantly lower effective radiation dose to which patients are exposed.[9] The effective dose of CBCT scanners may vary, but it can be almost as low as that of a panoramic dental X-ray.[11–14] The dose depends on the region of the jaw to be scanned, the exposure settings of the CBCT scanner, the size of the FOV, the exposure time(s), the tube current (mA) and the energy/potential (kV)[15,16]. The radiation dose can be reduced using a smaller FOV, fewer projections (180°) and a bigger voxel size.[17,18]

For endodontic applications, the FOV should be limited to the region of interest; that is, the FOV should encompass the tooth (or teeth) under investigation and the surrounding structures. This is an effective way to reduce the radiation dose.[1] The radiation dose of a small-volume CBCT scanner is comparable to that of 2–7 standard periapical radiographs (PRs), whereas the radiation dose of a large-volume scanner is similar to that of a full-mouth series of PRs.[17,19] The tube current (mA) selected should be as low as possible, so that the image produced is of sufficient diagnostic yield even

though this may result in a degree of noise.[4] Whenever possible, the mA and exposure times should be reduced.[18] The voxel size used in CBCT is often a device-related compromise. Reducing voxel size beyond that required to produce reconstructed images of a sufficient yield should be avoided to prevent unnecessarily high radiation doses.[4]

An accepted compromise between radiation dose and image quality must be reached to adhere to the ALARA principle.[20] This is especially relevant when assessing children, who are more susceptible to the potential effects of ionizing radiation.[21] At all ages, the associated risks for women are slightly higher than those for men. Therefore, exposure of a patient to ionizing radiation must never be considered routine. Furthermore, CBCT operators must be adequately trained in CBCT radiology and in the interpretation of the images obtained, because both differ substantially from conventional radiography.[2]

### Drawbacks and limitations of cone beam computed tomography

Despite the obvious advantages that CBCT offers in dentistry, the technology has drawbacks and limitations. At present, CBCT systems have significantly lower spatial resolution than PRs (15—20 lines per mm),[22,23] but the resolution of the reconstructed scans is improving as new systems are developed.

A significant problem affecting the image quality and diagnostic accuracy of CBCT images is the scatter and beam hardening caused by high-density neighbouring structures and materials.[24,25] If the scattering and beam hardening is close to or associated with the tooth under assessment, the resulting CBCT images may be of minimal diagnostic value.[26] Crowns, bridges, implants, fillings and intracanal posts can mimic endodontic complications or hide existing ones.[27,28] Ritter et al.[28] determined the influence of patients' age, sex, body mass index, and existing dental restorations and implants on the image quality of CBCT. The authors concluded that the patient's age and the number of existing dental restorations have a negative impact on CBCT image quality. However, further studies are required to identify the factors associated with age that influence the quality of CBCT images.

## Clinical applications of cone beam computed tomography in endodontics

The radiographic examination is an essential part of endodontic management, from the initial diagnosis to the assessment of treatment outcome. CBCT overcomes several limitations of conventional radiography.[2,9,14] For example, the spatial relationship of the roots of multi-rooted teeth can be visualized in 3D[25] and the true size and 3D nature of periapical lesions can also be assessed.[1,9] CBCT technology aids the diagnosis of endodontic pathosis and root and alveolar fractures, the assessment of canal morphology, the analysis of resorptive lesions, the identification of pathosis of non-endodontic origin, the evaluation of root canal preparation and filling and the pre-surgical assessment necessary for root-end surgery.

### Evaluation of root canal anatomy and complex morphology

Anatomical variations exist with each type of tooth.[29,30] The 2D nature of PRs does not consistently reveal the true number of canals present in teeth. The interpretation of an image can be confounded not only by the anatomy of its surrounding structures but also by that of the teeth themselves. In an *ex-vivo* investigation, Matherne et al.[31] compared the ability of charge-coupled device and photostimulable phosphor plate digital radiography systems and CBCT to detect the number of root canals in 72 extracted teeth. This study found that, with digital radiography, endodontists failed to identify at least one root canal in 40% of teeth, despite using a parallax technique. However, it should be taken into account that the teeth were not sectioned to confirm the true number of root canals.

Mandibular first molars display several anatomical variations. The major variant in this type of tooth is the occurrence of a supernumerary (distolingual [DL]) root.[32,33] In rare cases, an additional root may occur at the mesiobuccal (MB) side, known as a radix paramolaris.[34] According to a recent review, the frequency of mandibular first molars with DL roots is 14.4% and ethnicity is a predisposing factor for this anatomical variation.[35] Tu et al.,[36,37] who investigated the apparent prevalence of DL roots identified with PRs and CBCT, observed prevalences of 21% and 33%, respectively. In conclusion, multiple PRs (especially the 25° mesial tube shift) or CBCT are required to assess the presence of DL roots.[35]

Complex anatomy often occurs in the mesial root of mandibular molars.[38] Few clinical studies have investigated the prevalence of an isthmus between the MB and mesiolingual canals, which can be instrumented to length.[39—42] Despite reports of a high prevalence of intercanal communications in mandibular molars,[43,44] the success rate of locating and accessing a middle mesial root canal is low, ranging from 1% to 46%.[39,40,42,45] In an *in-vitro* study, de Toubes et al.[46] compared CBCT with clinical inspection, digital radiography and operating microscope methods in the identification of middle mesial canals in mandibular first molars. Their results demonstrated that, unlike parallax digital radiography, which was deemed unreliable, there was good agreement between CBCT and the dental operating microscope in detecting accessory mesial canals.

Different studies have used CBCT to study the root canal morphology of maxillary molars.[47,48] Blattner et al.[47] assessed the prevalence of second MB canals in extracted maxillary first and second molars *in vitro*. The teeth were sectioned axially to confirm the true number of root canals. In total, an 80% correlation was reported between CBCT findings and the results obtained by tooth sectioning. Neelakantan et al.[48] compared the efficacy of six methods (modified canal staining and clearing, CBCT, peripheral quantitative CT, spiral CT, digital radiography and contrast medium-enhanced digital radiography) in identifying the root canal systems of 95 teeth. Their results showed that CBCT was as accurate as the gold standard (a modified canal-staining and clearing technique). Moreover, as in previous studies,[47,49,50] the level of interexaminer and intraexaminer agreement was significantly higher with CBCT (and the other 3D imaging systems) than with PRs.

3D reconstructions of CBCT images allow clinicians to fully appreciate the internal endodontic anatomy of the root canal

system in each type of tooth.[51–54] Prior knowledge of the number of root canals and their location results in predictable identification of all root canal orifices.[4,6,35] CBCT is also invaluable for assessing teeth with uncommon anatomy, such as teeth with an unusual number of roots, dilacerated teeth, teeth exhibiting dens invaginatus (Fig. 1), teeth with C-shaped canals and fused teeth.[5,55] However, CBCT should be reserved for select cases where the root canal anatomy cannot be fully appreciated with conventional PRs and the dental operating microscope.[4,6]

## Detection of apical periodontitis

Periapical radiolucency, detected on PRs or by reconstructed scans obtained using CBCT, is a common sign of apical periodontitis.[56,57] This lesion is commonly caused by bone resorption triggered by the host response to bacteria inside the root canal system.[58] A periapical lesion is defined as periapical radiolucency connected with the apical part of a root that exceeds at least twice the width of the periodontal ligament space.[59,60]

Bender and Seltzer[61,62] and Schwarz and Foster[63] showed that the size of the periapical lesion is often underestimated using PRs. CBCT enables the detection of radiolucent endodontic lesions before the lingual or buccal plate is demineralized.[1,2,14] Use of CBCT eliminates the superimposition of anatomical structures and is useful in identifying processes occurring within the cancellous bone.[2] Both *in-vitro*[2,64] and *in-vivo*[14,26,48,49,59,65–67] studies have shown that CBCT detects periapical lesions more effectively than PRs. Two studies[2,68] have been undertaken to investigate whether CBCT-detected lesions are true lesions. de Paula-Silva et al.[68] examined the periapical area of 83 treated or untreated roots in dogs' teeth. Each root in which a periapical lesion was present on the CBCT images but absent on the PRs was histologically determined to have periapical inflammation. These findings confirm that CBCT scans are more sensitive in detecting apical periodontitis than PRs (Fig. 2). Overall, the specificity of PRs and CBCT is 1 (100%), as corroborated by Patel et al.[2] However, a human *in-vivo* study to validate these findings by histologically assessing the periapical tissues would be unethical.[4]

Using greyscale CBCT readings, Simon et al.[69] were able to differentiate solid from cystic or cavity-type lesions in 17 teeth. However, not all the lesions were intact and no attempt was made to perform serial sectioning of the biopsy material. To date, there remains no consensus on the possibility of differentiating cysts from granulomas using CBCT imaging[70,71]; therefore, the use of CBCT is not useful in deciding whether or not to perform a periapical surgery.

Images obtained using CBCT provide the clinician with great detail and much information, allowing the presence of previously undiagnosed pathoses[66,72] or absence of odontogenic aetiology of pain[73,74] to be verified. However, no single

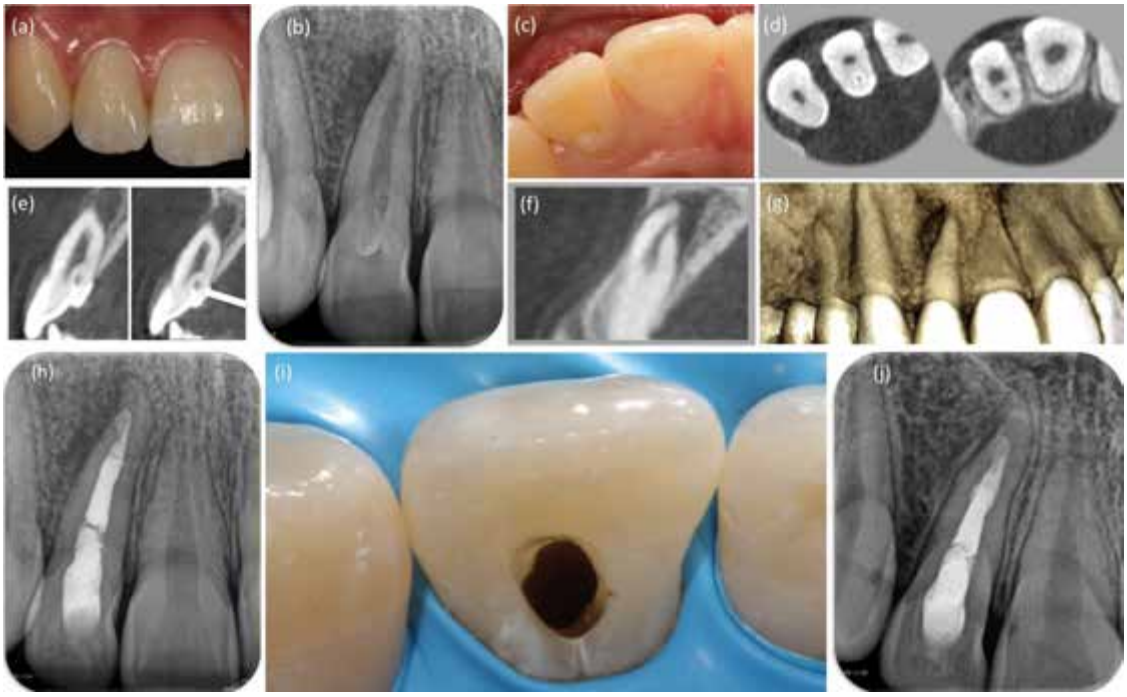


**Figure 1** (a) A healthy 16-year-old woman reported episodes of pain and swelling associated with maxillary lateral incisor (tooth 12) over the previous 3 weeks. The crown of the affected tooth was intact but somewhat wider than the bilateral tooth. (b) The tooth did not respond to thermal and electrical stimuli; periodontal probing revealed a normal periodontium. Periapical radiograph showed a mature tooth, and a lateral radiolucency could be seen. (c) A small pit evident in the palatal surface was suspected of being a dens invaginatus. (d, e) Reconstructed cone beam computed tomography (CBCT) (ProMax 3Ds; Planmeca Oy, Helsinki, Finland) images confirmed the diagnosis of a dens invaginatus. The axial and sagittal views showing the enamel-line invagination (white arrow) and the relationship between the main root canal. (f) Note the lateral exit of the root canal. (g) Three-dimensional CBCT reconstruction; buccal view. (h) Post-operative radiograph. (i) Final access opening. (j) A recall periapical radiograph taken 12 months after the initial appointment. Note the complete periapical healing.

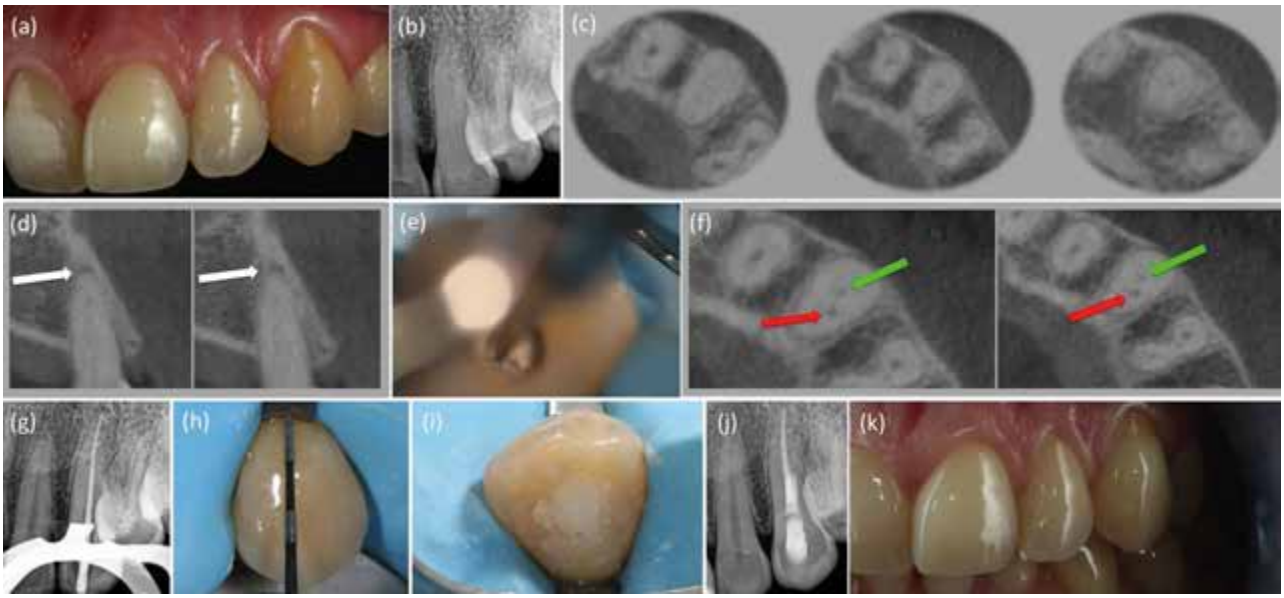


**Figure 2** (a) Pre-treatment photograph of left upper canine (tooth 23) showing a yellow-brown discoloration. (b) The tooth was sensitive to percussion, but neither sinus tract nor periodontal pocket was detected. Periapical radiograph revealed a healthy periapex and an obliterated pulp space. (c) The axial cone beam computed tomography (CBCT) (CS 9000 3D; Carestream Health, Rochester, NY, USA) images showed a visible pulp space in the middle and apical portion of the root. (d) Sagittal reconstructed CBCT images revealed a periapical lesion (white arrows). (e) Despite microscopic visualization and the use of an ultrasonic tip, the root canal was not located. (f) Intraoperative CBCT axial images helped to identify location of the root canal. The red arrow denotes the root canal deviation and the green arrow denotes the correct position of the root canal. (g) Guttapercha cone before root canal filling. (h) After root canal treatment, an intracoronal bleaching was the treatment of choice. The root filling was reduced 1—2 mm below the cementoenamel junction. (i) Sodium perborate mixed with distilled water was placed into the pulp chamber. (j) Periapical radiograph taken immediately after treatment. (k) Clinical results after 2 applications of the walking bleach technique, resulting in a slightly overbleached tooth.

test or imaging technology will provide a definitive diagnosis. A risk/benefit analysis should always be performed prior to the use of any imaging technique.[75]

## Assessment of the outcome of root canal treatment

Perhaps the most important area in which CBCT can be applied in endodontics is in determining the outcome of treatment. One advantage of CBCT is that regions or teeth to be compared over time do not need to be examined with the same projection geometry, as is the case in conventional radiography. Similarity between images in both geometry and contrast can be achieved *post hoc*.[2,9]

Earlier identification of periapical radiolucent changes using CBCT may result in earlier diagnosis and more effective management of periapical disease. Mota de Almeida et al.[74] determined whether the outcome of CBCT examinations, performed in accordance with European Commission guidelines, had an impact on endodontic diagnoses. Their results showed that CBCT had a substantial impact on diagnostic efficacy; diagnoses were changed for 28 teeth (35%).

Conventional and digital PRs have been widely used for follow-up after root canal treatment. However, in teeth with apical periodontitis, microscopic findings and radiographic examinations are often divergent.[76] Chronic periapical inflammation often persists for years after root canal filling, even in the absence of clinical symptoms and radiographic alterations.[77,78] The most recent literature demonstrates that the detection of periapical lesions following root canal treatment using CBCT is more accurate than that using radiographic evaluation.[68,79,80,67] de Paula-Silva et al.[58] evaluated periapical repair after root canal treatment in dogs' teeth using CBCT and PRs and compared these findings with the gold standard: microscopic evaluation. Six months after treatment, a favourable outcome was detected in 79% of teeth assessed with PRs, in comparison to 35% when CBCT was used.

These findings are similar to those of other studies.[67,81] Patel et al.[67] compared the radiographic change in the periapical status of individual roots using digital PRs versus CBCT 1 year after primary root canal treatment. The healed rate (no periapical radiolucency) for all roots was 92.7% using PRs and 73.9% using CBCT. This rate increased to 97.2% and 89.4%, respectively, when the healing group (periapical radiolucency of reduced size) was included. In teeth with existing pre-operative periapical radiolucencies, reconstructed CBCT images also showed more failure (13.9%) when compared with PRs (10.4%). In a retrospective longitudinal cohort study, Fernández et al.[81] evaluated the outcome of endodontic treatments as assessed by conventional and digital PRs and CBCT during a 5-year follow-up period. They suggested that CBCT was more sensitive than PRs for the visualization of periapical lesions in a long-term evaluation. In addition, it was found that the root canal curvature, failure to disinfect gutta-percha, the presence of missed canals and inadequate

definitive coronal restoration at follow-up were prognostic factors that negatively influenced the outcome of treatment. However, it was not possible to confirm whether these lesions were already present before commencement of the treatment, because no pre-treatment CBCT scans had been taken.

Liang et al.[82] compared the quality of root canal treatment using PRs and CBCT in teeth with vital pulps. They found that the treatment outcome, length and density of root fillings and outcome predictors as determined using CBCT differed from the corresponding values determined using PRs. CBCT detected periapical lesions in 25.9% of the teeth, compared with 12.6% using PRs. Root fillings with voids and unsatisfactory coronal restorations negatively influenced the outcome.

Underestimation of the size of periapical lesion by PRs relative to CBCT highlights the importance of human clinical trials to determine the mean time needed for periapical healing when assessed using CBCT, especially because recent reports have suggested that persistent or periapical disease can have an impact on both oral and general health.[83,84] It would be justifiable to use small FOV CBCT scans in clinical research trials. However, CBCT should not be used for the routine assessment of periapical disease prior to endodontic treatment.

## Pre-surgical planning

Post-treatment apical periodontitis is preferably treated by nonsurgical retreatment, unless patient preference or a risk/benefit analysis indicates the use of periapical surgery.[85] Modern surgical endodontic treatment offers easier identification of root apices, smaller osteotomies and shallower resection angles, which preserve cortical bone and root length.[85] The modern technique has a much higher success rate than the traditional technique.[86] Tsesis et al.[87] reported that modern surgical endodontic treatment yields a successful outcome rate of 89%. CBCT is particularly recommended for diagnosis and treatment planning before endodontic surgery.[1]

The benefits of the use of CBCT during endodontic surgery including elimination of the superimposition of anatomic structures, such as the zygomatic buttress, alveolar bone, maxillary sinus and other roots, and early detection of the presence and dimensions of apical lesions and changes in apical bone density.[4,14] The axial, coronal and sagittal planes obtained with CBCT scans also provide clinicians with a clear view of the anatomical relationship between root apices and neighbouring structures, such as the mandibular canal,[60] mental foramen and maxillary sinus.[65,88]

Low et al.[65] compared the radiographic findings of PRs with those of CBCT in root-treated maxillary posterior teeth under assessment for periapical surgery. CBCT identified significantly more periapical lesions (34%) than PRs, a clinically important difference. Detecting lesions with PRs alone was most difficult in second molars or in roots in close proximity to the floor of the maxillary sinus. Bornstein et al.[88] confirmed that limited CBCT imaging is a valuable diagnostic method to evaluate anatomically demanding areas, such as the posterior maxilla and maxillary sinus,

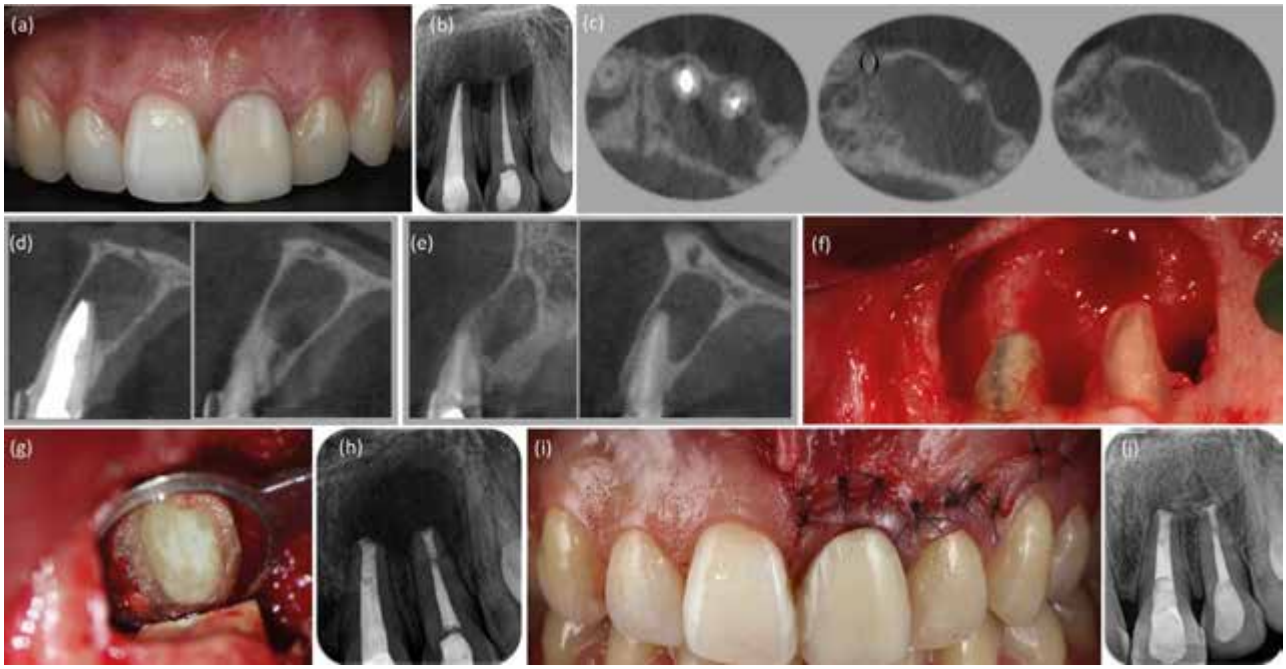


**Figure 3** (a) A clinical image of the left maxillary central and lateral incisor subjected to endodontic surgery. (b) A periapical radiograph showing an apical lesion in teeth 21 and 22. (c, d, e) A cone beam computed tomography (CBCT) scan (CS 9000 3D; Carestream Health, Rochester, NY, USA) was performed before endodontic surgery. (C) Sagittal and axial images confirmed a circumscribed apical lesion. Note that the apical lesion affected neither the buccal nor palatal cortical plates. (f) A submarginal (Ochsenbein-Luebke) flap was raised to gain access and treat the apical lesion. Final size of the osteotomy. (g) Mineral trioxide aggregate (White ProRoot MTA, Dentsply Maillefer) root-end — filled apex. (h) An immediate post-operative radiograph. No bone regeneration techniques were required. (i) The flap was repositioned and sutured tightly with 5 × 0 monofilament sutures. (j) Two-year follow-up radiograph showing almost complete healing.

before periapical surgery. Malliet et al.[89] concluded that CBCT images may allow clinicians to avoid periapical surgery for maxillary molar teeth where the floor of the sinus has been perforated by a periapical lesion that is larger than estimated, which may have not been readily detected on PRs.

The study by Bornstein et al.,[60] which was performed on mandibular molars, showed that, of 58 periapical lesions detected with sagittal CBCT sections, 15 (25.9%) were not detected with PRs. These authors also found that the distance between the apices of the first mandibular molars and the upper border of the mandibular canal was not measurable in 44 of 68 PRs (64.7%). The true size, location and extent of periapical lesions can be appreciated with CBCT and the actual root with which the lesion is associated can be confirmed.[67]

The use of CBCT imaging may be indicated for select cases when planning periapical surgery, but the decision should be based on several factors, such as proximity of the root apices to neighbouring anatomical structures,[60,88] suspicion of a missing root canal,[90] or assessment of the bony defect (e.g. apicomarginal lesions, large periapical lesions communicating with the alveolar crest and through-and-through lesions)[91] (Fig. 3).

## Assessment of vertical root fracture, resorption or perforation

Complete or incomplete vertical root fracture (VRF) develops longitudinally along the root.[92] If the root fragment has not been displaced (incomplete root fracture), root fractures may be difficult to diagnose using PRs.[93] As reported by Tsesis et al.,[94] it is difficult to reach a definitive diagnosis based on the signs and symptoms alone, because they are not specific to fractures and may be very similar to those of endodontic or periodontal disease. Meister et al.[95] suggested that VRF could only be detected directly using PRs if there is separation of the root fragment and if the fracture traverses in the direction of the X-ray beam. If the fracture is not in the plane of the beam, the clinician is forced to make interpretations based on periradicular bone loss.

Controversy surrounds the accuracy of CBCT imaging for detecting VRF. Some studies have found that CBCT imaging is more accurate than PRs. Özer[96] created fractures of known widths ranging from 0 to 0.4 mm and reported that CBCT imaging was more successful than PRs in correctly diagnosing the fractures (82% and 42%, respectively). Bernardes et al.[97] reported that, in endodontically treated teeth, CBCT imaging detected VRF in 90% of cases, whereas PRs detected VRF in only 10%. However, this study did not confirm the presence/absence of root fracture by comparison with a reference standard.

Some studies[98,99] have concluded that CBCT imaging is an unreliable method of detecting VRF, whereas others have found no differences between CBCT and PRs.[100,101] Recently, Chavda et al.[102] concluded that both CBCT and PRs had a high and comparable degree of specificity (0.92 for PRs and 0.83 for CBCT imaging) but that both exhibited low sensitivity, at 0.27 and 0.15, respectively. These results indicate that the

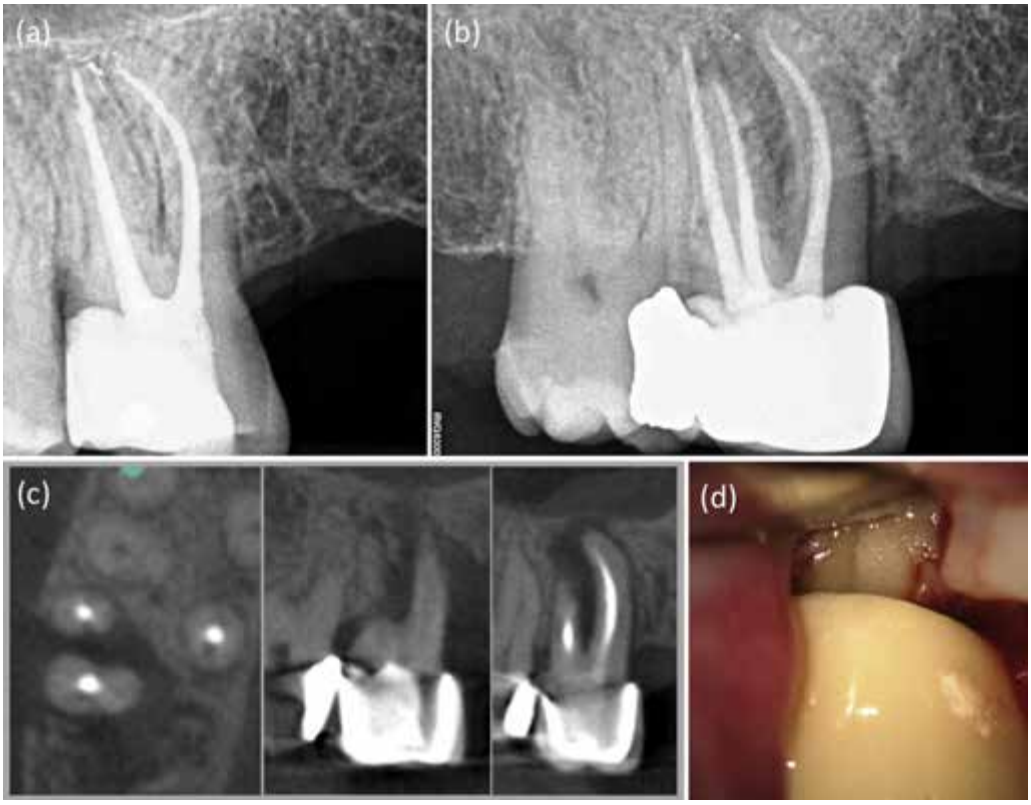


**Figure 4** Example images of a right maxillary first molar (tooth 16): (a, b) digital periapical radiographs, and (c) reconstructed axial cone beam computed tomography (CBCT) (CS 9000 3D; Carestream Health, Rochester, NY, USA) slices. The fracture was not visible on either imaging modality. (d) The suspected vertical root fracture was only confirmed during the surgical flap procedure.

likelihood of detecting a VRF is low for both modalities (Fig. 4). Therefore, CBCT imaging could be a useful adjunct to a thorough clinical examination, but this system by no means guarantees a correct diagnosis of a VRF.

Root resorption is defined as the loss of dental hard tissues as a result of osteoclastic activities.[103] It can be a physiological or a pathological phenomenon. Unlike bone, which undergoes continuous physiological remodelling throughout life, root resorption of permanent teeth does not occur naturally and is invariably inflammatory in nature. Therefore, root resorption in the permanent dentition is a pathological event; if untreated, it may result in the premature loss of the affected teeth.[104] The diagnosis of root resorption is based primarily on radiographic examination, with supplementary information gained from the history and clinical findings.[105]

Although PRs are currently the reference standard for the detection of root resorption, CBCT scans result in enhanced diagnosis of the presence and type of root resorption (Fig. 5).[103,104] *In-vitro* studies[106–109] have demonstrated the superior diagnostic accuracy of CBCT over PRs in the detection of simulated resorption cavities. Both Durack et al.[106] and Bernardes et al.[109] highlighted the ability of CBCT to detect incipient root resorption before it became identifiable using conventional radiographic systems. However, it is unclear whether voxel size affects the potential of CBCT to detect these cavities.[108,110]

Two clinical studies[111,112] also reported that CBCT is superior to PRs in identifying and determining the extent of root resorption. Patel et al.[111] found that CBCT was 100% accurate in its ability to diagnose the presence of root resorption, whereas the sensitivity of PRs was significantly lower. Therefore, this imaging modality is a suitable tool for the assessment of the true condition of teeth diagnosed with root resorption that can improve their diagnosis and aid management.

Root canal perforation is a procedural error that results in communication between the root canal walls and the periodontal space; it is capable of affecting the prognosis of endodontic retreatment (Fig. 6).[113] In phases 3 and 4 of the Toronto study,[114] the observed healed rate in teeth with a perforation was 31%, lower than in teeth without perforation.

Timely detection of perforations will aid in selecting the proper therapy, thus minimizing bone loss, and in predicting the outcome and analysing failures.[115] Radiographic detection is challenging on the labial and lingual root surface, because the image of the perforation is superimposed on that of the root. Kamburoğlu et al.[116] found that the ProMax® 3D Max CBCT scanner (Planmeca Oy, Helsinki, Finland), at all voxel sizes, is useful in determining the presence and dimensions of furcal perforations when perforation is suspected. When adequate information cannot be obtained through clinical examination and using traditional 2D techniques, CBCT imaging may help to identify fractured files, cast post deviations and perforations.[107,117] The final diagnosis and choice of clinical therapy for root perforations should always be made in conjunction with the clinical findings.

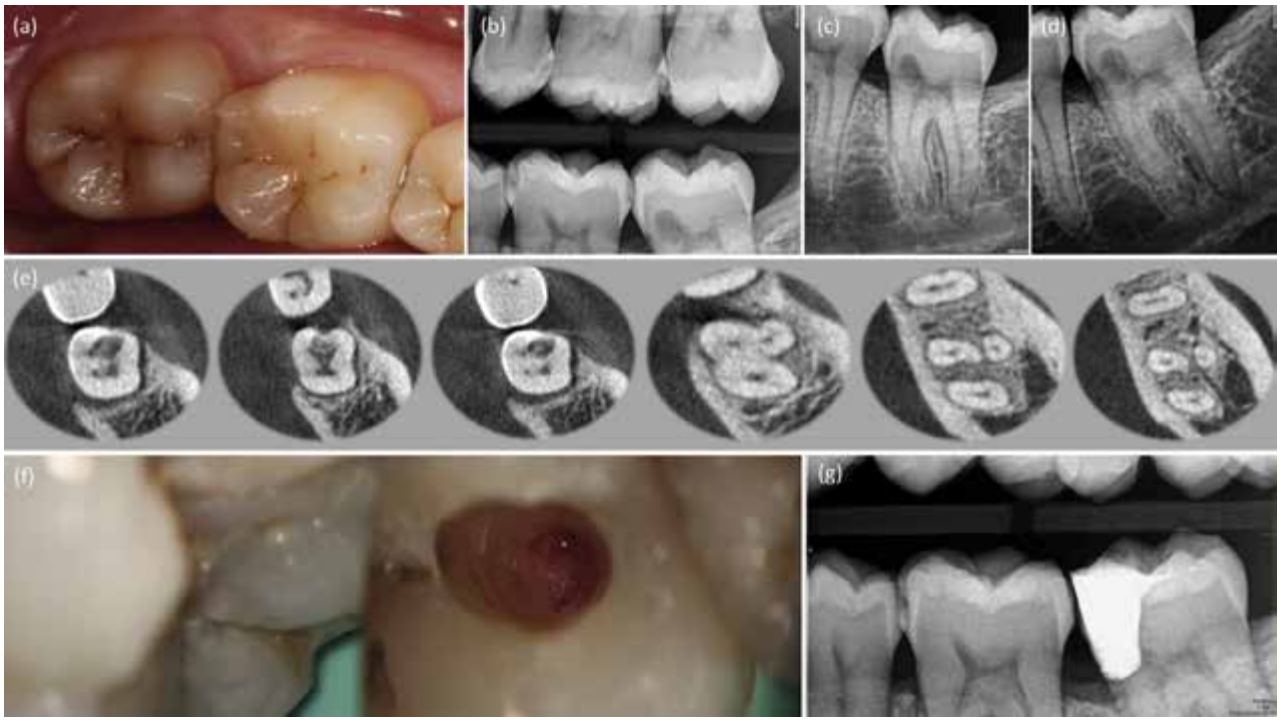


**Figure 5** (a, b) A 45-year-old woman was referred by her general dental practitioner for endodontic management of a possible external cervical resorption lesion on the tooth 37. On presentation, the patient was asymptomatic. (c, d) Periapical radiographs of tooth 37 using a paralleling technique revealed a well-circumscribed and symmetric radiolucency in the cervical aspect of the tooth. (e) Axial cone beam computed tomography (CBCT) (ProMax 3Ds; Planmeca Oy, Helsinki, Finland) slices through tooth 37 showing a radiolucency with defined margins. The resorptive lesion had not perforated into the root canal. Furthermore, axial slices allowed the relationship between a supernumerary root (distolingual) and the other roots to be assessed. (f) The external cervical lesion was treated by an internal approach. (g) A post-operative periapical radiograph.

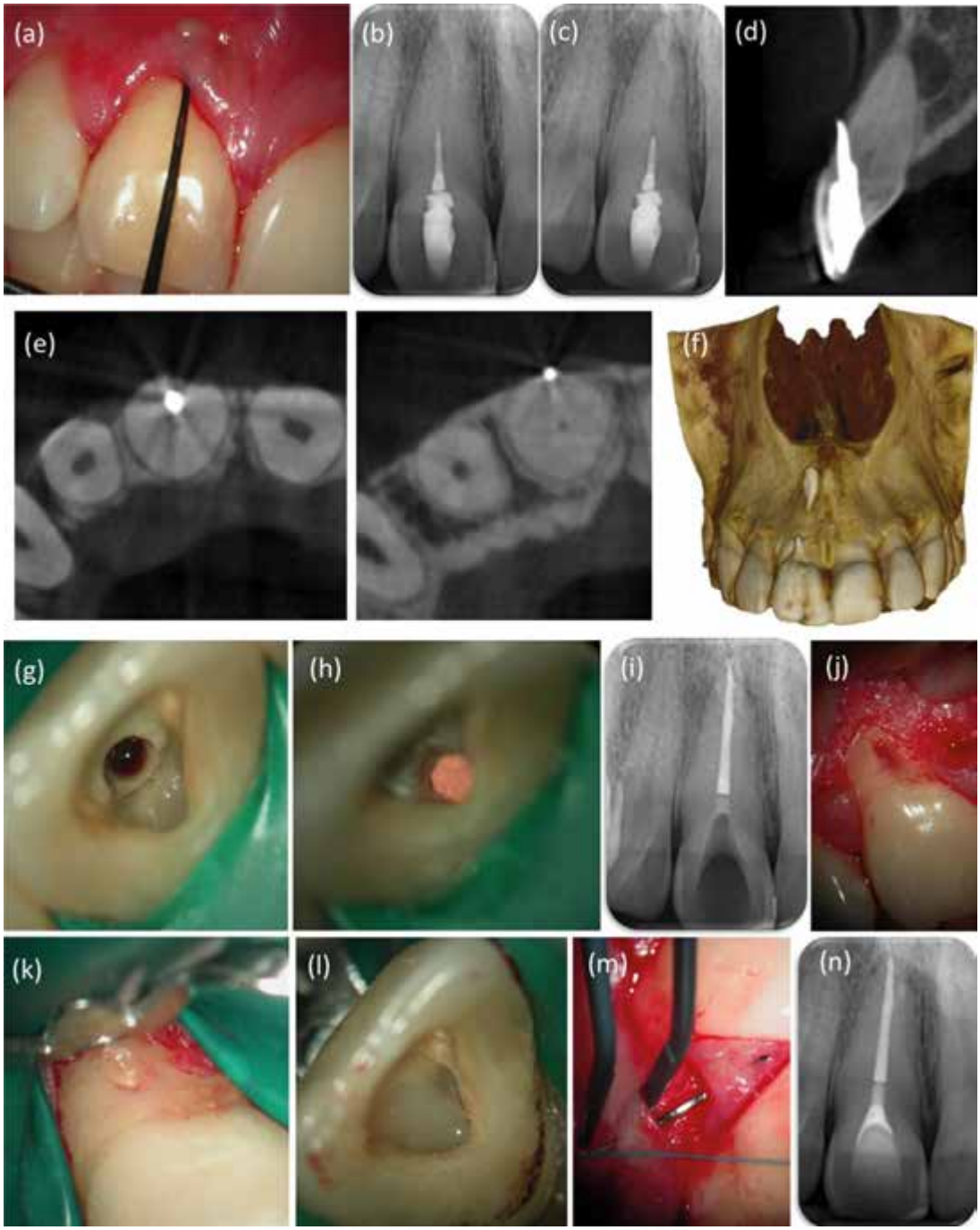


**Figure 6** (a) A 30-year-old male patient presented with a chief complaint of severe pain and swelling in the maxillary incisor region. Clinical examination revealed 5-mm-deep periodontal pocket associated with tooth 11. (b, c) Pre-operative periapical radiographs of tooth 11 with different horizontal angulations. Root perforation was suspected but could not be confirmed because of superimposition of the surrounding structures. (d, e) Cone beam computed tomography (CBCT) (CS 9000 3D; Carestream Health, Rochester, NY, USA) demonstrated a root perforation on the buccal root surface 1 mm above the alveolar crest. Sagittal reconstructed CBCT images revealed that the periapical radiolucency was larger than that seen radiographically. (f) Three-dimensional CBCT reconstruction. (g, h) An adequate access cavity to locate both the root perforation and the root canal. (i) Radiographic control after filling the root canal. (j) A papilla-base flap was raised to gain access and treat the root perforation. (k—m) Treatment attempt of the perforation included sealing with a resin-composite. (n) Two-year follow-up radiograph.

## Assessment of dental trauma

Traumatic dental injuries present a challenge to clinicians worldwide. Correct diagnosis, treatment planning and follow-up of the injury are essential and must be achieved through detailed history taking and clinical and radiographic assessment.[118] The International Association of Dental Traumatology guidelines recommend that several

projections and angles should be imaged routinely (90° horizontal angle, occlusal view and a lateral view from the mesial or distal aspect of the affected tooth)[119].

Horizontal root fractures usually affect maxillary central incisors and are typically traumatic in origin, associated with accidents, sports injuries or fights.[120] The treatment outcome for fractured teeth may be influenced by several factors, such as the degree of dislocation, stage of root formation, location of the fracture, interval between trauma and treatment, and type of dental trauma (displacement of the coronal fragment compared with no displacement of the coronal fragment).[121] One problem is that the fracture line will only be detected if the X-ray beam passes directly through it. The absence of radiographic signs when the X-ray beam is not parallel to the plane of the root fracture, tooth displacement and/or alveolar bone fracture is a limitation of intra-oral PRs.[4]

Use of CBCT allows accurate diagnosis of the presence or absence, as well as the exact location, extent and direction, of a horizontal fracture line.[122,123] The latest trauma guidelines suggest that, in addition to conventional radiography, CBCT scans may be considered for the diagnosis of horizontal root fracture.[118] Bornstein et al.[124] highlighted the relevance of CBCT to prognosis and treatment planning. As reported by May et al.,[125] there is a significant risk of misdiagnosing the location of a root fracture in anterior teeth when using intra-oral radiography, because of the possibility of an oblique course of the fracture line in the sagittal plane.

## Conclusions

Diagnostic information directly influences clinical decisions. Accurate data facilitate better treatment-planning decisions and more predictable outcomes. CBCT is an emerging technology with the potential to revolutionize the diagnosis and management of endodontic problems. An increasing number of specific applications of CBCT in endodontics are being identified as use of the technology becomes more widespread.

The benefits of a CBCT investigation must outweigh any potential risks; therefore, cases of endodontic disease should be judged on an individual basis. Until further evidence is available, CBCT should only be considered in situations where conventional imaging systems do not yield sufficient information to allow the appropriate management of the endodontic problem. The ALARA principle must be adhered to in all cases.

CBCT imaging has the potential to become the first choice for endodontic treatment planning and outcome assessment, especially when new scanners with lower radiation doses and better resolution become available. However, the currently available literature in this field is mainly limited to technical details and diagnostic accuracy (levels 1 and 2 in a hierarchical model) and, even in these areas, the information available is limited and incomplete.[75] Further clinical trials are needed to provide insight on the increased efficacy possible with endodontic applications of CBCT, especially regarding patient outcome.

Furthermore, practitioners of CBCT must be adequately trained in CBCT radiology as well as in the interpretation of the images obtained, because the modality is completely different from conventional radiography. In summary, a cautious and rational approach is advised when considering the use of CBCT imaging in endodontics.

## Conflict of interest

The authors deny any conflicts of interest.

The authors deny any financial affiliations related to this study or its sponsors.

## References


1. Cotton TP, Geisler TM, Holden DT, Schwartz SA, Schindler WG. Endodontic applications of cone-beam volumetric tomography. *J Endod* 2007;**33**:1121—32.
2. Patel S. New dimensions in endodontic imaging: part 2. Cone beam computed tomography. *Int Endod J* 2009;**42**:463—75.
3. Dailey B, Mines P, Anderson A, Sweet M. The use of cone beam computer tomography in endodontics: results of a questionnaire: 2010. AAE annual session abstract presentation PR10. *J Endod* 2010;**36**:567.
4. Patel S, Durack C, Abella F, Shemesh H, Roig M, Lemberg K. Cone beam computed tomography in Endodontics — a review. *Int Endod J* 2015;**48**:3—15.
5. Cohenca N, Shemesh H. Clinical applications of cone beam computed tomography in endodontics: a comprehensive review. *Quintessence Int* 2015;**46**:465—80.
6. European Society of Endodontology, Patel S, Durack C, Abella F, Roig M, Shemesh H, Lambrechts P, et al. European Society of Endodontology position statement: the use of CBCT in endodontics. *Int Endod J* 2014;**47**:502—4.
7. Robb RA, Sinak LJ, Hoffman EA, Kinsey JH, Harris LD, Ritman EL. Dynamic volumen imaging of moving organs. *J Med Syst* 1982;**6**:539—54.
8. Mozzo P, Procacci C, Tacconi A, Martini PT, Andreis IA. A new volumetric CT machine for dental imaging based on the cone-beam technique: preliminary results. *Eur Radiol* 1998;**8**: 1558—64.
9. Patel S, Dawood A, Whaites E, Pitt Ford T. New dimensions in endodontic imaging: part 1. Conventional and alternative radiographic systems. *Int Endod J* 2009;**42**:447—62.
10. Kau CH, Bozic M, English J, Lee R, Bussa H, Ellis RK. Cone-beam computed tomography of the maxillofacial region — an update. *Int J Med Robot* 2009;**4**:366—80.
11. Ngan DCS, Kharbanda OP, Geenty JP, Darendeliler MA. Comparison of radiation levels from computed tomography and conventional dental radiographs. *Aust Orthod J* 2003;**19**:62—75.
12. Mah JK, Danforth RA, Bumann A, Hatcher D. Radiation absorbed in maxillofacial imaging with a new dental computed tomography device. *Oral Surg Oral Med Oral Pathol Oral Radiol Endod* 2003;**96**:508—13.
13. Ludlow JB, Davies-Ludlow LE, Brooks SL. Dosimetry of two extraoral direct digital imaging devices: NewTom cone beam CT and Orthophos Plus DS panoramic unit. *Dentomaxillofac Radiol* 2003;**32**:229—34.
14. Lofthag-Hansen S, Huumonen S, Gröndahl K, Gröndahl HG. Limited cone-beam CT and intraoral radiography for the diagnosis of periapical pathology. *Oral Surg Oral Med Oral Pathol Oral Radiol Endod* 2007;**103**:114—9.
15. Suomalainen A, Kiljunen T, Käser Y, Peltola J, Kortesniemi M. Dosimetry and image quality of four dental cone beam computed tomography scanners compared with multislice computed tomography scanners. *Dentomaxillofac Radiol* 2009;**38**:367—78.
16. Pauwels R, Beinsberger J, Collaert B, Theodorakou C, Rogers J, Walker A, et al. Effective dose range for dental cone beam computed tomography scanners. *Eur J Radiol* 2012;**81**:267—71.

17. Qu X-M, Li G, Ludlow JB, Zhang ZY, Ma XC. Effective radiation dose of ProMax 3D cone-beam computerized tomography scanner with different dental protocols. *Oral Surg Oral Med Oral Pathol Oral Radiol Endod* 2010;**6**:770—6.
18. Hedesiu M, Baciut G, Nackaerts O, Jacobs R, SERDENTEXT Consortium. Comparison of cone beam CT device and field of view for the detection of simulated periapical bone lesions. *Dentomaxillofac Radiol* 2012;**7**:548—52.
19. Patel S, Dawood A, Ford TP, Whaites E. The potential applications of cone beam computed tomography in the management of endodontic problems. *Int Endod J* 2007;**40**:818—30.
20. ICRP Publication 103. The 2007 recommendations of the international commission on radiological protection. *Ann ICRP* 2007;**37**:1—34.
21. Theodorakou C, Walker A, Horner K, Pauwels R, Bogaerts R, Jacobs R, et al. Estimation of paediatric organ and effective doses from dental cone beam CT using anthropomorphic phantoms. *Br J Radiol* 2012;**85**:153—60.
22. Yamamoto K, Ueno K, Seo K, Shinohara D. Development of dento-maxillofacial cone beam X-ray computed tomography system. *Orthod Craniofac Res* 2003;**6**:160—2.
23. Farman AG, Farman TT. A comparison of 18 different X-ray detectors currently used in dentistry. *Oral Surg Oral Med Oral Pathol Oral Radiol Endod* 2005;**99**:485—9.
24. Mora MA, Mol A, Tyndall DA, Rivera E. In vitro assessment if local tomography for the detection of longitudinal tooth fractures. *Oral Surg Oral Med Oral Pathol Oral Radiol Endod* 2007;**103**: 825—9.
25. Sögur E, Baksi BG, Grondahl HG. Imaging of root canal fillings: a comparison of subjective image quality between limited cone-beam CT, storage phosphor and film radiography. *Int Endod J* 2007;**40**:179—85.
26. Estrela C, Bueno MR, Leles CR, Azevedo B, Azevedo JR. Accuracy of cone beam computed tomography and panoramic and periapical radiography for detection of apical periodontitis. *J Endod* 2008;**34**:273—9.
27. Logthag-Hansen S, Thilander-Klang A, Gröndahl K. Evaluation of subjective image quality in relation to diagnostic task for cone beam computed tomography with different fields of view. *Eur J Radiol* 2011;**80**:483—8.
28. Ritter L, Mischkowski RA, Neugebauer J, Dreiseidler T, Scheer M, Keeve E, et al. The influence of body mass index, age, implants, and dental restorations on image quality of cone beam computed tomography. *Oral Surg Oral Med Oral Pathol Oral Radiol Endod* 2009;**3**:e108—16.
29. Vertucci FJ. Root canal anatomy of the mandibular anterior teeth. *J Am Dent Assoc* 1974;**89**:369—71.
30. Kulid JC, Peters DD. Incidence and configuration of canal systems in the mesiobuccal root of maxillary first and second molars. *J Endod* 1990;**16**:311—7.
31. Matherne RP, Angelopoulos C, Kulid JC, Tira D. Use of cone-beam computed tomography to identify root canal systems in vitro. *J Endod* 2008;**34**:87—9.
32. Carabelli G. Systematisches Handbuch der Zahnheilkunde, 2nd edn. Vienna, Austria: Braumüller and Seidel; 1884: 114.
33. Bolk L. Bermerkungen über Wurzelvariationen am menschilchen unteren Molaren. *Ztg Morphol Anthropol* 1915;**17**:605—10.
34. Calberson FL, De Moor RJ, Deroose CA. The radix entomolaris and paramolaris: clinical approach in endodontics. *J Endod* 2007;**33**: 58—63.
35. Abella F, Patel S, Durán-Sindreu F, Mercadé M, Roig M. Mandibular disto-lingual roots: review and clinical management. *Int Endod J* 2012;**45**:963—78.
36. Tu MG, Tsai CC, Jou MJ, Chen WL, Chang YF, Chen SY, et al. Prevalence of three-rooted mandibular first molars among Taiwanese individuals. *J Endod* 2007;**33**:1163—6.
37. Tu MG, Huang HL, Hsue SS, Hsu JT, Chen SY, Jou MJ, et al. Detection of permanent three-rooted mandibular first molars by cone-beam computed tomography imaging in Taiwanese individuals. *J Endod* 2009;**35**:503—7.
38. Gulabivala K, Aung TH, Alavi A, Ng YL. Root and canal morphology of Burmese mandibular molars. *Int Endod J* 2001;**34**:359.70.
39. Kim Y, Perinpanayagam H, Lee JK, Yoo YJ, Oh S, Gu Y, et al. Comparison of mandibular first molar mesial root canal morphology using micro-computed tomography and clearing technique. *Acta Odontol Scand* 2015;**73**:427—32.
40. Karapinar-Kazandag M, Basrani BR, Friedman S. The operating microscope enhances detection and negotiation of accessory mesial canals in mandibular molars. *J Endod* 2010;**36**:1289—94.
41. Pomeranz HH, Edelman DL, Goldberg MG. Treatment considerations of the middle mesial canal of mandibular first and second molars. *J Endod* 1981;**7**:565—8.
42. Azim AA, Deutsch AS, Solomon CS. Prevalence of middle mesial canals in mandibular molars after guided troughing under high magnification: an in vivo investigation. *J Endod* 2015;**41**:164—8.
43. Teixera FB, Sano CL, Gomes BP, Zaia AA, Ferraz CC, Souza-Filho FJ. A preliminary in vitro study of the incidence and position of the root canal isthmus in maxillary and mandibular first molars. *Int Endod J* 2003;**36**:276—80.
44. von Arx T. Frequency and type of canal isthmuses in first molars detected by endoscopic inspection during periradicular surgery. *Int Endod J* 2005;**38**:160—8.
45. Baugh D, Wallace J. Middle mesial canal of the mandibular first molar: a case report and literature review. *J Endod* 2004;**30**: 185—6.
46. de Toubes KM, Cortes MI, Valadares MA, Fonseca LC, Nunes E, Silveira FF. Comparative analysis of accessory mesial canal identification in mandibular first molars by using four different diagnostic methods. *J Endod* 2012;**38**:436—41.
47. Blattner TC, George N, Lee CC, Kumar V, Yelton CD. Efficacy of cone-beam computed tomography as a modality to accurately identify the presence of second mesiobuccal canals in maxillary first and second molars: a pilot study. *J Endod* 2010;**36**:867—70.
48. Neelakantan P, Subbarao C, Ahuja R, Subbarao CV, Gutmann JL. Cone-beam computed tomography study of root and canal morphology of maxillary first and second molars in an Indian population. *J Endod* 2010;**36**:1622—7.
49. Abella F, Patel S, Duran-Sindreu F, Mercadé M, Bueno R, Roig M. Evaluating the periapical status of teeth with irreversible pulpitis by using cone-beam computed tomography scanning and periapical radiographs. *J Endod* 2012;**38**:1588—91.
50. Abella F, Patel S, Duran-Sindreu F, Mercadé M, Bueno R, Roig M. An evaluation of the periapical status of teeth with necrotic pulps using periapical radiography and cone-beam computed tomography. *Int Endod J* 2014;**47**:387—96.
51. Altunsoy M, Ok E, Nur BG, Aglarci AS, Gungor E, Colak M. A cone-beam computed tomography study of the root canal morphology of anterior teeth in a Turkish population. *Eur J Dent* 2014;**8**:302—6.
52. Han T, Ma Y, Yang L, Chen X, Zhang X, Wang Y. A study of the root canal morphology of mandibular anterior teeth using cone-beam computed tomography in a Chinese subpopulation. *J Endod* 2014;**40**:1309—14.
53. Yu X, Guo B, Li KZ, Zhang R, Tian YY, Wang H. Cone-beam computed tomography study of root and canal morphology of mandibular premolars in a western Chinese population. *BMC Med Imaging* 2012;**20**:12—8.
54. Abella F, Teixidó LM, Patel S, Sosa F, Duran-Sindreu F, Roig M. Cone-beam computed tomography of maxillary first and second premolars in a Spanish population. *J Endod* 2015;**41**:1241—7.
55. Venskutonis T, Plotino G, Juodzbalys G, Mickevičienė LM. The importance of cone beam computed tomography in the management of endodontics problems: a review of the literature. *J Endod* 2014;**40**:1895—901.
56. Andreasen JO, Rud J. Correlation between histology and radiography in the assessment of healing after endodontic surgery. *Int J Oral Surg* 1972;**1**:161—73.

57. Pitt Ford TR. The radiographic detection of periapical lesions in dogs. *Oral Surg Oral Med Oral Pathol* 1984;**57**:662—7.
58. de Paula-Silva FW, Santamaria Jr M, Leonardo MR, Consolaro A, da Silva LA. Cone-beam computerized tomographic, radiographic, and histologic evaluation of periapical repair in dogs' post-endodontic treatment. *Oral Surg Oral Med Oral Pathol Oral Radiol Endod* 2009;**108**:796—805.
59. Özen T, Kamburoğlu K, Cebeci AR, Yüksel SP, Paksoy CS. Interpretation of chemically created periapical lesions using 2 different dental cone-beam computerized tomography units, an intraoral digital sensor, and conventional film. *Oral Surg Oral Med Oral Pathol Oral Radiol Endod* 2009;**107**:426—32.
60. Bornstein MM, Lauber R, Sendi P, von Arx T. Comparison of periapical radiography and limited cone-beam computed tomography in mandibular molars for analysis of anatomical landmarks before apical surgery. *J Endod* 2011;**37**:151—7.
61. Bender IB, Seltzer S. Roentgenographic and direct observation of experimental lesions in bone, I. *J Am Dent Assoc* 1961;**62**: 152—60.
62. Bender IB, Seltzer S. Roentgenographic and direct observation of experimental lesions in bone, II. *J Am Dent Assoc* 1961;**62**: 708—16.
63. Schwartz SF, Foster JK. Roentgenographic interpretation of experimentally produced bone lesions. *Oral Surg Oral Med Oral Pathol* 1971;**32**:606—12.
64. Stavropoulos A, Wenzel A. Accuracy of cone beam dental CT, intraoral digital and conventional film radiography for the detection of periapical lesions. An ex vivo study in pig jaws. *Clin Oral Investig* 2007;**11**:101—6.
65. Low MTL, Dula KD, B€urgin W, von Arx T. Comparison of periapical radiography and limited cone-beam tomography in posterior maxillary teeth referred for apical surgery. *J Endod* 2008;**34**: 557—62.
66. Pigg M, List T, Petersson K, Lindh C, Petersson A. Diagnostic yield of conventional radiographic and conebeam computed tomographic images in patients with atypical odontalgia. *Int Endod J* 2011;**44**:1092—101.
67. Patel S, Wilson R, Dawood A, Foschi F, Manocci F. The detection of periapical pathosis using digital periapical radiography and cone beam computed tomography — part 2: a 1-year post-treatment follow-up. *Int Endod J* 2012;**45**:711—23.
68. de Paula-Silva FW, Wu MK, Leonardo MR, da Silva LA, Wesselink PR. Accuracy of periapical radiography and cone-beam computed tomography scans in diagnosing apical periodontitis using histopathological findings as a gold standard. *J Endod* 2009;**35**: 1009—12.
69. Simon JH, Enciso R, Malfaz JM, Roges R, Bailey-Perry M, Patel A. Differential diagnosis of large periapical lesions using cone-beam computed tomography measurements and biopsy. *J Endod* 2006;**32**:833—7.
70. Guo J, Simon JH, Sedghizadeh P, Soliman ON, Chapman T, Enciso R. Evaluation of the reliability and accuracy of using cone-beam computed tomography for diagnosing periapical cysts from granulomas. *J Endod* 2013;**39**:1485—90.
71. Rosenberg PA, Frisbie J, Lee J, Lee K, Frommer H, Kottal S, et al. Evaluation of pathologists (histopathology) and radiologists (cone beam computed tomography) differentiating radicular cysts from granulomas. *J Endod* 2010;**36**:423—8.
72. Nakata K, Naitoh M, Izumi M, Inamoto K, Ariji E. Evaluation of correspondence of dental computed tomography imaging to anatomic observation of external root resorption. *J Endod* 2009;**35**:1594—7.
73. Jiang M, You M, Wang H, Xu L. Characteristic features of the adenomatoid odontogenic tumour on cone beam CT. *Dentomaxillofac Radiol* 2014;**43**:20140016.
74. Mota de Almeida FJ, Knutsson K, Flygare L. The impact of cone beam computed tomography on the choice of endodontic diagnosis. *Int Endod J* 2015;**48**:564—72.
75. Rosen E, Taschieri S, Del Fabbro M, Beitlitum I, Tsesis I. The diagnostic efficacy of cone-beam computed tomography in Endodontics: a systematic review and analysis by a hierarchical model of efficacy. *J Endod* 2015;**41**:1008—14.
76. Barthel CR, Zimmer S, Trope M. Relationship of radiologic and histologic signs of inflammation in human root-filled teeth. *J Endod* 2004;**2**:75—9.
77. Katebzadeh N, Hupp J, Trope M. Histological periapical repair after obturation of infected root canals in dogs. *J Endod* 1999;**25**:364—8.
78. Katebzadeh N, Sigurdsson A, Trope M. Radiographic evaluation of periapical healing after obturation of infected root canals: an in vivo study. *Int Endod J* 2000;**33**:60—6.
79. Cotti E, Vargiu P, Dettori C, Mallarini G. Computerized tomography in the management and follow-up of extensive periapical lesion. *Endod Dent Trauma* 1999;**15**:186—9.
80. de Paula-Silva FW, Hassan B, Bezerra da Silva LA, Leonardo MR, Wu MK. Outcome of root canal treatment in dogs determined by periapical radiography and cone-beam computed tomography scans. *J Endod* 2009;**35**:723—6.
81. Fernández R, Cadavid D, Zapata SM, Alvarez LG, Restrepo FA. Impact of three radiographic methods in the outcome of nonsurgical endodontic treatment: a five-year follow-up. *J Endod* 2013;**39**:1097—103.
82. Liang YH, Li G, Wesselink PR, Wu MK. Endodontic outcome predictors identified with periapical radiographs and cone-beam computed tomography scans. *J Endod* 2011;**37**:326—31.
83. van der Waal SV, Lappin DF, Crielaard W. Does apical periodontitis have systemic consequences? The need for well-planned and carefully conducted clinical studies. *Br Dent J* 2015;**8**: 513—6.
84. Nair PN. On the causes of persistent apical periodontitis: a review. *Int Endod J* 2006;**39**:249—81.
85. Kim S, Kratchman S. Modern endodontic surgery concepts and practice: a review. *J Endod* 2006;**32**:601—23.
86. Tsesis I, Rosen E, Schwartz-Arad D, Fuss Z. Retrospective evaluation of surgical endodontic treatment: traditional versus modern technique. *J Endod* 2006;**32**:412—6.
87. Tsesis I, Rosen E, Taschieri S, Telishevsky Strauss Y, Ceresoli V, Del Fabbro M. Outcomes of surgical endodontic treatment performed by a modern technique: an updated meta-analysis of the literature. *J Endod* 2013;**39**:332—9.
88. Bornstein MM, Wasmer J, Sendi P, Janner SF, Buser D, von Arx T. Characteristics and dimensions of the Schneiderian membrane and apical bone in maxillary molars referred for apical surgery: a comparative radiographic analysis using limited cone beam computed tomography. *J Endod* 2012;**38**:51—7.
89. Malliet M, Bowles WR, McClanahan SL, John MT, Ahmad M. Cone-beam computed tomography evaluation of maxillary sinusitis. *J Endod* 2011;**37**:753—7.
90. Song M, Kim HC, Lee W, Kim E. Analysis of the cause of failure in nonsurgical endodontic treatment by microscopic inspection during endodontic microsurgery. *J Endod* 2011;**37**:1516—9.
91. Lin L, Chen MY, Ricucci D, Rosenberg PA. Guided tissue regeneration in periapical surgery. *J Endod* 2010;**36**:618—25.
92. Rivera EM, Walton RE. Longitudinal tooth fractures: findings that contribute to complex endodontic diagnoses. *Endod Top* 2007;**16**:82—111.
93. Wang P, Yan XB, Liu D-G, Zhang WL, Zhang ZY, Ma XC. Evaluation of dental root fracture using cone-beam computed tomography. *Chin J Dent Res* 2010;**13**:31—5.
94. Tsesis I, Rosen E, Tamse A, Taschieri S, Kfir A. Diagnosis of vertical root fracture in endodontically treated teeth based on clinical and radiographic indices: a systematic review. *J Endod* 2010;**36**: 1455—8.
95. Meister F, Lommel TJ, Gerstein H. Diagnosis and possible causes of vertical root fracture. *Oral Surg Oral Med Oral Pathol Oral Radiol Endod* 1980;**49**:243—53.

96. Özer SY. Detection of vertical root fractures of different thicknesses in endodontically enlarged teeth by cone beam computed tomography versus digital radiography. *J Endod* 2010;**36**:1245—9.
97. Bernardes RA, de Moraes IG, Húngaro Duarte MA, Azevedo BC, de Azevedo JR, Bramante CM. Use of cone-beam volumetric tomography in the diagnosis of root fractures. *Oral Surg Oral Med Oral Pathol Oral Radiol Endod* 2009;**108**:270—7.
98. Patel S, Brady E, Wilson R, Brown J, Manocci F. The detection of vertical root fractures in root filled teeth with periapical radiographs and CBCT scans. *Int Endod J* 2013;**46**:1140—52.
99. Brady E, Manocci F, Brown J, Wilson R, Patel S. A comparison of cone beam computed tomography and periapical radiography for the detection of vertical root fractures in nonendodontically treated teeth. *Int Endod J* 2014;**47**:735—46.
100. da Silveira PF, Vizzotto MB, Liedke GS, da Silveira HL, Montagner F, da Silveira HE. Detection of vertical root fractures by conventional radiographic examination and cone beam computed tomography — an in vitro analysis. *Dent Traumatol* 2013;**1**:41—6.
101. Junqueira RB, Verner FS, Campos CN, Devito KL, do Carmo AM. Detection of vertical root fractures in the presence of intracanal metallic post: a comparison between periapical radiography and cone-beam computed tomography. *J Endod* 2013;**39**:1620—4.
102. Chavda R, Manocci F, Andiappan M, Patel S. Comparing the in vivo diagnostic accuracy of digital periapical radiography with cone-beam computed tomography for the detection of vertical root fracture. *J Endod* 2014;**40**:1524—9.
103. Patel S, Pitt Ford TR. Is the resorption external or internal? *Dent Update* 2007;**34**:218—29.
104. Patel S, Ricucci D, Durack C, Tay F. Internal root resorption: a review. *J Endod* 2010;**36**:1107—21.
105. Gulabivala K, Searson LJ. Clinical diagnosis of internal resorption: an exception to the rule. *Int Endod J* 1995;**28**:255—60.
106. Durack C, Patel S, Davies J, Wilson R, Manocci F. Diagnostic accuracy of small volume cone beam computed tomography and intraoral periapical radiography for the detection of simulated external inflammatory root resorption. *Int Endod J* 2011;**44**:136—47.
107. D'Addazio PS, Campos CN, Özcan M, Teixeira HGC, Passoni RM, Carvalho ACP. A comparative study between cone-beam computed tomography and periapical radiographs in the diagnosis of simulated endodontic complications. *Int Endod J* 2011;**44**:218—24.
108. Kamburoğlu K, Kursun S. A comparison of the diagnostic accuracy of CBCT images of different voxel resolutions used to detect simulated small internal resorption cavities. *Int Endod J* 2010;**43**:798—807.
109. Bernardes RA, de Paulo RS, Pereira LO, Duarte MA, Ordinola-Zapata R, de Azevedo JR. Comparative study of cone beam computed tomography and intraoral periapical radiographs in diagnosis of lingual-simulated external root resorptions. *Dent Traumatol* 2012;**28**:268—72.
110. Neves FS, Vasconcelos TV, Vaz SL, Freitas DQ, Haiter-Neto F. Evaluation of reconstructed images of different voxel sizes of acquisition in the diagnosis of simulated external root resorption using cone beam computed tomography. *Int Endod J* 2012;234—9.
111. Patel S, Dawood A, Wilson R, Horner K, Manocci F. The detection and management of root resorption lesions using intraoral radiography and cone beam computed tomography- an in vivo investigation. *Int Endod J* 2009;**42**:831—8.
112. Estrela C, Reis Bueno M, Alencar AH, Mattar R, Valladares Neto J, Azevedo BC, et al. Method to evaluate inflammatory root resorption by using cone beam computed tomography. *J Endod* 2009;**35**:1491—7.
113. Ingle JI. A standardized endodontic technique utilizing newly designed instruments and filling materials. *Oral Surg Oral Med Oral Pathol* 1961;**14**:83—91.
114. de Chevigny C, Dao TT, Basrani BR, Marquis V, Farzaneh M, Abitbol S, et al. Treatment outcome in endodontics: the Toronto study—phase 4: initial treatment. *J Endod* 2008;**34**:258—63.
115. Alhadainy HA. Root perforations. A review of literature. *Oral Surg Oral Med Oral Pathol* 1994;**78**:368—74.
116. Kamburoğlu K, Yeta EN, Yilmaz F. An ex vivo comparison of diagnostic accuracy of cone-beam computed tomography and periapical radiography in the selection of furcal perforations. *J Endod* 2015;**41**:696—702.
117. Shemesh H, Cristescu RC, Wesselink PR, Wu M-K. The use of cone-beam computed tomography and digital periapical radiographs to diagnose root perforations. *J Endod* 2011;**4**:513—6.
118. Diangelis AJ, Andreasen JO, Ebeleseder KA, Kenny DJ, Trope M, Sigurdsson A, et al. International Association of Dental Traumatology guidelines for the management of traumatic dental injuries: 1. Fractures and luxations of permanent teeth. *Dent Traumatol* 2012;**28**:2—12.
119. Flores MT, Andersson L, Andreasen JO, Bakland LK, Malmgren B, Barnett F, et al. Guidelines for the management of traumatic dental injuries: I. Fractures and luxations of permanent teeth. *Dent Traumatol* 2007;**23**:66—71.
120. Andreasen JO, Lauridsen E, Andreasen FM. Contradictions in the treatment of traumatic dental injuries and ways to proceed in dental trauma research. *Dent Traumatol* 2010;**26**:16—22.
121. Roig M, Espona J, Mercadé M, Duran-Sindreu F. Horizontal root fracture treated with MTA, a case report with a 10-year follow-up. *Dent Traumatol* 2011;**27**:460—3.
122. Ilgüy D, Ilgüy M, Fisekcioglu E, Bayirli G. Detection of jaw and root fractures using cone beam computed tomography: a case report. *Dentomaxillofac Radiol* 2009;**38**:169—73.
123. Costa FF, Gaia BF, Umetsubo OS, Paraiso Cavalcanti MG. Detection of horizontal root fracture with small-volume cone-beam computed tomography in the presence and absence of intracanal metallic post. *J Endod* 2011;**37**:1456—9.
124. Bornstein MM, Wölner-Hansen AB, Sendi P, von Arx T. Comparison of intraoral radiography and limited cone beam computed tomography for the assessment of root-fractured permanent teeth. *Dent Traumatol* 2009;**25**:571—7.
125. May JJ, Cohenca N, Peters OA. Contemporary management of horizontal root fractures to the permanent dentition: diagnosis radiologic assessment to include cone-beam computed tomography. *J Endod* 2013;**39**(3 Suppl):S20—5.

Giornale Italiano di Endodonzia (2015) **29**, 51—57

Available online at www.sciencedirect.com

ScienceDirect

journal homepage: www.elsevier.com/locate/gie

ORIGINAL ARTICLE/ARTICOLO ORIGINALE

# Application of platelet-rich fibrin in endodontic surgery: a pilot study

*Applicazione del platelet-rich fibrin in endodonzia chirurgica: studio pilota*

**Daniele Angerame [a,*], Matteo De Biasi [b], Iva Kastrioti [a], Vittorio Franco [c], Attilio Castaldo [a], Michele Maglione [a]**

[a] *Dental Clinic, University Clinical Department of Medical, Surgical and Health Sciences, University of Trieste, Trieste, Italy*
[b] *Graduate School of Nanotechnology, University of Trieste, Trieste, Italy*
[c] *Private Practice, Rome, Italy*

Received 30 June 2015; accepted 28 July 2015
Available online 4 September 2015

**KEYWORDS**
Endodontic surgery;
Healing;
Platelet-rich fibrin;
Postoperative pain;
Swelling.

**Abstract**
*Aim:* To assess preliminarily the potential benefits of the use of the platelet-rich fibrin (PRF) in modern endodontic surgical procedures in terms of radiographic healing acceleration and postoperative discomfort reduction.
*Methodology:* Eleven patients with chronic apical periodontitis were randomly assigned to either the PRF ($n = 7$) or the control group ($n = 4$). Postoperative swelling and pain were assessed with a questionnaire. Radiographic healing was scored according to Molven's scale up to a period of one year. Data were statistically analyzed with non-parametric tests.
*Results:* In the PRF group the patients experienced less pain in the 2—6 h postoperatively as well as oedema, which never exceeded the moderate intraoral swelling. Radiographic healing was detectable earlier in the PRF group, with the majority of cases scored as complete healing after 2—3 months.
*Conclusions:* The adjunctive use of PRF might promote the acceleration of the radiographic healing and reduce the postoperative discomfort.


* Corresponding author at: University Clinical Department of Medical, Surgical and Health Sciences, Piazza Ospedale 1, I-34125, Trieste, Italy. Tel.: +39 0403992761; fax: +39 0403992665.
*E-mail:* d.angerame@fmc.units.it (D. Angerame).
Peer review under responsibility of Società Italiana di Endodonzia.

Production and hosting by Elsevier

http://dx.doi.org/10.1016/j.gien.2015.08.003

**PAROLE CHIAVE**
Endodonzia chirurgica;
Guarigione;
Platelet-rich fibrin;
Dolore postoperatorio;
Gonfiore.

**Riassunto**
*Obiettivi:* Valutare preliminarmente i potenziali benefici dell'uso del platelet-rich fibrin (PRF) nella moderna endodonzia chirurgica in termini di accelerazione della guarigione radiografica e riduzione del discomfort postoperatorio.
*Materiali e metodi:* Undici pazienti con paradentite periapicale cronica sono stati assegnati casualmente al gruppo PRF ($n = 7$) o al gruppo controllo ($n = 4$). Gonfiore e dolore postoperatori sono stati valutati con un questionario. Nell'arco di un anno di osservazione è stato assegnato un punteggio alla guarigione radiografica secondo la scala di Molven. I dati sono stati analizzati statisticamente con test non parametrici.
*Risultati:* I pazienti del gruppo PRF hanno provato meno dolore nelle 2—6 ore postoperatorie e sviluppato minor edema, che era sempre limitato e intraorale. Nel gruppo PRF la guarigione radiografica era individuabile precocemente, con la maggioranza dei casi classificata come guarigione completa dopo 2—3 mesi.
*Conclusioni:* L'uso aggiuntivo del PRF sembra promuovere l'accelerazione della guarigione radiografica e ridurre il discomfort postoperatorio.


## Introduction

Untreated pulp tissue necrosis may lead to periapical periodontitis, which represents a response of the bone around the apex to restrain the local infective offence. Periapical healing can be achieved by root canal treatment, whose purpose is to remove bacteria and remnants of infected tissue by shaping, cleaning and filling with an inert material the entire root canal system.[1] The main cause of unsuccessful periapical healing after primary endodontic therapy is the persistence of bacteria and infected tissue in the endodontic space[2] even after orthograde endodontic treatment and retreatment; in such cases, the last resort to maintain the tooth is represented by apical surgery.[3] In the choice between orthograde re-treatment and surgical approach, the latter has to be preferred when the root canal filling is adequate, but symptoms are persisting, when re-treatment involves high risk procedures or long posts are present in the root canal.[4]

Improvement in technical instruments and in surgical techniques might enhance the outcome of endodontic surgery.[5] In fact, the employment of microsurgical techniques and modern obturation materials raised the success rates after root-end resection and retrograde filling to about 80—90%.[6,7] In order to induce bone regeneration and soft tissues healing after oral surgery, the local application of hormones, grow factors and plasma derivates has been advocated.[8] Platelet-rich plasma (PRP), bone morphogenic proteins (BMPs), platelet-derived growth factor (PDGF), parathyroid hormone (PTH), and enamel matrix proteins (EMD) have been locally applied to promote the healing potential of the surgical site.[8] Nevertheless, the effectiveness of their application in endodontic surgery is still questionable and the advantages they provide to both surgeon and patient have been reported to be moderate and remain still controversial.[9—14]

It has been advocated that Platelet-rich Fibrin (PRF) can be considered a healing biomaterial because it is constituted by a fibrin network in which platelets, leukocytes, cytokines and stem cells are enmeshed.[15] Moreover, the platelets in the PRF network are capable of slowly releasing platelet-derived growth factor (PDGF) and insulin-like growth factor (IGF),[16,17] even up to one week.[18] The osteogenic potential of these molecules has been already demonstrated.[19,20] PRF can be thought as a grow factor reservoir that can be employed without exposing the patient to any immunogenicity or infection risk,[21] because it is entirely composed of nothing but the patient's blood. The application of such a specific biomaterial to endodontic surgery has already been described in some recent case reports[22—24] and a randomized clinical trial in the specifical field of the treatment of apicomarginal defects.[25]

Considering that the teeth undergoing apical surgery have less predictable prognosis and even a single tooth can be strategic in the whole oral prosthetic rehabilitation, the possibility of accelerating the bone regeneration in periapical surgical defects might be of great interest to the clinician, in order to proceed sooner with the permanent rehabilitation.

The aim of the present one-year follow-up pilot study is to evaluate the radiographic healing and the postoperative discomfort in patients undergoing apical surgery, either by leaving the apical surgical cavity empty or by filling it with the PRF gel. The null hypotheses were that periapical surgical defects filled with the PRF gel require the same healing time of sites treated by conventional surgical techniques and that the patients experienced the same postoperative discomfort with or without PRF application.

## Materials and methods

### Patient selection

In this study 11 patients underwent endodontic surgery for the treatment of refractory periapical periodontitis. The whole experimentation was conducted in accordance with the declaration of Helsinki of 1983. The patients involved were fully informed about the intent and the design of the study and they were asked to give their approval by signing a written consent.

Patients with severe systemic disorders (i.e. non-controlled diabetes, immunologic diseases, malignant neoplastic processes), thrombocytopenia or insufficient compliance were excluded from the present study. For inclusion of

**Table 1** Patients involved in the study.

| Group | Subject | Gender | Age | Tooth |
|---|---|---|---|---|
| Control group | C1 | F | 45 | 1.3 |
| | C2 | M | 72 | 4.3 |
| | C3 | F | 37 | 1.5 |
| | C4 | M | 60 | 2.3 |
| PRF test group | T1 | F | 45 | 2.5 |
| | T2 | M | 43 | 1.5 |
| | T3 | F | 44 | 1.1 |
| | T4 | F | 47 | 1.2 |
| | T5 | M | 28 | 3.6 |
| | T6 | M | 42 | 3.7 |
| | T7 | F | 52 | 3.2 |

patients, we selected adult individuals presenting a tooth with persisting periapical radiolucency, the presence of fistula and symptoms after orthograde retreatment and a high risk of jeopardize the root integrity by orthograde approach. Each patient was randomly assigned to the control group ($n = 4$) or PRF test group ($n = 7$) by simple computerized randomization procedures. Detailed information about the patients involved in the study are reported in Table 1.

## Surgical procedure

A single surgeon performed all surgical interventions under operating microscope magnification. Lidocaine with epinephrine 1:50,000 was employed as local anaesthetic. Twenty minutes were waited for the vasoactive agent to constrict the local blood vessels in order to achieve optimal haemostasis.[3] Surgical access to the apical area of the involved tooth was obtained via a full-thickness muco-gingival flap with vertical releasing incisions. The bone around the root apex was removed with a round bur mounted on a low-speed handpiece under constant water irrigation. All granulomatous tissue was removed by manual curettage. Ferric sulphate (Astringedent, Ultradent, South Jordan, UT, USA) was used as haemostatic agent. The root was sectioned 3 mm from the anatomical apex. The root-end cavity was performed by using ultrasonic tips (KiS, Spartan Obtura, Fenton, MI, USA), dried with sterile paper points (Inline, BM Dentale, Turin, Italy) and filled with SuperEba (Regular setting powder, Bosworth, Skokie, IL, USA). After the cement setting, the apical surface of the resected root was dyed with methylene blu and a surgical mirror was employed to verify the absence of visible marginal defects. At the end of root-end filling procedure the surgical site was abundantly flushed with saline to remove blood clots and ferric sulphate residuals. In the four patients of the control group, the bone defect was not filled and the flap was sutured with $5 \times 0$ and $6 \times 0$ monofilament polypropylene. In the other 7 cases (PRF test group), PRF gel was prepared as described below and applied in the bone defect before repositioning and suturing the flap (Fig. 1). Antibiotics were prescribed during the 6 days post-operatively (1 g amoxicillin every 12 h). The choice to assume analgesics was left to the patient. Sutures were removed within 48—72 h from surgery.

## PRF preparation

The PRF gel was obtained by following the protocol by Choukroun et al.[26] This consisted of collecting a small amount

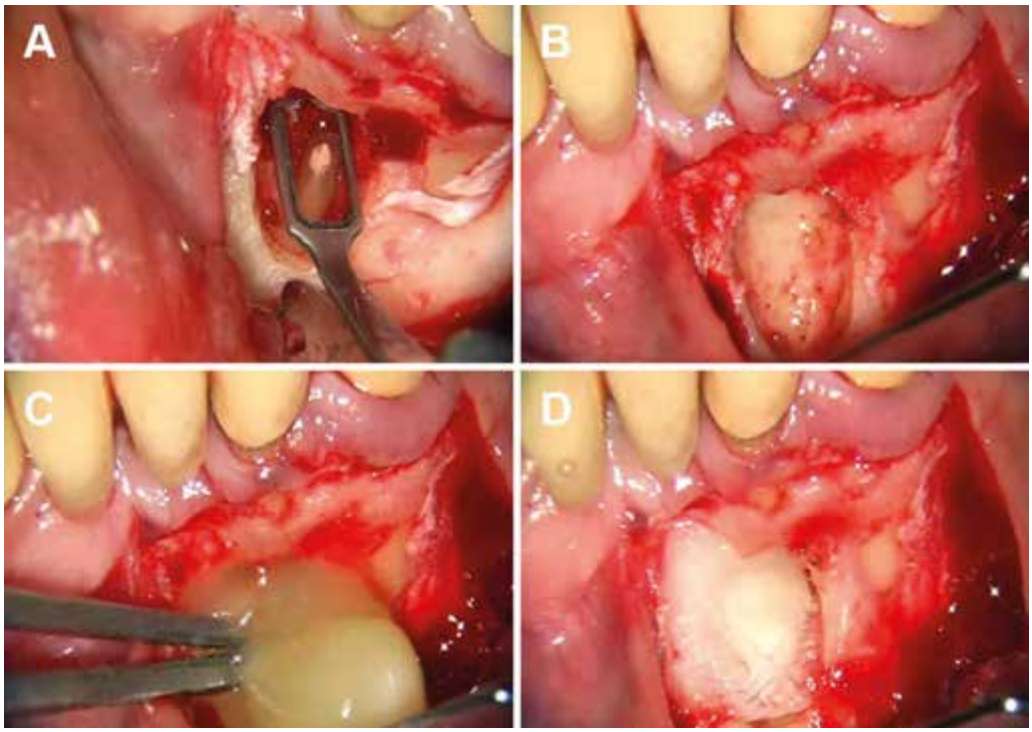


**Figure 1** Phases of the PRF gel application: (A) check of the proper seal of the retrograde filling with a surgical mirror; (B) appearance of the periapical bony defect; (C) positioning of the PRF gel in the bony defect with forceps; (D) adaptation of the gel to the defect after compression with a gauze.

of the patient's blood (10—40 mL in the case of our study) at the needed moment of the surgical operation into dried monovettes without anticoagulant agent (Vacuette, Greiner Bio-One, Kremsmünster, Austria). The collected blood was immediately centrifuged for 10 min at 2,500 rpm. The produced clot was extracted from the container by using thin sterile forceps and entirely employed, without depriving it of the red thrombus.

## Radiographic centering and examination

Customized filmholders and digital X-ray system (Vistascan Dental Perio, Dürr Dental AG, Bietigheim, Germany) were used throughout the study with a paralleling technique;[27] the X-ray device (2200 Intraoral X-Ray System, Kodak Dental Systems, Rochester, NY, USA) was set at 70 kVp, 10 mA, and 0.20 s exposure time. Radiographs were taken before and after surgery, and at each follow-up visit; recalls were planned at the 1st, 2nd, 3rd, 4th, 5th, 6th and 12th month after surgery.

Two endodontists with 16 and 20 years of clinical experience extraneous to involved patients and study design were calibrated.[28,29] All radiographs were blindly examined twice at interval of at least 30 days. Inter- and intraobserver reproducibility was assessed by means of Kappa statistics.[30] Each follow-up radiograph was assigned to the appropriate category of the classification introduced by Molven et al.:[28,29] complete, incomplete, uncertain or unsatisfactory healing (failure). Independently of the radiological periapical condition, the presence of postoperative clinical complications (e.g. sinus tract, apicomarginal communication, infection with tenderness to palpation or percussion) reported at any time of the control visits was considered as failure.

## Pain and swelling assessment

The model for subjective data collection described by Pennarocha et al.[31] was adopted. Each patient was asked to fill out a questionnaire in which pain and swelling information were recorded after 2, 6, and 12 h from the intervention, and each day during the first 7 postoperative days. Pain was rated as follows:

- 0, absence of pain;
- 1 (mild), recognizable but not discomforting pain that did not require the assumption of analgesics;
- 2 (moderate), discomforting but bearable pain that is effectively relieved by analgesics, if assumed;
- 3 (severe), pain that is difficult to bear.

The following scale was formulated to score the postoperative swelling:

- 0, absence of swelling;
- 1, minor intraoral oedema localized to the surgical site;
- 2, moderate extraoral swelling in the surgical zone;
- 3, severe extraoral swelling beyond the treated area.

## Statistical analysis

The Statistical Package for Social Sciences v. 15 (SPSS Inc., Chicago, IL, USA) was used for statistical analysis. Descriptive statistics of the considered variables were performed. The significance of the differences between the groups in terms of periapical healing, pain and swelling scores was assessed by means of a Mann-Whitney test. Since the present pilot study was conducted on a restricted number of patients, a p value less than 0.01 was regarded as statistically significant.

## Results

The distribution of the periapical healing scores is showed in Fig. 2. After the 1st radiographical recall, only one patient of the PRF test group was classified as healed by the blinded examiners and no significant differences were found between the two groups. At the recalls after 2 and 3 months from the surgical intervention, the PRF test group exhibited significantly better periapical healing scores than the control group. From that moment on, the periapical healing scores of the control and test group were similar and no significant difference was pointed out by the statistical analysis.

The graphs in Figs. 3 and 4 represent the changes in postoperative pain and swelling during the time of observation hours and days after the surgical intervention. By considering both investigated parameters, average to low scores were registered in the two groups with a trend of lower scores associated with the application of PRF. More specifically, the patients of the PRF test group felt less intense pain than the control group during the first hours and days postoperatively,

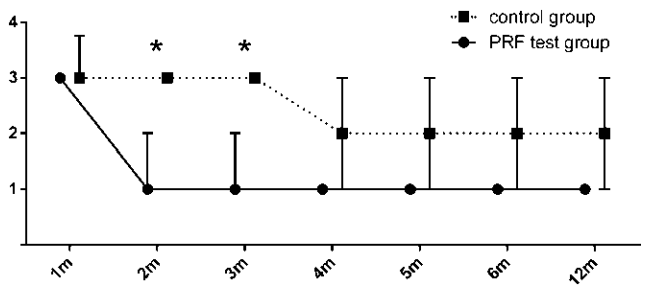


**Figure 2** Median values and interquartile ranges of periapical healing scores after months (m) from the surgical intervention: 1, complete healing; 2, incomplete healing; 3, uncertain healing; 4, unsatisfactory healing. The asterisks mark statistically significant differences between control and PRF experimental groups at the specific time point ($p < 0.01$).

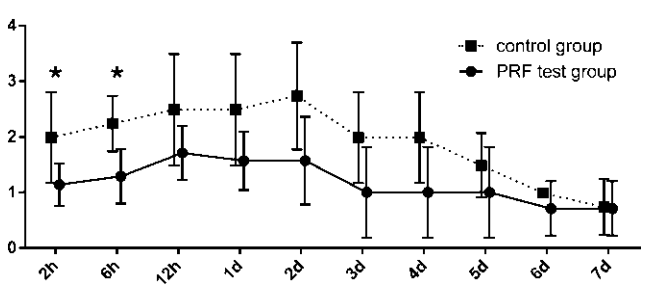


**Figure 3** Mean values and standard deviations of pain scores after hours (h) and days (d) from the surgical intervention: 0, absence of pain; 1, mild pain; 2, moderate pain; 3, severe pain. The asterisks mark statistically significant differences between control and PRF experimental groups at the specific time point ($p < 0.01$).

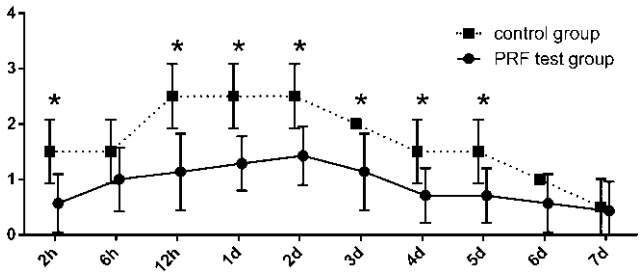


**Figure 4** Mean values and standard deviations of swelling scores after hours (h) and days (d) from the surgical intervention: 0, absence of swelling; 1, minor intraoral swelling; 2, moderate extraoral swelling; 3, severe extraoral swelling. The asterisks mark statistically significant differences between control and PRF experimental groups at the specific time point ($p < 0.01$).

with significantly lower scores after 2 and 6 h ($p < 0.01$). As to the swelling assessment, the maximum scores in both groups were reached in the time period between the 12 h and the second postoperative day. Starting from the third postoperative day, the swelling slowly decreased in both groups. The score in the PRF test group never exceeded the moderate intraoral swelling.

## Discussion

The present study evaluated the effects of the application of PRF in endodontic surgery. Similar periapical healing scores were assigned to the two groups at the first radiographic control; true to form, one month was not enough to observe mineralization changes with intraoral radiography, even in the PRF test group. On the contrary, radiographic healing in PRF test group appeared to be significantly improved after two and three months from the surgical intervention. If confirmed by studies involving a larger number of patients, such an advantage is likely to arouse the interest of the clinician, because the use of the PRF gel seems to accelerate the healing process, which was detectable earlier. In many clinical and operative situations the possibility to shorten the follow-up period to only few months before proceeding with the permanent rehabilitation would be a substantial asset. Moreover, a general trend of reduced postoperative pain and local swelling was noticed and must be considered in the management of the patient's overall comfort. In the first hours postoperatively the majority of the patients belonging to the test group experienced only mild pain (i.e. bearable without assuming drugs); this means that their use of analgesics could be limited and has both clinical and economic advantages. A clinical trial reported a beneficial effect of the use of plasma rich in growth factors (PDGF) during endodontic surgery in affecting postoperative symptoms and patient's quality of life after surgery.[32] The authors described in detail the procedure to obtain and apply this plasma concentrate to the surgical site, which required several steps to be performed, namely separating the plasmatic component in two fractions, storing them, adding $CaCl_2$ to enable clot formation and finally apply liquid and a clot of PRGF in three steps.[32] We chose to use PRF over PRGF because the former has simpler procedures for both preparation and positioning that allow to spare operative time potentially without compromising the clinical effectiveness.

One of most common indications to apical surgery is the presence of an obstruction that does not allow the access to the entire endodontic space and cannot be overcome. The orthograde techniques for overstepping the obstruction depend on the availability of specific instruments and above all on the operator's dexterity, so that they are hardly standardizeable.[4] Thus, it can be concluded that there are no absolute indications to apical surgery,[33] as they depend on a host of factors. The benefits that PRF could provide in terms of accelerated radiographic healing and limited postoperative soreness might influence the therapeutic choice.

Preferring PRF over PRP in endodontic surgery depends on several factors. Since in most cases the surgical bone defect is likely to be small, PRF, differently from PRP, would be the first choice because it requires the collection of very few milliliters of blood. PRP is obtained from the patient's own blood to whom citrate dextrose solution A is added prior to centrifuging.[34,35] PRF was specifically created for oral and maxillofacial surgery.[26] The preparation of PRF requires neither anticoagulant in the container nor addition of gelling agent (i.e. bovine thrombin).[36] The absence of anticoagulant implies the need of fast transfer and immediate centrifugation of collected blood because fibrin polymerization is not inhibited. During the first centrifugation phase, fibrinogen concentrates in the upper part of the tube; thereafter, circulating thrombin causes the slow transformation of fibrinogen into fibrin and the clot forms in the middle of the tube.[36] Red corpuscles sediment at tube's bottom, whilst acellular plasma supernatant collects at its top. The slow gelling process distinguishes PRF by PRP and other plasma derivates as it modifies the mechanical and biological characteristics of the fibrin matrix.[37] In fact, physiological thrombin concentration determines the organization of the fibrin network in a biochemical architecture characterized by trimolecular or equilateral junctions between monomers.[36] This three-dimensional structure allow the establishment of a flexible, elastic and resistant PRF gel, in which cytokines are retained and cellular migration is supported by the fibrin network.[38,39] Platelets are mainly entrapped in the clot at the interface between the fibrin clot and its lower portion (the red thrombus); thus, this portion of the plasma derivate gains in clinical relevance because of the substances it contains.[38] PRF seems also capable of enmeshing glycosaminoglycans,[38] whose affinity for circulating platelet cytokines can enhance the cell migration and the healing process.[40] Cytokines are soluble molecules that play a relevant role in healing and regeneration mechanisms in injured tissues;[38,41] their capability of regulate inflammation and healing phenomena consists of a multitude of molecular interactions that has not been completely understood and described.[39] The biologic activity and clinical effectivess of the PRF gel benefits from a partially known cytokines action. Our preliminary results highlight a trend of lower postoperative discomfort and accelerated bone healing in the patients who received the PRF gel; these findings can be indicative of a attenuated inflammatory response and enhanced healing of the surgical site. The action of healing cytokines the PRF gel contains, consists of interrupting the inflammation process or promoting angiogenesis. The effects of interleukin 4 (IL-4) profoundly depend on the cytokines environment.[42] When

inflammatory processes are present, IL-4 acts as regulator by inhibiting the IL-1β-mediated signal.[43] The most powerful agent for angiogenesis promotion is the vascular endothelial growth factor (VEGF), which can control growth, migration and differentiation of epithelial cells.[44] PRF has been defined an "immune organizing node" owing to its content in cytokines with both pro- (IL-1β, IL-6, TNF-α) and anti-inflammatory (IL-4) action, which was found to be superior than in plasma concentrates.[39]

Although cytokines and cells enmeshed in PRF fibrin network influence tissue healing, the molecular fibrin structure seems to be the crucial characteristic of PRF.[15] It is noteworthy that fibrin employed in surgery as a single agent cannot lead to sufficient bone regeneration.[45] The complex fibrin matrix of PRF can induce angiogenesis, because endothelial cells can migrate and adhere to its articulate structure in which they differentiate and proliferate.[46] Moreover, one of the main angiogenesis soluble factors, the platelet-derived growth factor (PDGF), binds to fibrin with high affinity.[47,48]

Since PRF has been introduced in recent years, only a small number of clinical studies on its efficacy have been produced; nevertheless, hopeful results have been obtained in different fields of oral surgery.[21,49–51] Some clinical case reports or series have been produced on the PRF application to endodontic surgery, with the authors generally describing reduced morbidity and discomfort for the patient and accelerated healing.[22–24] Nevertheless, no effort is made in these studies to standardize the surgical techniques or the preoperative conditions;[23] moreover, some authors make use of bone substitutes — e.g. hydroxyapatite or β-tricalcium phosphate (TCP)[22,24] — which are likely to affect the reliability of the radiographic assessment. On similar basic principles, also a case report of a single periapical lesion treated with PRP and allogenic graft (TCP) has been published.[52] The authors speculated that PRP could accelerate TCP resorption and reported a subtotal replacement of the grafting material with newly-formed bone 12 months after surgery. Since a 3-year follow up study on 146 teeth that underwent standard periapical surgery reported that 66% of treated teeth could be considered healed after 12 months,[7] the use of PRP and TCP as grafting material appears questionable at the moment. Recently, a randomized controlled trial on the surgical treatment of apicomarginal defects with PRF has been published.[25] However, endoperiodontal defects are peculiar lesions, whose treatment is known to be particularly arduous. The authors did not find significant benefit from the use of PRF. Differently, the aim of the present study was to assess the effect of PRF in endodontic lesions without periodontal communication, so it is probable that the gel can express its beneficial effect in the absence of bacterial interference from the marginal periodontum and other non-controlled factors.

Similarly to the case of periodontal regenerative therapy, bone grafting materials have been frequently employed in endodontic surgery to promote bone regeneration and their ability to induce new bone formation has been described well.[53] Notwithstanding, the risk of ankylosis after the use of a grafting material in endodontic surgery has still to be assessed because grafting materials might interfere with the regeneration of the periodontal ligament. There are no specific indications to bone grafting in periapical surgery on account of their controversial ability to provide favourable healing and because of a lack of controlled clinical trials.[53] PRF is an autologous material that surmounts problems related to graft rejection, which might occur when the source of the grafting material is allograft, alloplast or xenograft.

## Conclusions

The application of PRF gel in apical surgery showed promising result in stimulating bone formation after 2 and 3 months around periapical surgical defects and in reducing postoperative discomfort. Further clinical studies are needed to confirm the findings of this pilot study.

## Conflict of interest

The authors have no conflict of interest to declare.

## References


1. Quality guidelines for endodontic treatment: consensus report of the European Society of Endodontology. *Int Endod J* 2006;**39**: 921–30.
2. Nair PN. Pathogenesis of apical periodontitis and the causes of endodontic failures. *Crit Rev Oral Biol Med* 2004;**15**:348–81.
3. Kim S, Kratchman S. Modern endodontic surgery concepts and practice: a review. *J Endod* 2006;**32**:601–23.
4. Abramovitz I, Better H, Shacham A, Shlomi B, Metzger Z. Case selection for apical surgery: a retrospective evaluation of associated factors and rational. *J Endod* 2002;**28**:527–30.
5. von Arx T, Penarrocha M, Jensen S. Prognostic factors in apical surgery with root-end filling: a meta-analysis. *J Endod* 2010;**36**: 957–73.
6. von Arx T. Failed root canals: the case for apicoectomy (periradicular surgery). *J Oral Maxillofac Surg* 2005;**63**:832–7.
7. Maddalone M, Gagliani M. Periapical endodontic surgery: a 3-year follow-up study. *Int Endod J* 2003;**36**:193–8.
8. Bashutski JD, Wang HL. Periodontal and endodontic regeneration. *J Endod* 2009;**35**:321–8.
9. Ingle JI, Backland LK. Endodontics, 6th ed. Ontario, Canada: BC Decker; 2008.
10. Cohen S, Hargreaves KM. Pathways of the pulp. St. Louis, 9th ed. 2006.
11. Giannobile WV, Somerman MJ. Growth and amelogenin-like factors in periodontal wound healing. A systematic review. *Ann Periodontol* 2003;**8**:193–204.
12. Nevins M, Giannobile WV, McGuire MK, Kao RT, Mellonig JT, Hinrichs JE, et al. Platelet-derived growth factor stimulates bone fill and rate of attachment level gain: results of a large multicenter randomized controlled trial. *J Periodontol* 2005;**76**:2205–15.
13. Jung RE, Glauser R, Scharer P, Hammerle CH, Sailer HF, Weber FE. Effect of rhBMP-2 on guided bone regeneration in humans. *Clin Oral Implants Res* 2003;**14**:556–68.
14. Heijl L, Heden G, Svardstrom G, Ostgren A. Enamel matrix derivative (EMDOGAIN) in the treatment of intrabony periodontal defects. *J Clin Periodontol* 1997;**24**:705–14.
15. Choukroun J, Diss A, Simonpieri A, Girard MO, Schoeffler C, Dohan SL, et al. Platelet-rich fibrin (PRF): a second-generation platelet concentrate, Part V: Histologic evaluations of PRF effects on bone allograft maturation in sinus lift. *Oral Surg Oral Med Oral Pathol Oral Radiol Endod* 2006;**101**:299–303.
16. Clausen C, Hermund NU, Donatsky O, Nielsen H, Osther K. Homologous activated platelets stimulate differentiation and

proliferation of primary human bone cells. *Cells Tissues Organs* 2006;**184**:68—75.
17. Ferreira CF, Carriel Gomes MC, Filho JS, Granjeiro JM, Oliveira Simoes CM, Magini Rde S. Platelet-rich plasma influence on human osteoblasts growth. *Clin Oral Implants Res* 2005;**16**: 456—60.
18. Dohan Ehrenfest DM, de Peppo GM, Doglioli P, Sammartino G. Slow release of growth factors and thrombospondin-1 in Choukroun's platelet-rich fibrin (PRF): a gold standard to achieve for all surgical platelet concentrates technologies. *Growth Factors* 2009;**27**:63—9.
19. Devescovi V, Leonardi E, Ciapetti G, Cenni E. Growth factors in bone repair. *Chir Organi Mov* 2008;**92**:161—8.
20. Kawai M, Rosen CJ. Insulin-like growth factor-I and bone: lessons from mice and men. *Pediatr Nephrol* 2009;**24**:1277—85.
21. Jang ES, Park JW, Kweon H, Lee KG, Kang SW, Baek DH, et al. Restoration of peri-implant defects in immediate implant installations by Choukroun platelet-rich fibrin and silk fibroin powder combination graft. *Oral Surg Oral Med Oral Pathol Oral Radiol Endod* 2010;**109**:831—6.
22. Hiremath H, Motiwala T, Jain P, Kulkarni S. Use of second-generation platelet concentrate (platelet-rich fibrin) and hydroxyapatite in the management of large periapical inflammatory lesion: a computed tomography scan analysis. *Indian J Dent Res* 2014;**25**:517—20.
23. Singh S, Singh A, Singh R. Application of PRF in surgical management of periapical lesions. *Natl J Maxillofac Surg* 2013;**4**:94—9.
24. Jayalakshmi KB, Agarwal S, Singh MP, Vishwanath BT, Krishna A, Agrawal R. Platelet-rich fibrin with beta-tricalcium phosphate-a noval approach for bone augmentation in chronic periapical lesion: a case report. *Case Rep Dent* 2012;**2012**:902858.
25. Dhiman M, Kumar S, Duhan J, Sangwan P, Tewari S. Effect of platelet-rich fibrin on healing of apicomarginal defects: a randomized controlled trial. *J Endod* 2015;**41**:985—91.
26. Choukroun J, Adda F, Schoeffel C, Vervelle A. Una opportunitè en paro-implantologie: le PRF. *Implantodontie* 2001;**42**:55—62.
27. Forsberg J, Halse A. Periapical radiolucencies as evaluated by bisecting-angle and paralleling radiographic techniques. *Int Endod J* 1997;**30**:115—23.
28. Molven O, Halse A, Grung B. Observer strategy and the radiographic classification of healing after endodontic surgery. *Int J Oral Maxillofac Surg* 1987;**16**:432—9.
29. Molven O, Halse A, Grung B. Incomplete healing (scar tissue) after periapical surgery — radiographic findings 8 to 12 years after treatment. *J Endod* 1996;**22**:264—8.
30. Brunette DM. Critical thinking: understanding and evaluating dental research. Hanover Park, IL; 1996.
31. Penarrocha M, Garcia B, Marti E, Balaguer J. Pain and inflammation after periapical surgery in 60 patients. *J Oral Maxillofac Surg* 2006;**64**:429—33.
32. Del Fabbro M, Ceresoli V, Lolato A, Taschieri S. Effect of platelet concentrate on quality of life after periradicular surgery: a randomized clinical study. *J Endod* 2012;**38**:733—9.
33. Kang M, In Jung H, Song M, Kim SY, Kim HC, Kim E. Outcome of nonsurgical retreatment and endodontic microsurgery: a meta-analysis. *Clin Oral Investig* 2015;**19**:569—82.
34. Sanchez AR, Sheridan PJ, Kupp LI. Is platelet-rich plasma the perfect enhancement factor? A current review. *Int J Oral Maxillofac Implants* 2003;**18**:93—103.
35. Nikolidakis D, Jansen JA. The biology of platelet-rich plasma and its application in oral surgery: literature review. *Tissue Eng Part B Rev* 2008;**14**:249—58.
36. Dohan DM, Choukroun J, Diss A, Dohan SL, Dohan AJ, Mouhyi J, et al. Platelet-rich fibrin (PRF): a second-generation platelet concentrate, Part I: Technological concepts and evolution. *Oral Surg Oral Med Oral Pathol Oral Radiol Endod* 2006;**101**:e37—44.
37. Mosesson MW, Siebenlist KR, Meh DA. The structure and biological features of fibrinogen and fibrin. *Ann N Y Acad Sci* 2001;**936**: 11—30.
38. Dohan DM, Choukroun J, Diss A, Dohan SL, Dohan AJ, Mouhyi J, et al. Platelet-rich fibrin (PRF): a second-generation platelet concentrate, Part II: Platelet-related biologic features. *Oral Surg Oral Med Oral Pathol Oral Radiol Endod* 2006;**101**:e45—50.
39. Dohan DM, Choukroun J, Diss A, Dohan SL, Dohan AJ, Mouhyi J, et al. Platelet-rich fibrin (PRF): a second-generation platelet concentrate, Part III: Leucocyte activation: a new feature for platelet concentrates? *Oral Surg Oral Med Oral Pathol Oral Radiol Endod* 2006;**101**:e51—5.
40. Clark RA. Fibrin and wound healing. *Ann N Y Acad Sci* 2001;**936**: 355—67.
41. Giannobile WV. Periodontal tissue engineering by growth factors. *Bone* 1996;**19**:23S—37S.
42. Keegan AD, Zamorano J. Regulation of gene expression, growth, and cell survival by IL-4: contribution of multiple signaling pathways. *Cell Res* 1998;**8**:1—13.
43. Hayashi Y, Kobayashi M, Kuwata H, Atsumi G, Deguchi K, Feng Wei X, et al. Interferon-gamma and interleukin 4 inhibit interleukin 1beta-induced delayed prostaglandin E(2)generation through suppression of cyclooxygenase-2 expression in human fibroblasts. *Cytokine* 2000;**12**:603—12.
44. Ruhrberg C. Growing and shaping the vascular tree: multiple roles for VEGF. *Bioessays* 2003;**25**:1052—60.
45. Jung RE, Schmoekel HG, Zwahlen R, Kokovic V, Hammerle CH, Weber FE. Platelet-rich plasma and fibrin as delivery systems for recombinant human bone morphogenetic protein-2. *Clin Oral Implants Res* 2005;**16**:676—82.
46. Dvorak HF, Harvey VS, Estrella P, Brown LF, McDonagh J, Dvorak AM. Fibrin containing gels induce angiogenesis. Implications for tumor stroma generation and wound healing. *Lab Investig* 1987;**57**:673—86.
47. Feng X, Clark RA, Galanakis D, Tonnesen MG. Fibrin and collagen differentially regulate human dermal microvascular endothelial cell integrins: stabilization of alphav/beta3 mRNA by fibrin1. *J Investig Dermatol* 1999;**113**:913—9.
48. Sahni A, Odrljin T, Francis CW. Binding of basic fibroblast growth factor to fibrinogen and fibrin. *J Biol Chem* 1998;**273**:7554—9.
49. Simonpieri A, Choukroun J, Del Corso M, Sammartino G, Dohan Ehrenfest DM. Simultaneous sinus-lift and implantation using microthreaded implants and leukocyte- and platelet-rich fibrin as sole grafting material: a six-year experience. *Implant Dent* 2011;**20**:2—12.
50. Toffler M, Toscano N, Holtzclaw D. Osteotome-mediated sinus floor elevation using only platelet-rich fibrin: an early report on 110 patients. *Implant Dent* 2010;**19**:447—56.
51. Mazor Z, Horowitz RA, Del Corso M, Prasad HS, Rohrer MD, Dohan Ehrenfest DM. Sinus floor augmentation with simultaneous implant placement using Choukroun's platelet-rich fibrin as the sole grafting material: a radiologic and histologic study at 6 months. *J Periodontol* 2009;**80**:2056—64.
52. Demiralp B, Keceli HG, Muhtarogullar M, Serper A, Demiralp B, Eratalay K. Treatment of periapical inflammatory lesion with the combination of platelet-rich plasma and tricalcium phosphate: a case report. *J Endod* 2004;**30**:796—800.
53. Lin L, Chen MY, Ricucci D, Rosenberg PA. Guided tissue regeneration in periapical surgery. *J Endod* 2010;**36**:618—25.

Giornale Italiano di Endodonzia (2015) **29**, 58—64

Available online at www.sciencedirect.com

ScienceDirect

journal homepage: www.elsevier.com/locate/gie

ORIGINAL ARTICLE/ARTICOLO ORIGINALE

# Conditioning of root canal anatomy on static and dynamics of nickel-titanium rotary instruments

## *Condizionamento dell'anatomia canalare sulla statica e la dinamica degli strumenti rotanti in Nichel-Titanio*

**Italo Di Giuseppe [a,*], Davide Di Giuseppe [b], Vito Antonio Malagnino [c], Enrico Paolo Silla [d], Francesco Somma [d]**

[a] *Private Practitioner in Rome, Italy*
[b] *Mechanical Engineer in Rome, Italy*
[c] *Department of Endodontics, School of Dentistry, University of Chieti "G. D'Annunzio", Chieti, Italy*
[d] *Facoltà di Medicina e Chirurgia, Università Cattolica del Sacro Cuore, Largo Francesco Vito, 1, 00168 Roma (RM), Italy*

Received 10 July 2015; accepted 28 July 2015
Available online 4 October 2015

**KEYWORDS**
Ni-Ti rotary instruments;
Rotary translation;
Roughness;
Torque;
Torsional stress.

**Abstract**
*Aim:* Aim of this study is to analyze the real movement, influenced by anatomical difficulties, of nickel-titanium rotary instruments within root canal systems; then the objective is to point out the physical and geometrical characteristics of an ideal instrument, able to overcome the most complex anatomies.
*Methodology:* At first, observation of the behavior of nickel-titanium rotary instruments within root canal systems and of the influence on them of root canal anatomy. Then, attempt to avoid the anatomical obstructions exploiting, with manual rotation, the advantages of a zero/low torque.

* Corresponding author at: Italo Di Giuseppe, Largo Maresciallo Diaz, 10—00135 Roma, Italy. Tel.: +39 063336787; fax: +39 063330093.
*E-mail:* studiodigiuseppe2@virgilio.it (I. Di Giuseppe).
Peer review under responsibility of Società Italiana di Endodonzia.

Production and hosting by Elsevier

http://dx.doi.org/10.1016/j.gien.2015.08.004

*Results:* Given that, in some root canals the severity of the curves prevents instruments to advance in rotation, we obtained significant results by manually advancing and rotating NiTi rotary instruments.
*Conclusions:* Therefore, in some cases, we would need an instrument that can reconcile efficiency with a reduction of mass and torque; the ideal instrument should have a very contained working part, combining efficiency with the decrease of mass and, consequently, of torsional stresses too.


**PAROLE CHIAVE**
Roto-traslazione;
Rugosità;
Stress torsionale;
Strumenti rotanti in Ni-Ti;
Torque.

**Riassunto**
*Obiettivi:* obiettivo di questo studio è di registrare il reale movimento degli strumenti, condizionato dalle difficoltà anatomiche, all'interno dei sistemi endocanalari, per poi tentare di evidenziare le caratteristiche fisiche e geometriche dello strumento ideale, impegnato ad affrontare le anatomie più complesse.
*Materiali e Metodi:* in un primo momento: osservazione del comportamento delle lime endodontiche meccaniche in Ni-Ti all'interno dei sistemi canalari e del condizionamento che l'anatomia canalare ha su di esse. In seguito: tentativo di eludere l'impedimento anatomico sfruttando, con la rotazione manuale, i vantaggi di un torque nullo-basso.
*Risultati:* premesso che in alcuni canali la severità delle curve impedisce agli strumenti di avanzare in rotazione, si sono ottenuti risultati significativi facendo avanzare e ruotare gli strumenti manualmente.
*Conclusioni:* alla luce di queste considerazioni, in alcuni casi avremmo bisogno di uno strumento che possa conciliare l'efficienza con una diminuzione di massa e torque. L'ideale sarebbe trovare uno strumento con parte lavorante molto contenuta e che coniughi, quindi, l'efficienza alla diminuzione della massa e di conseguenza anche dello stress torsionale.


## Introduction

Anatomical complexities submit nickel-titanium (Ni-Ti) rotary instruments to stresses that often undermine their structural integrity. Despite an extraordinary development of Ni-Ti in more than 20 years of utilization, the increased risk of a separation remains a significant problem for many clinicians.[1] Many variable might contribute to this fracture, but the two main causes are cyclic fatigue and torsional fatigue, both of which might contribute to fracture, depending on canal curvature, instrument geometry and manufacturing method.[2–4] Torsional fracture occurs when an instrument tip or another part of the instrument is locked in a canal, while the shank continues to rotate and the elastic limit of the metal is exceeded[1,5]; instruments fractured by fatigue do not bind in the canal but they rotate freely around a curve, generating tension/compression cycles at the point of maximum flexure until fracture occurs.[6] Many fracture simulation studies on Ni-Ti instruments have been conducted separately from cyclic fatigue and torsional failure tests.[7,8] Only a few studies have tried to correlate these two factors of fracture.[9–12]

The endodontic handpiece imparts to the instruments a rotary motion around an axis (axis of the handpiece). When the apical portion of an instrument is inserted into a curvature, this portion will rotate around a new and different axis (axis of the canal after the curvature); this rotational motion around a new axis is the result of two actions; the first due to the structural continuity of the instrument which tends to transfer, to its portion inserted into the curvature, the same rotary motion imprinted by the endodontic handpiece to the portion of instrument in direct contact with the endodontic handpiece itself (rotation motion around the axis of the handpiece); the second due to the root canal walls, which, opposing the penetration of the instrument inserted into the curvature, exert on it pressing forces (this portion of instrument, in fact, attempts to rotate around the axis of the handpiece, but "slams" on root canal walls). The resultant of these two actions will rotate the portion of instrument inserted into the curvature around a new axis (axis of the canal after the curvature). To appreciate this rotation around a new and different axis, a rotary instrument can be put in rotation on a glass plate, in order to simulate a true rotation in a root canal with a high degree of curvature; a rotary-translation of the bent portion of the instrument can be observed; this would be impossible to value if root canal walls were present.[1]

Even when on the handpiece is not set any torque, once the instrument is inserted in the root canal, on it act forces (conditioning of the root canal walls) that flex it and give it the same root canal's shape.

Pressing forces exerted by root canal walls, if on one hand deviate the axis of rotation of the portion on instrument inserted in the curvature, on the other cause the increasing of friction forces that oppose the rotation and the advancement of the instrument. In vivo, when the curvatures are more than one, this phenomenon happens at every curve. Pressing forces (frictional forces), increase, up to the result of the inability to rotate and/or advance the endodontic file.

Today we have particularly efficient instruments that, cutting a lot, advance until reaching the apical foramen

[1] https://www.youtube.com/watch?v=RkGOftLEv1g.

(easily, most of the time). Therefore, the problem of the torsion is removed and instruments seems to break only for accumulation of cyclic fatigue. In fact, studies have found cyclic fatigue to be the primary cause of instrument fracture. It accounted for 50–90% of the mechanical failures.[13] However, it is unlikely that cyclic fatigue can occur if a rotating instrument does not significantly contact canal walls. Consequently, cyclic fatigue is not necessarily the main reason for instrument failure.[1] These considerations bring renewed emphasis on torsional stress as cause of fracture: there is torsion, more or less significant, whenever there is a curvature. However, the underlying physical principles of rotary root canal instrumentation are not fully understood nor researched; likewise, there is no concise norm for cyclic fatigue tests.[1]

The aim of this study is to highlight the behavior of Ni-Ti rotary files inside root canals and bring back the attention on torsional stress, partially forgotten since the cutting ability allows instruments to rapidly advance and gain the apex.

## Materials and methods

As already mentioned, pressing forces generate frictional forces, which oppose the relative motion of rotation and advancement of the endodontic instruments. These frictional forces are much stronger than the greater are the forces that press one surface on the other and the greater is the roughness of the two surfaces in contact. Formula of sliding friction force:

$$F\underline{a} = \mu \times Fp$$

where F$\underline{a}$ is the force of friction, $\mu$ is the coefficient of friction (static or dynamic) which is directly proportional to the roughness of surfaces in contact; Fp is the pressing force.

The relationships, which describe the forces acting on the instrument according with the curvature that it assumes in its various points are expressed below, where: $E$ is the Young's modulus of the material, $I$ is its moment of inertia, $P$ is the force that exert the walls, $x$ is the distance between the point of application of force and any point X of the instrument, $d^2v/dx^2$ is the curvature (that is the inverse of the radius of curvature) at a point $x$, $M(x)$ is the flexing moment at a point $x$ (i.e. the force $P$ per the arm $x$), $v(x)$ is the displacement compared to the 'axis of the handpiece of a point $x$ of the instrument, theta ($x$) is the angle between the axis of the instrument and the axis of the handpiece at a point X. Fig. 1 shows a section of the instrument, forces exerted by walls are radial.

Flexing moment in $x$:

$$Mx = Px$$

$$\frac{d^2v(x)}{dx^2} = \frac{Px}{EI}$$

$$\frac{dv(x)}{dx} = \frac{Px^2}{2EI} + C1$$

$$v(x) = \frac{Px^3}{6EI} + C1x + C2$$

In the point of load application:

$$v0 = \frac{1PL^3}{3EI}$$

$$\theta 0 = \frac{1PL^2}{2EI}$$

Formulas show that in a point X of the instrument the curvature-shape, taken by the instrument, is greater how much is the force ($P$) exerted by root canal walls.

We observe that endodontic instruments made of particular Ni-Ti alloys (more "malleable" after thermal and mechanical treatments), after a rotation in a root canal with particularly severe curvatures, appear deformed by torsion after the impact with canal walls. A "softer" instrument when takes contact with root canal walls during the rotation tends to deform, losing "roughness"; so it has certainly a greater ability to advance, but a smaller cutting capacity. As well, a less malleable instrument, which does not tend to deform in contact with root canal walls, will be more efficient, but will accumulate rapidly torsion fatigue. Endodontic instruments with superior cutting ability and untreated Ni-Ti alloys (harder), non-deformable in contact with root canal walls, in analog angles undergo smaller deformations and, in one sense, less report the presence of natural torsional stress. The latter are more cleansing, the first deform and make minor cleansing, burnishing but less cutting, root canal walls: so the instrument will reach the apical foramen, but organic and inorganic debris will be coated on the walls. In fact, we know that the most efficient cleaning is obtained by the cutting action of the endodontic instruments.[14]

We noticed that in some complex root canal anatomies (Figs. 2 and 3), inside of which, in mechanical rotation, endodontic files appear to be rejected and, in manual rotation, they could cover the entire canal length. By using rotary Ni-Ti instruments manually, we apply minimum values of torque and angular acceleration, often allowing the endodontic file to overcome the anatomical obstacle (Figs. 4–6). With manual rotation the change of axis of rotation starts in a less abrupt and more gradual way. The light push toward apical direction, contextual to manual rotation, compatibly

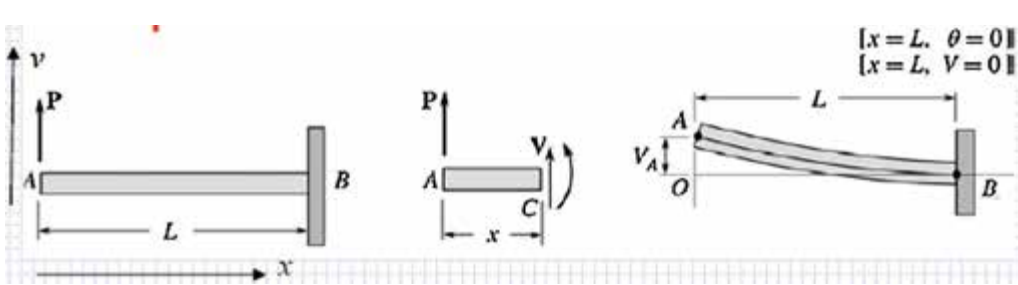


**Figure 1** Free-fixed beam.

**Figure 2** Initial RX, showing the necessity of a root canal treatment on 1.7. Apparent resorption of DB root.

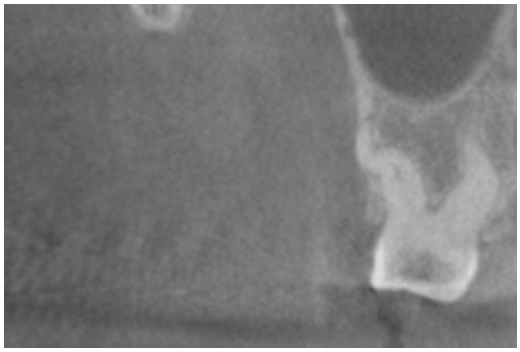

**Figure 3** CB-CT image showing the S-shaped anatomy of DB root.

**Figure 4** Final RX, filling of root canal system of 1.7.

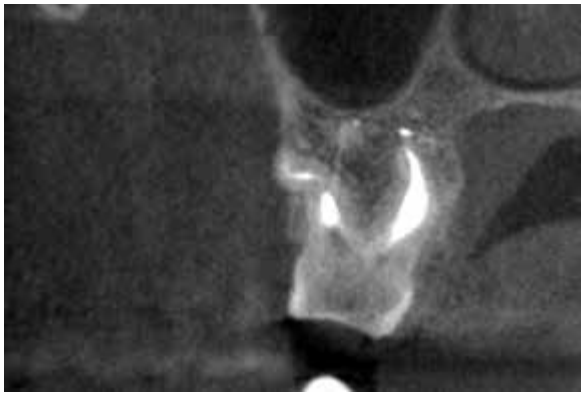

**Figure 5** CB-CT images showing how the S-shaped anatomy of DB root has been entirely cleaned, shaped (with Ni-Ti rotary instruments used in manual rotation), then filled.

**Figure 6** 3D image of the filled root canal systems.

**Figure 7** Initial RX of 4.6.

with size and roughness of the instrument (as a matter of low roughness and small sizes, we used MTwo- Sweden & Martina, Padova, Italy), will anticipate the rotary-translation and, at the same time, the generated impact on root canal's walls; this impact produces frictions, which prevents the instrument from advancing. In addition, many authors reported that reduction in operational speed could prevent taper locking, deformation and fracturing of Ni-Ti instruments[15–17] during clinical practice.

**Figure 8** Mesial root canal system's high degree of curvature.

**Figure 9** Final RX.

**Figure 10** One-year follow-up.

In this other case (Fig. 7), we can see how in a root canal with high degree of curvature in the apical one-third (Fig. 8), which prevents the engine-driven instruments to advance in rotation, as said, by manual rotation the entire working length can be shaped (Figs. 9 and 10).

## Results

So, we need to contain friction forces; to do this we can modify the characteristics of endodontic instruments, decreasing their roughness or reducing pressing forces between the instrument and root canal walls. For example, we should study instruments with a very contained working part and significantly reduced cutting efficiency in the coronal portion, in order to decrease roughness of its sections in contact. This instrument could be used after a preliminary enlargement with conventional rotary instruments, brought in proximity of the anatomical complication. As seen, the geometrical design is an important determinant because of the effect on the torsional and bending properties of the instrument.[19] In fact, the mechanical properties of the instruments are clearly influenced by their geometrical configurations, which include the cross-sectional shape (which determine the bending and torsional inertia), taper, helical angle and pitch.[20]

However, from the above, another fundamental element that we can modify to reduce the friction is to decrease pressing forces, for example, by reducing the torque on the endodontic motor. In fact, the higher is the torque set at the orifice of root canal (torque set on the endodontic motor), the greater is the reaction (and thus the pressing force) that we receive from the canal walls: thus, decreasing the momentum on the handpiece, the intensity of frictional forces will be reduced.

$$T = f \times b$$

where $T$ is the torque, $f$ is the intensity of the pair of forces applied from the handpiece to the instrument, and $b$ is the arm or the distance between the two forces. Hence, reducing $T$, for the same arm, decreases the intensity of the forces applied from the handpiece and, therefore, decreases the intensity of pressing forces. The amount of torque generated clearly depends on the size of the contact areas between the instruments and the canal walls, as was demonstrated.[21]

Ni-Ti engine-files operate by way of continuous rotation in the root canal and, as such, are subjected to unidirectional torque (assuming no stalling).[2] The value of torsional (shear) stress varies depending on the canal size,[22,23] hardness of the dentine to be cut,[24] and the use of a lubricant.[25] The cross-sectional configuration is also an important determinant of the distribution of stresses on the instrument.[26]

In some cases, therefore, the only way to advance is to reduce torque, but the minimum value of torque selectable in most endodontic motor is 1 N/m; a low value, but not negligible in absolute and still too high for circumvent the anatomical impediment. Friction, therefore, decrease either reducing the torque of the endodontic motor, or by making a less wrinkled endodontic instrument (limiting/containing its working part), in such a way that its portion located at the point of maximum curvature, takes minimum contacts with root canal walls (better zero contacts), simulating what occurs in vitro with cyclic fatigue tests. To date, several torque-controlled low-speed motors have been introduced to help reduce the incidence of separation when using rotary instruments.[1] The efficacy and clinical rationale for using these torque-controlled motors has been described recently in a case report.[27]

One of the effects of the real movement of rotary endodontic instruments into root canal systems is that the file will go across a longer way than that of a steel file, used, at first,

to determine working length. So much so that, if we refer the working length measured with an hand file on a rotary file, once it is rotating, when the rubber stopper, representing the established working length, arrives in correspondence of the chosen point of reference, the apex locator often does not confirm this data; but it will be necessary another small advancement to get the real working length. This process would be particularly valuable as much severe will be the curves that rotary instrument has to face and much less root canal system will be relatively straight and wide its transverse diameter; reason why we would need always apex locator to be connected to the rotary file during root canal shaping.

## Discussion

Since we know the real movement of Ni-Ti rotary file in root canals, we can now understand the importance of torsional stress and controlled torque for clinic practice. In fact, in the clinical situation, because of the diversity of canal dimensions, Ni-Ti rotary instruments may be subject to torsional stress of varying degrees, especially at the early stage of canal enlargement.[28]

We know that cyclic fatigue tests are performed without torque: in this case, the instrument does not keep contact with canal walls. In fact, in cyclic fatigue tests[29] files were rotated freely without tip binding, which limits the stress on the files to that produced by flexural stress. Moreover, torsional or lateral loading of the instrument as may be experienced in the clinical situation is not reproduced in much test method.[30] Furthermore, the few documented studies on torsional moments and forces exerted during actual canal preparation were carried out using straight canals.[1]

Clinically, cyclic fatigue fracture seems to be more prevalent in curved root canals, whereas torsional failure might occur even in a straight canal.[3,31] Although both failure modes probably occur simultaneously during root canal shaping,[32] most laboratory studies of instrument separation have been conducted separately either for cyclic fatigue resistance or torsional failure,[3,7,18,31,33–35] probably for convenience or for better control of the loading condition. There were rare studies that correlated these two aspects of fracture.[28]

In vivo, as soon as the rotary file takes contact with the walls of a curvature, because of the friction that comes from the pressing forces, it twists and struggles to advance: the progress of the rotation will be strongly slowed. If we rely only on the results of cyclic fatigue tests, we could use a new endodontic instrument respecting the time limits that are provided by manufacturers. However, in vivo, that data could point out only the flexibility of the instrument, but those times are not respected because we have to consider, in addition to simple rotating bending, also torsional fatigue, that cannot be evaluated in vitro. Therefore, we have to take special care because, in particular situations, we could have sudden and unexpected breakage that we actually had to expect: Ni-Ti rotary files are susceptible to fracture, especially when they are used in curved root canals in continuous rotation.[34]

Particularly, when an endodontic instrument has to face a 90° curvature, the torque set on the endodontic handpiece is equal to that of resistance, so the instrument cannot advance because the propulsion it receives is equal and opposite to the force, that prevents its progression.

At every curvature, in fact, the most apical part of the instrument, as seen, changes its axis of rotation and its rotation become a rotatory-translation that, because of the presence of root canal walls, turns into torsion. Therefore, we should talk about accumulation of torsional fatigue, because the instruments are subject to torsional forces, that are greater the more extensive and numerous are the angles of the curvature. In addition, more sharp an instrument is, the greater are its contacts with root canal walls, more it will be subject to torsional stresses, thus to accumulation of torsional fatigue. The endodontic instrument is subjected to torsion, its progression slows down and, because of the accumulation of fatigue (cyclic and torsional), it can undergo breakage.

Torsional overload is an important cause of failure for an endodontic instrument and should never be forgotten or underestimated. Therefore, it is easy to understand the importance to study a technique or an endodontic instrument, which can relate this phenomenon and allow a safe endodontic treatment according to root canal anatomy.

## Conclusions

We have seen how anatomical complexities make very intricate the real movement of rotary instruments into root canal systems. Besides, we have seen that the mechanical rotation is actually a rotary-translation.

That is the reason why, in some cases, we would need an endodontic instrument that can reconcile efficiency with a reduction of working part and torque. The ideal would be to find an instrument:

- With few, minimal radial contact points and working part limited to the finishing touch and negotiation of apical one-third.
- Very sharp in order to keep down the value of torque.

## Conflict of interest

The authors have no conflict of interest to declare.

## References


1. Peters OA, Barbakow F. Dynamic torque and apical forces of ProFile.04 rotary instruments during preparation of curved canals. *Int Endod J* 2002;**35**(4):379–89.
2. Kim TO, Cheung GS, Lee JM, Kim BM, Hur B, Kim HC. Stress distribution of three NiTi rotary files under bending and torsional conditions using a mathematic analysis. *Int Endod J* 2009;**42**(1):14–21.
3. Pruett J, Clement D, Carnes DJ. Cyclic fatigue testing of nickel-titanium endodontic instruments. *J Endod* 1997;**23**:77–85.
4. Kim HC, Yum J, Hur B, Cheung GS. Cyclic fatigue and fracture characteristics of ground and twisted nickel-titanium rotary files. *J Endod* 2010;**36**:147–52.
5. Parashos P, Messer HH. Rotary NiTi instruments fracture and its consequences. *J Endod* 2006;**32**:1031–43.
6. Pedullà E, Grande NM, Plotino G, Gambarini G, Rapisarda E. Influence of continuous or reciprocating motion on cyclic fatigue resistance of 4 different nickel-titanium rotary instruments. *J Endod* 2013;**39**:258–61.
7. Yum J, Cheung GSP, Park JK, Hur B, Kim HC. Torsional strength and toughness of nickel-titanium rotary files. *J Endod* 2011;**37**:382–6.

8. Pedullà E, Plotino G, Grande NM, Pappalardo A, Rapisarda E. Cyclic fatigue resistance of four nickel-titanium rotary instruments: a comparative study. *Ann Stomatol* 2012;**3**:59—63.
9. Bahia MG, Melo MC, Buono VT. Influence of cyclic torsional loading on the fatigue resistance of K3 instruments. *Int Endod J* 2008;**41**: 883—91.
10. Kim JY, Cheung GS, Park SH, Ko DC, Kim JW, Kim HC. Effect from cyclic fatigue of nickel-titanium rotary files on torsional resistance. *J Endod* 2012;**38**:527—30.
11. Cheung GS, Oh SH, Ha JH, Kim SK, Park SH, Kim HC. Effect of torsional loading of nickel-titanium instruments on cyclic fatigue resistance. *J Endod* 2013;**39**:1593—7.
12. Campbell L, Shen Y, Zhou HM, Haapasalo M. Effect of fatigue on torsional failure of nickel-titanium controlled memory instruments. *J Endod* 2014;**40**:562—5.
13. Parashos P, Gordon I, Messer HH. Factors influencing defects of rotary nickel titanium files after clinical use. *J Endod* 2004;**30**: 722—5.
14. Dobó-Nagy C, Serbán T, Szabó J, Nagy G, Madléna M. A comparison of the shaping characteristics of two nickel-titanium endodontic hand instruments. *Int Endod J* 2002;**35**:283—8.
15. Yared GM, BouDagher FE, Machtou P. Influence of rotational speed, torque and operator's proficiency on ProFile failures. *Int Endod J* 2001;**34**:47—53.
16. Martin B, Zelada G, Varela P, Bahillo JG, Magán F, Ahn S, et al. Factors influencing the fracture of nickel-titanium rotary instruments. *Int Endod J* 2003;**36**:262—6.
17. Lopes HP, Ferreira AA, Elias CN, Moreira EJ, de Oliveira JC, Siqueira Jr JF. Influence of rotational speed on the cyclic fatigue of rotary nickel-titanium endodontic instruments. *J Endod* 2009;**35**:1013—6.
18. Lee MH, Versluis A, Kim BM, Lee CJ, Hur B, Kim HC. Correlation between experimental cyclic fatigue resistance and numerical stress analysis for nickel-titanium rotary files. *J Endod* 2011;**37**: 1152—7.
19. Camps JJ, Pertot WJ, Levallois B. Relationship between file size and stiffness of nickel-titanium instruments. *Endod Dent Traumatol* 1995;**11**:270—3.
20. Zhang Ew, Cheung GS, Zheng YF. A mathematical model for describing the mechanical behavior of root canal instruments. *Int Endod J* 2011;**44**:72—6.
21. Blum JY, Matctou P, Micallef JP. Location of contact areas on rotary Profile instruments in relationship to the forces developed during mechanical preparation on extracted teeth. *Int Endod J* 1999;**32**:108—14.
22. Hübscher W, Barbakow F, Peters OA. Root canal preparation with Flex Master: assessment of torque and force in relation to canal anatomy. *Int Endod J* 2003;**36**:883—90.
23. Peters OA, Peters CI, Schonenberg K, Barbakow F. ProTaper rotary root canal preparation: assessment of torque and force in relation to canal anatomy. *Int Endod J* 2003;**36**:93—9.
24. Berutti E, Chiandussi G, Gaviglio I, Ibba A. Comparative analysis of torsional and bending stresses in two mathematical models of nickel-titanium rotary instruments: ProTaper versus ProFile. *J Endod* 2003;**29**:15—9.
25. Boessler C, Peters OA, Zehnder M. Impact of lubricant parameters on rotary instrument torque and force. *J Endod* 2007;**33**: 280—3.
26. Tripi TR, Bonaccorso A, Condorelli GG. Cyclic fatigue of different nickel-titanium endodontic rotary instruments. *Oral Surg Oral Med Oral Pathol Oral Radiol Endod* 2006;**102**:e106—14.
27. Gambarini G. Rationale for the use of low-torque endodontic motors in root canal instrumentation. *Endod Dent Traumatol* 2000;**16**:95—100.
28. Ha J-H, Kim SK, Cheung GS-P, Jeong SH, Bae YC, Kim H-C. Effect of alloy tipe on the life-time of torsion-preloaded nickel-titanium endodontic instruments. *Scanning* 2015;**37**(3):172—8.
29. Haïkel Y, Serfaty R, Bateman G, Senger B, Allemann C. Dynamic and cyclic fatigue of engine-driven rotary nickel-titanium endodontic instruments. *J Endod* 1999;**25**:434—40.
30. Cho OI, Versluis A, Cheung GS, Ha J-H, Hur B, Kim H-C. Cyclic fatigue resistance tests of nickel-titanium rotary files using simulated canal and weight loading conditions. *Restor Dent Endod* 2013;**38**:31—5.
31. Cheung GS. Instrument fracture: mechanisms, removal of fragments, and clinical outcomes. *Endod Top* 2009;**16**:1—26.
32. Wei X, Ling J, Jiang J, Huang X, Liu L. Modes of failure of ProTaper nickel-titanium rotary instruments after clinical use. *J Endod* 2007;**33**:276—9.
33. Alapati SB, Brantley WA, Svec TA, Powers JM, Nusstein JM, Daehn GS. SEM observations of nickel-titanium rotary endodontic instruments that fractured during clinical use. *J Endod* 2005;**31**: 40—3.
34. Cheung GS, Shen Y, Darvell BW. Effect of environment on low-cycle fatigue of a nickel-titanium instrument. *J Endod* 2007;**33**: 1433—7.
35. Kramkowski TR, Bahcall J. An in vitro comparison of torsional stress and cyclic fatigue resistance of ProFile GT and ProFile GT Series X rotary nickel-titanium files. *J Endod* 2009;**35**: 404—7.

Giornale Italiano di Endodonzia (2015) **29**, 65–69

Available online at www.sciencedirect.com

ScienceDirect

journal homepage: www.elsevier.com/locate/gie

ORIGINAL ARTICLE/ARTICOLO ORIGINALE

# The activation of irrigation solutions in Endodontics: a perfected technique

*L'attivazione degli irriganti in Endodonzia: una tecnica perfezionata*

**Michele Simeone [a], Alessandra Valletta [a], Amerigo Giudice [a], Pierpaolo Di Lorenzo [b], Alfredo Iandolo [a,*]**

[a] *Dipartimento di Neuroscienze, Scienze riproduttive e odontostomatologiche, Università degli Studi di Napoli Federico II, Italy*
[b] *Dipartimento di Scienze Biomediche Avanzate, Sezione di Medicina Legale, Università degli Studi di Napoli Federico II, Italy*

Received 22 July 2015; accepted 28 July 2015
Available online 3 September 2015

**KEYWORDS**
Irrigation solutions;
Activation;
Microscope;
Sodium hypochlorite.

**Abstract**
*Aim:* In endodontics a complete chemo mechanical cleansing of the complex root canal system is essential in order to achieve a theraupetic success.
*Methodology:* Sodium hypoclorite due to its antimicrobial and proteolytic characteristic, is an efficient endodontic irrigant and it is the most commonly used.

The following article introduces a refined technique in order to increase the degree of cleansing during endodontic treatment.

The technique involves intracanal heating of the irrigants through a heat source.
*Results:* The described technique is able to enhance simply and considerably the use of sodium hypochlorite, making it easily accessible even to generic operators.
*Conclusions:* To confirm the validity of this improved technique, further research and scientific studies are needed, although at the clinical level, the results by using it are very satisfactory.


* Corresponding author at: DDS, University of Naples Federico II, via S. Pansini 5, 80131 Naples, Italy.
*E-mail:* iandoloalfredo@libero.it (A. Iandolo).
Peer review under responsibility of Società Italiana di Endodonzia.

Production and hosting by Elsevier

http://dx.doi.org/10.1016/j.gien.2015.08.005
1121-4171/

**PAROLE CHIAVE**
Soluzioni irriganti;
Attivazione;
Microscopio;
Ipoclorito di sodio.

**Riassunto**
*Obiettivo:* In Endodonzia una completa detersione chemio-meccanica del complesso sistema dei canali radicolari è fondamentale per il raggiungimento del successo terapeutico.
*Materiali e metodi:* L'ipoclorito di sodio, grazie alle sue proprietà antimicrobiche e proteolitiche, è un irrigante endodontico efficiente ed efficace ed è il più comunemente utilizzato.

L'articolo che segue introduce una tecnica perfezionata per incrementare il grado di detersione durante il trattamento endodontico. La tecnica prevede il riscaldamento intracanalare della soluzione mediante una fonte di calore.
*Risultati:* La tecnica descritta riesce a potenziare in modo semplice e considerevole l'uso dell'ipoclorito di sodio, rendendola facilmente fruibile anche agli operatori generici.
*Conclusioni:* Per confermare la validità di questa tecnica perfezionata occorrono ulteriori ricerche e studi scientifici, anche se a livello clinico i risultati che si stanno ottenendo utilizzandola sono davvero soddisfacenti.


## Introduction

The long-term success of endodontic treatment is closely linked to adequate cleansing of the endodontic space after root canal shaping, and then proceed to a complete obturation of the complex root canal system.[1–3] Probably, a significant percentage of failures is caused by the presence of residual pulp tissue.[4] The endodontic space is composed by spaces easily accessible to hand and rotary instruments (main canals) and, as confirmed by many clinical and histological studies, by not easily accessible or inaccessible spaces (isthmus, delta, loop, lateral and accessory canals and dentinal tubules)[5] (Figs. 1–3). Root canal shaping is not able to reach all areas of the root canal system, regardless of the technique used; then a part of canal is not treated. It is therefore necessary to carry out the endodontic biochemistry cleansing (accessible and not accessible spaces); once cleaned, it can be filled and obtured with guttapercha and cement during obturation.[6] It is important to use proper care and diligence in the diagnosis and treatment of endodontic disease and make treatment plan, record data of pre-treatment and treatment itself and save them.[7] These are tips, useful to gather documents that can, in case of necessity, prove the correctness of the diagnostic, therapeutic and ethics behavior held by the dentist. Particularly important is recording and storage the informed consent, as in a non-negligible percentage of cases the complaint raised to the dentist is right in the defect information to the patient.[8] Bacteria are

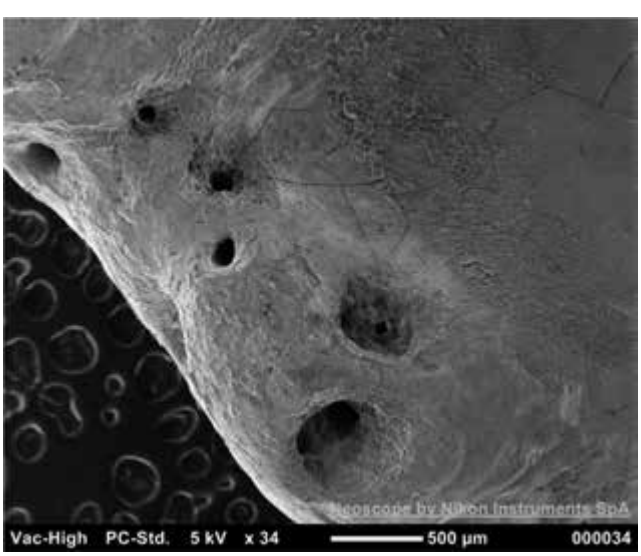


**Figure 1** Root apex of the mesial root of a lower first molar SEM photographed: the number of many exits are shown.

**Figure 2** Diaphanization of a lower central incisor: an isthmus between the two root canals is shown.

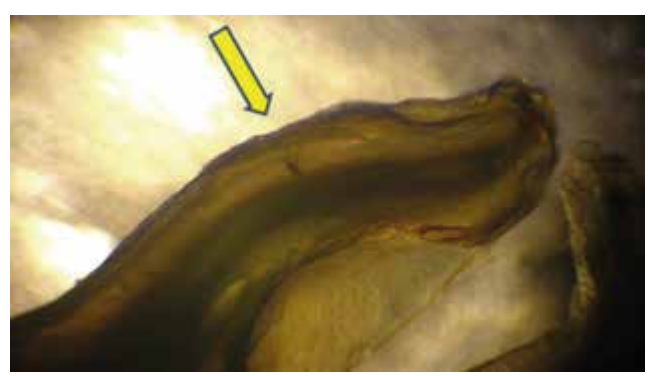

**Figure 3** Diaphanization of a lower first molar: a lateral canal in the middle third of the distal root is shown.

the main causative agents of periapical pulp infection.[9] A not treated canal, so do not cleansed, shaped and obtured, can lead to the development or persistence of a periapical lesion. In the literature a lot of authors showed various techniques to improve the effectiveness of sodium hypochlorite as irrigant, including the use of greater amounts of irrigant and preheating of the same.[10,11] Cunningham and Joseph have shown that a sodium hypochlorite solution at body temperature allows to carry out the sterilization in considerably less time compared to the same solution at room temperature (22 °C).[12] Preheated sodium hypochlorite solution has greater ability to dissolve pulp tissue and cleanse the canal.[11–13] Abou Rass and Oglesby[11] have compared the timing of the dissolution of the connective tissues of rat using sodium hypochlorite solutions at 2.6% and 5.25% at the temperature of 23 °C and 60 °C. Timing of the dissolution of the tissues significantly decreased with increasing of concentration and temperature. The speed at which a chemical reaction occurs increases with the increase of temperature, pressure, excitement and concentration. Since the pressure inside the root canal system cannot be increased, it is possible to accelerate the cleansing increasing the concentration and the temperature of the detergent shaking it once irrigated the endodontic space. The excitement is easily achieved by sonic or ultrasonic sources. Currently are available solutions of sodium hypochlorite with a concentration not exceeding 6% to prevent possible stinging reactions.[14,15] In everyday practice, sodium hypochlorite solution is preheated outside of the tooth to a temperature of 50 °C.[16–17] Preheated solutions have limited utility, since they rapidly stabilize at a temperature included between body and the ambient temperature.[13] Woodmansey[18] has shown that hypochlorite at boiling temperature is able to disintegrate the pulp tissue at a speed 210 times higher compared to the solution at room temperature (2 min against 420 min). For this reason in 2005 Woodmansey proposed a technique of intracanal heating of sodium hypochlorite using a heat source, System-B (Sybron Endo).[18] The technique was as follows: after completing chemo-mechanical preparation of the root canal system, a System-B plugger was chosen that fit passively to 3 mm from the working length. The heat source was at 200 °C with power equal to 10. Then the canal

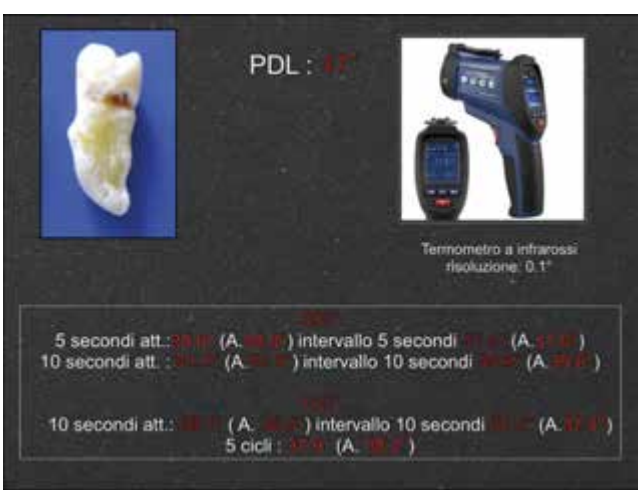


**Figure 4** Temperatures of the outer surface of the root measured during the heating cycle of the irrigant.

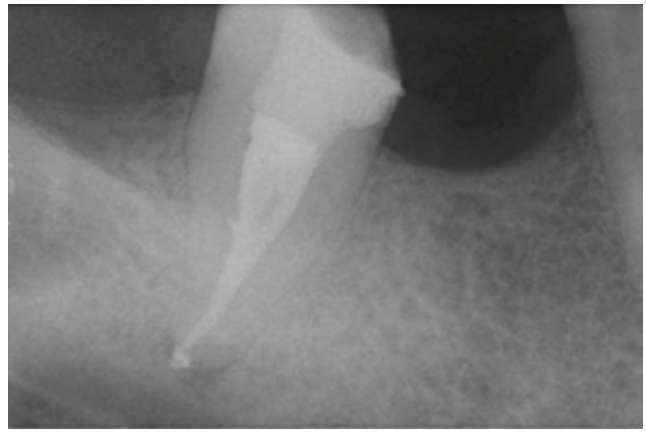

**Figure 5** Post-operative radiograph of 4.7. Obturation with thermo-plasticized guttapercha after activation and heating of irrigants: a complex endodontic anatomy is shown.

was irrigated with sodium hypochlorite introducing the heat-carrier activated for 3/5 s. The cycle should be repeated every 5 s until the complete irrigant evaporation. During the irrigant heating a pipe draw vapors of chlorine.

## Materials and methods

This study proposes a revision and improvement of Woodmansey technique with a careful analysis of the benefits and improvements.

**Figure 6** Post-operative radiograph of 2.1. Obturation with thermo-plasticized guttapercha after activation and heating of irrigants: several lateral canals are shown.

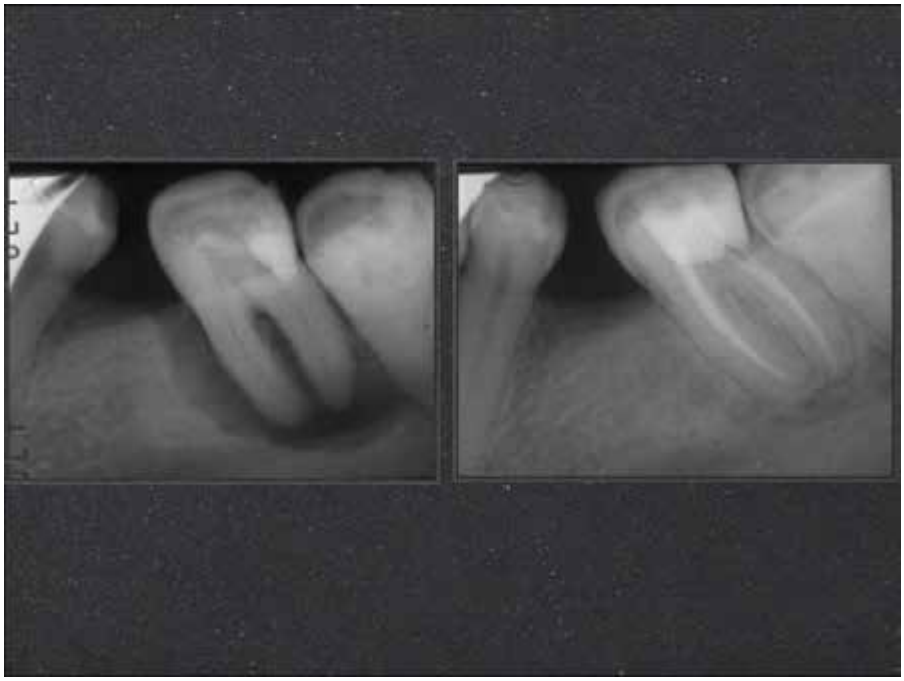

**Figure 7** Endodontic treatment of 4.7 with severe osteolytic lesion. Treatment with activation and heating of irrigants. 24 months control: complete restitutio ad integrum of bone tissue is shown.

## Perfected technique: operating protocol

Sodium hypochlorite has a boiling temperature included between 96 °C and 120 °C. Moreover, with temperature increasing more chlorine is released, so there is a reduction of the title.

Based on these characteristics Woodmansey technique has been revised and improved. First of all the temperature of the heat carrier has been changed, from 200 °C to 150 °C. Since the boiling temperature of sodium hypochlorite is between 96 °C and 120 °C it is worthless to use the heat carrier at 200 °C. Keeping it at 150 °C the boiling point will be reached, the irrigant will act more with less lost of chlorine. It will increase the safety for the periodontal ligament too. The smaller heat carrier in 2005 was the fine (50/06), then to bring it to 3 mm from the working length, the canal must be abundantly prepared. Today, however, there are several tools such as 30/04, then the passive 3 mm from the working length can be easily achieved without excessive preparations. Each activation cycle of the heat-carrier lasts 10 s with an interval 10 s. During activation, the heat carrier makes short excursions of 2 mm up and down in order to shake the irrigant. After each cycle, the irrigant is replaced with fresh solution in order to have hypochlorite with greater amounts of active chlorine. By heating, however, the same solution until complete evaporation after a couple of cycles, the title of chlorine will drastically reduce. The activation cycle is repeated 5 times. During each activation of the irrigant, the vapors are sucked by a pipe. There were carried out tests on extracted teeth for periodontal reasons to assess during the irrigant heating if there were leaks of irrigant or vapors beyond the apex. The root canals were prepared up to a measure of 30/06. The irrigant was brought to working length with an endodontic needle with lateral exit. Then the heat carrier was passively inserted to 3 mm from the working length and has been activated. During activation, the apical foramen was observed at 10× (stereo microscope) to assess the leak of irrigants or vapors. No leakage was highlighted. Another parameter considered was the heating of the outer surface of the root, at the third coronal level, middle, apical and at the foramen level. During activation of the irrigant with an infrared thermometer (resolution: 0.1 °C) the temperatures on the outer surface of the root were evaluated. Using the values exposed in the operating protocol external temperature higher than 42.5 °C were not detected, which is below the levels of heat (47 °C) dangerous for the cells of the periodontal ligament (Fig. 4).[19,20]

## Conclusions

The awareness of the difficulty of access mechanically to tissues and to pathogens present in the endodontic space and in the dentinal tubules, led us to develop operating methods that use chemicals agents that can reach deeper endodontic spaces, optimizing the apical flow (Endovac) or decreasing the surface tension by the addition of surfactants. The described technique is able to enhance simply and considerably the use of sodium hypochlorite, making it easily accessible even to generic operators. Of course, to confirm what we have described, further research and scientific studies are needed, although at the clinical level, the results by using it are very satisfactory (Figs. 5—7).

## Conflict of interest

The authors have no conflict of interest.

## References


1. Paduano S, Uomo R, Amato M, Riccitiello F, Simeone M, Valletta R. Cyst-like periapical lesion healing in an orthodontic patient: a case report with five-year follow-up. *G Ital Endod* 2013;**27**(2): 95—104.
2. Silvani M, Brambilla E, Cerutti A, Amato M, Gagliani M. Root canal treatment quality in undergraduate program: a preliminar report on NiTi reciprocating files. *G Ital Endod* 2013;**27**:33—7.
3. Ametrano G, Riccitiello F, Amato M, Formisano A, Muto M, Grassi R, et al. μCT analysis of mandibular molars before and after instrumentation by Reciproc files. *Recent Prog Med* 2013;**104**: 420—4.
4. Iandolo A. Reperimento del canale mesiale mediano nei primi molari inferiori II. *Dent Mod* 2011;**18**:269.
5. Spagnuolo G, Ametrano G, D'Antò V, Formisano A, Simeone M, Riccitiello F, et al. Microcomputed tomography analysis of mesiobuccal orefices and major apical foramen in first maxillary molars. *Open Dent J* 2012;**6**:118—25.
6. Iandolo A, Ametrano G, Amato M, Rengo S, Simeone M. IG-File: un nuovo strumento per l'ottimizzazione della detersione canalare e per la misurazione del diametro apicale. *G Ital Endod* 2011;**25**(2): 72—81.
7. Di Lorenzo P, Niola M, Pantaleo G, Buccelli C, Amato M. On the comparison of age determination methods based on dental development radiographic studies in a sample of Italian population. *Dent Cadmos* 2015;**83**(1):38—45.
8. Di Lorenzo P, Niola M, Buccelli C, Re D, Cortese A, Pantaleo G, et al. Professional responsibility in dentistry: analysis of interdepartmental case study. *Dent Cadmos* 2015;**83**(5):324—40.
9. Dahlen G, Bergenholtz G. Endodontic activity in teeth with necrotic pulps. *J Endod* 1980;**59**:1033—9.
10. Sedgley CM, Nagel AC, Hall D, Applegate B. Influence of irrigant needle depth in removing bioluminescent bacteria inoculated into instrumented root canals using real-time imaging in vitro. *Int Endod J* 2005;**38**:97—104.
11. Abou Rass M, Oglesby SW. The effects of temperature, concentration and tissue type on the solvent ability of sodium hypochlorite. *J Endod* 1981;**7**:376—7.
12. Cunningham WT, Joseph SW. Effect of temperature on the bactericidal action of sodium hypochlorite endodontic irrigant. *Oral Surg Oral Med Oral Pathol* 1980;**50**:569—71.
13. Cunnigham WT, Balekjian AY. Effect of temperature on collagen-dissolving ability of sodium hypochlorite endodontic irrigant. *Oral Surg Oral Med Oral Pathol* 1980;**49**:175—7.
14. Spagnuolo G, Desiderio C, Rivieccio V, Amato M, Rossetti DV, D'Antò V, et al. In vitro cellular detoxification of triethylene glycol dimethacrylate by adduct formation with N-acetylcysteine. *Dent Mater* 2013;**29**(8):e153—60.
15. Mohammadi Z, Giardino L, Palazzi F, Shalavi S, Alikhani MY, Lo Giudice G, et al. Effect of sodium hypochlorite on the substantivity of chlorexidine. *Int J Clin Dent* 2013;**6**(2): 173—8.
16. Berutti E, Marini R. A scanning electron microscopic evaluation of the debridement capability of sodium hypochlorite at different temperatures. *J Endod* 1996;**22**:467—70.
17. Riccitiello F, Maddaloni G, D'Ambrosio C, Amato M, Rengo S, Simeone M. Operating microscope: diffusion and limits. *G It Endod* 2012;**26**(2):67—72.
18. Woodmansey KF. Intracanal heating of sodium hypochlorite solution. An improbe endodontic irrigation technique. *Dent Today* 2005;**24**:114—6.
19. D'Antò V, Valletta R, Amato M, Schweikl H, Simeone M, Paduano S, et al. Effect of nickel chloride on cell proliferation. *Open Dent J* 2012;**6**:177—81.
20. Eriksson AR, Albrektsson T. Temperature threshold levels for heat-induced bone tissue injury: a vital-microscopic study in the rabbit. *J Prosthet Dent* 1983;**50**:101—7.

Giornale Italiano di Endodonzia (2015) **29**, 70—76

Available online at www.sciencedirect.com

ScienceDirect

journal homepage: www.elsevier.com/locate/gie

CASE REPORT/CASO CLINICO

# Importance of CBCT in the management plan of upper canine with internal resorption

*Importanza della CBCT nel piano di trattamento di un canino superiore con riassorbimento interno*

**Roberto Fornara** [a,*], **Dario Re Cecconi** [b]

[a] *Private Practice in Magenta, Italy*
[b] *Department of Medicine, Surgery and Dentistry, Unit of Oral Medicine, Oral Pathology and Gerontology, University of Milan, Italy*

Received 2 September 2015; accepted 22 September 2015

**KEYWORDS**
Internal resorption;
Perforating internal root resorption;
Cone beam computed tomography;
Mineral trioxide aggregate;
Nonsurgical endodontic therapy.

**Abstract**
*Aim:* Internal root resorption is a particular medical condition which requires the clinician to a treatment as early as possible to avoid complications such as excessive loss of mineralized tissues and periodontal communications.
*Methodology:* This article describes the diagnosis and treatment of a case of internal resorption of an upper canine in a patient of 21 years. The presence of pain and swelling periodontal gum showed an interest, a sign of the presence of a perforation.
*Result and conclusions:* Accurate diagnosis associated with the three-dimensional evaluation of the internal fault (CBCT examination) have allowed a conservative treatment who has allowed the recovery of the tooth.


* Corresponding author at: Via G. Cler, 42, 20013 Magenta, Milano, Italy. Tel.: +39 02 97296453; fax: +39 02 97296453.
*E-mail:* info@studiofornara.eu (R. Fornara).
Peer review under responsibility of Società Italiana di Endodonzia.

Production and hosting by Elsevier

http://dx.doi.org/10.1016/j.gien.2015.09.001

**PAROLE CHIAVE**
Riassorbimento interno;
Riassorbimento radicolare interno con perforazione;
Cone Beam tomografia compiuterizzata;
Mineral Trioxide Aggregate;
terapia endodontica non chirurgica.

**Riassunto**
*Obiettivi:* Il riassorbimento interno radicolare rappresenta una particolare condizione patologica che obbliga il clinico ad un trattamento il più precoce possibile onde evitare complicazioni quali l'eccessiva perdita dei tessuti mineralizzati e le comunicazioni parodontali.
*Materiali e metodi:* Questo articolo descrive la diagnosi e il trattamento di un caso di riassorbimento interno di un canino superiore in una paziente di 21 anni. La presenza di dolore e di una tumefazione gengivale evidenziava un interessamento parodontale, segno della presenza di una perforazione.
*Risultati e conclusioni:* Una diagnosi accurata associata alla valutazione tridimensionale del difetto interno (esame CBCT) hanno permesso un intervento conservativo che ha consentito il recupero dell'elemento dentario.


## Introduction

Internal root resorption (IRR) is a relatively rare condition in permanent teeth that poses many difficulties for treatment.[1–5] IRR occurs exclusively as a result of pulp inflammation, indeed IRR is the progressive destruction of intraradicular dentin and dentinal tubules along the middle and apical thirds of the canal walls as a result of clastic activities.[1] IRR can manifest by means of a slow or rapid progression.[6]

The etiology of IRR is not fully understood, however, it can be associated with many factors such as partial removal of the pulp, trauma, orthodontic treatment, caries, pulp capping with calcium hydroxide or pulpotomy, extreme heat and a cracked tooth. These factors stimulate the pulp tissue, thus initiating inflammatory processes and then some undifferentiated cells of the pulp convert themselves to osteoclasts or macrophages, which results in dentinal resorption.[1,7,8]

The clinical characteristics of internal root resorption depend on the degree and stage of the resorption.[9] Usually IRR is asymptomatic and detected coincidentally through routine radiographs,[1,4] during active progression of the resorption the tooth is at least partially vital and may show typical symptoms of pulpitis.[1] However, it may include the presence of a reddish area — pink spot, which represents the granulation tissue showing through the resorbed area.[10] Untreated teeth often turn gray/dark gray if the pulp becomes Necrotic[9].

The diagnosis and follow-up of IRR is primarily based on radiographic examinations and supplementary information gained from the patient history and clinical findings.[1,6]

In conventional radiographs IRR can appear as round, oval or elongated radiolucent enlargements of the root canal space with well-defined margins, and shifted radiographs do not change the positional relationship of the canal to the resorptive entity.[1,9]

Conventional radiography is often unable to identify the true extent, location, or portal of entry of a resorptive lesion.[1,11]

Recently Cone Beam Computed Tomographic (CBCT) allows a more accurately diagnosis than conventional radiographs.[10–12] CBCT images also display the location and extension of perforations and resorptive defects.[12–14] Several case reports and case series have confirmed the usefulness of CBCT imaging in diagnosing and managing resorptive lesions.[1,11,15] In particular the use of small *FOV (fi eld of view)* captures clear images that allow display even small perforation. CBCT scanning has been shown to help determine treatment complexity and aid the clinician in offering an accurate prognosis.[3]

Several reports have shown that in cases where internal resorption was not a result of inflammation, the arrest of resorption was followed by apposition of calcified tissue.[16,17]

Root canal treatment remains the treatment of choice of internal root resorption as it removes the granulation tissue and blood supply of the clastic cells.[8]

The complex irregularities of the root canal system, especially in internal resorption defects, pose technical difficulties for the thorough cleaning and obturation of the root canal. The persistence of organic debris and bacteria in these irregularities may interfere with the long-term success of the endodontic treatment.[17,18] Therefore, the importance of achieving total obliteration of the root canal space has been stressed in case of internal resorption.[19]

Instrumentation and cleaning of the root canal space of teeth with IRR is a challenge different from those of normal endodontic treatment. In case of actively resorbing vital tissue, excessive bleeding makes it difficult to locate the root canal openings.[20] However, irrigation with sodium hypochlorite (NaOCl) or inter appointment calcium hydroxide ($Ca(OH)^2$) dressing (to control bleeding, and to necrotize residual pulp tissue and to make the necrotic tissue more soluble to NaOCl[1,9]) will in most cases help to reduce the bleeding.[1,21,22]

The NaOCl penetration in the endodontic space and its antibacterial activity can be enhanced by ultrasonic activation.[23]

Various materials available for the treatment of internal root resorption include MTA, glass ionomer cement, Super EBA, hydrophilic plastic polymer, zinc oxide eugenol and zinc acetate cement, amalgam alloy, composite resin and thermoplasticized gutta-percha by injection or condensation techniques.[10]

When IRR was perforated the mineral trioxide aggregate (MTA) was indicated for filling the resorption cavity.[2–5] MTA is most commonly used because of its biocompatibility, sealing ability and potential induction of osteogenesis and cementogenesis followed by thermoplasticized gutta-percha obturation techniques.[2,24–26]

**Figure 1** Clinical photograph showing localized swelling.

**Figure 2** Pre-operative periapical radiograph showing a periapical lesion with severe internal root resorption on the right maxillary canine.

## Materials and methods

A 21-year-old female was referred to our practice for pain and swelling since 8—10 days. The medical history was non-contributory. She had no story of traumatic injury but she led the orthodontic appliance fixed 7 years ago for 2 years.

The patient's oral hygiene was fair and the periodontal condition was excellent.

Clinical examination revelated periodontal abscess in 22—23 area (Fig. 1), no sinus tract is present. The crown of 2.3 did not show any pink spot (Fig. 1). The tooth responded positively to the test of percussion while the thermal test (crio test) was uncertain, cold testing with ENDO-ICE frozen gas (Pharmaéthyl Septodont, Saint-Maur-des-Fossés, Cedex, France). The tooth did not present pathologic mobility. The adjacent teeth responded normally to pulp vitality tests.

The examination of palpation at the apex of the 2.3 the patient reported pain. The patient do not take farmacology therapy.

A preoperatory periapical radiographic examination (Fig. 2) (Insight, Carestream Dental, Rochesters New York, USA) showed a radiolucency elongated positioned along the pulp chamber and the coronal portion of the root canal in the mesial part of the tooth with a crescent radiolucency lesion in the alveolar bone next to a resorptive lesion.

A CBCT was performed (Fig. 3) (Orthophos XG 3D, SIRONA DENTAL SYSTEMS, Verona, Italy) with a small field of view ($5 \times 5.5$ cm) and high resolution (0.1 mm slice thickness) for the study of real dimension, position and shape of the resorption (SIDEXIS XG 2.61 SIRONA DENTAL SYSTEMS, Verona, Italy). In particular the bucco-palatal anatomy can be visualized (with conventional radiography cant be displayed). Three dimensional imaging also aids the clinician to evaluate the exact location of perforation that preoperative radiograph has not determined.

The patient was advised of the technical difficulties and potential risks of the endodontic treatment and the uncertainty healing. The patient gave written consent for the proposed treatment.

Treatment plain including cleaning of the resorptive cavity and the canal space, obturation of the resorption with MTA, endodontic obturation with gutta-percha and direct composite.

At the first session after mouth rinse with 0.2% chlorhexidine gluconate (Curasept, Curaden Healthcare, Saronno, VA, Italy) the tooth was anesthetized with buccal infiltration of


**Figure 3** (a—c) Axial, coronal and sagittal CBCT cross-sections, is possible to showing the extension of the internal root resorption lesion on the right maxillary canine, the extension of periapical lesion and the septum that divide the resorption by endodontic canal. (d) The 3D reconstruction of coronal CBCT cross-section showing the resorption area with perforation of radicular walls.

**Figure 4** Clinical photograph showing endodontic access is possible see the blooding by perforation.

2% Articaine containing 1:100,000 epinephrine (Ubistesin 3M ESPE, Neuss, Germany).

The tooth was isolation with a rubber dam (Nictone Manufacturera Dental Continental, Zapopan, Jalisco, Mexico), a classic palatal access cavity was prepared with tungsten carbide bur (Fig. 4) (2P SS White Burs Inc., Lakewood, NJ, USA).

Based on the CBCT findings, the lesion was diagnosed as a perforating internal resorption and the treatment was performed under surgical microscope at 8—12.5× of magnification (Leika M400-E, Sesto San Giovanni, MI, Italy). Irrigation was performed with 5.25% NaOCl (Niclor Ogna, Muggió, MB, Italy) at 50 °C with ultrasonic activation (Fig. 5) (ProUltra™ Endo7, Maillefer Dentsply, Baillaigues, Switzerland).

The resorptive cavity it has been cleaned with the aid of ultrasonic inserts (Figs. 6 and 7) (ETBD Satelec, StartX® 1 Maillefer Dentsply, Baillaigues, Switzerland) and the granulation tissue was removed almost completely. The first working length hypothetical was performed by a preoperative radiograph and then by CBCT software. The pulp tissue has been removed from the root canal and then was shaped provisionally. calcium hydroxide was placed as interappointment dressing (Endoidrox Ogna, Muggió, MB, Italy), which has good tissue dissolution property to remove completely the granulation tissue in the clastic cavity.

After 10 days the periodontal swelling was clinically healing (Fig. 8) and the root canals were re-entered and irrigated alternately with 5.25% NaOCl at 50 °C and sterile saline 0.9% (S.A.L.F., Cenate sotto, BG, Italy) to remove the temporary dressing. Root canal were cleaned and then the electronically working length has been taken by a apex locator (Justy II, Yoshida Dentcraft, Tokio, Japans) and it was 28 mm. The resorption cavity was cleaned and finished with ultrasonic insert (K25 Acteon Satelec, MERIGNAC cedex, France) and dried gently with a sterile paper points (Absorbent paper point size coarse, Inline, TO, Italy). Communication with the external root surface was evident (Fig. 9). While the coronal part of root canal was sealed with a large paper point, the white MTA Prooroot Maillefer Dentsply, Ballaigues, Switzerland) was condensed into the resorption cavity using a non-surgical MTA carrier (Micro Apical Placement System,

**Figure 5** Clinical photograph showing ultrasonic activation of endodontic irrigant.

**Figure 6** Clinical photograph showing the internal resorption after detersion.

**Figure 7** Clinical photograph showing the endodontic canal and the two perforations.

**Figure 8** Clinical photograph showing healing of gengiva after 10 days.

**Figure 9** Clinical photograph showing the internal resorption after cleaning and shaping by ultrasonic tip under operative microscope.

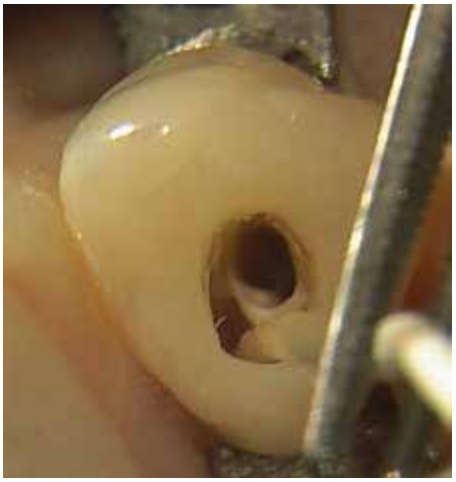

**Figure 10** Clinical photograph showing root canal drie with calibrated absorbent paper points.

Produits Dentaires, Vevey, Switzerland) and with the help of root canal pluggers and paper points wet the MTA cement was adapted into cavity (Figs. 10 and 11). (Maillefer Dentsply, Ballaigues, Switzerland). A moist cotton pellet was placed in the pulp chamber to stimulate MTA setting and a control

**Figure 11** Clinical photograph showing the resorptive area has been filled with MTA.

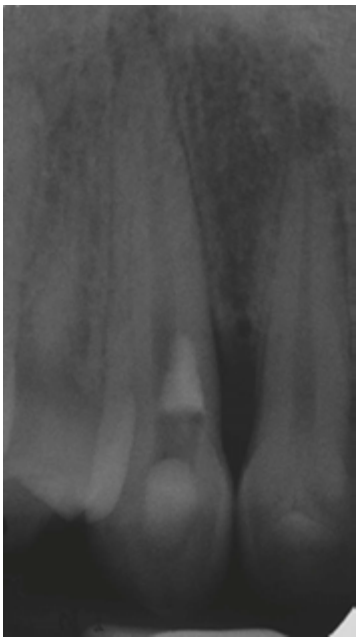

**Figure 12** Intra-operative periapical radiograph showing the MTA place in the resorption area.

radiograph was acquired to verify the quality of the MTA placement (Fig. 12).

The next appointment, after 7 days, after checking the complete hardening of the MTA (Fig. 13), the canal was prepared using crown down technique with ProTaper Universal files (Maillefer Dentsply, Ballaigues, Switzerland) accompanied by copious irrigation with 5.25% sodium hypochlorite at 50 °C. The last endodontic file used was Protaper Universal F5 iso 50 taper .04 (Maillefer Dentsply, Ballaigues, Switzerland) and the master cone radiograph was taken.

Before the drying of the root canal after a final rinse with EDTA (E.D.T.A. 17% Ogna, Muggió, MB, Italy) and the last rinse with NaOCL, the root canals were dried with calibrated absorbent paper points and the canal was obturated with gutta percha (Dentsply, Maillefer) and Argoseal (Argoseal Ogna, Muggió, MB, Italy) using vertical compaction with heated pluggers and condensers (Calamus dual Maillefer Dentsply, Ballaigues, Switzerland).

**Figure 13** Clinical photograph showing the hardening of MTA.

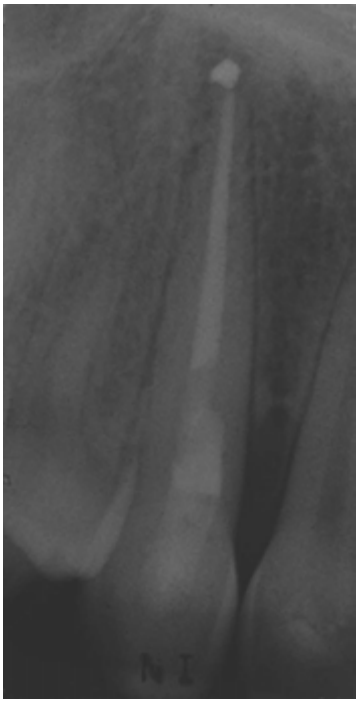

**Figure 14** Periapical radiograph after 3-month showing the initial healing of periapical lesion and the essence of parodontal defect.

Between the therapy appointment the access cavity was temporarily sealed with Cavit G (3M ESPE, Neuss, Germany). At the fourth clinical session the coronal chamber was restored with a fiber post (Tech 21 cop size Isasan, Rovello Porro, CO Italy) and composite (Optibon Solo Plus Keer Scafati, SA Italy; Enamel Plus HFO mycelium Rosbach, Germany) an immediate postoperative radiograph was taken and radiographic follow up was conducted three month later (Fig. 14). Clinical examination was performed six months after proving a functional tooth without periodontal probe and inflammatory.

## Discussion

Internal Root Resorption (IRR) is a pathologic condition that destroys the hard tissues of teeth by reactivating odontoclastic activity.[1,20] IRR begins in the endodontic space to then continue along the external surface of the tooth and requires a partial pulp vitality.[1,7] If detected at an early stage, it is possible to have a conservative treatment — such as a root treatment — and therefore save the tooth.[1,4] In case of late diagnosis — which often occurs due to a lack of symptoms — and IRR with one or more communications with the paradontal tissue, a clinician has to face two issues: diagnosis and treatment.

For what concerns diagnosis, as periapical radiograph is a two-dimensional representation of a three-dimensional structure, it does not give us the full picture of the clinical condition and, therefore, does not allow a correct treatment plan. In recent years, cone beam CT has been introduced in dentistry.[5,11,12] The use of a small FOV (*field of view*) has led to the use of this technology in the diagnosis and assessment of many dental pathologies — among which IRR — thus limiting X-ray exposure.[11] In particular, 3D view allows us to see the buccopalatal dimensions and the possible presence and exact position of all parodontium communications, something radiograph does not show.[4,5]

For what concerns treatment, the choice is strongly linked to a precise diagnosis.[1,3] That is why we believe that Cone Beam CT does not only allow a better resorption diagnosis, but, since it gives us more data, it allows clinicians to establish the most appropriate treatment, thus it reduces overtreatment when recovery is no longer possible.[11,14,15]

In this clinical case, due to cone beam CT, we were able to plan the conservative treatment starting from a correct diagnosis and precise indication of all perforations.

In the orthograde conservative treatment for this kind of disorder, the key is a correct disinfection and cleansing of the endodontic space with heated NaOCl and EDTA, and ultrasonically activating them using ultrasonic inserts.[22,23] The effect of NaOCL is important also to deactivate clastic activity by blocking the resorption process.[1,8,10] The use of a $Ca(OH)^2$ medication between appointments is necessary to reduce the presence of bacteria in the endodontic space.[22] Furthermore, the tissue dissolution capacity of calcium hydroxide[22] improves mechanical removal in those anatomic areas that cannot be reached by endodontic tools. Resorption anatomy causes difficulties in its cleansing; at the same time, the possible presence of debris and bacteria may hinder treatment prognosis, hence some authors recommend the use of ultrasonic tips for resorption cleansing.[4,23]

The prognosis of teeth treated with IRR depends on the size of the lesion and the presence of perforations associated with compromised parodontal tissues.[1,9,18] Moreover, wide lesions imply a reduced mechanic resistance of the tooth with a greater risk of vertical fracture. An early diagnosis is still the best solution for conservative and resolutive treatments.[1,8]

In our clinical case, the presence of more communications with the parodontal tissue led to closing this defect with MTA based cement.[17,2,26] This because this kind of cement creates a stable seal and grip when liquids are present. Finally, the many properties MTA cements have — biocompatibility, bactericide effect and radiocapacity — make them the first choice for the treatment of IRR with perforation.[7,2,24,26]

## Conclusions

Although this clinical case has only been completed recently — radiograph follow up after three months and control visit after six months — the rapid solution of the symptoms and parodontal abscess after only a few days could be considered as a concrete base for the long-term recovery of the tooth.

## Clinical relevance

This case report has shown the limited accuracy of 2D radiographs and the superior performance of cone beam CT exam in the management of internal resorption with perforation.

## Conflict of interest

The authors deny any conflicts of interest.

## References


1. Patel S, Ricucci D, Durak C, Tay F. Internal root resorption: a review. *J Endod* 2010;**36**:1107—21.
2. Meire M, De Moor R. Mineral trioxide aggregate repair of a perforating internal resorption in a mandibular molar. *J Endod* 2008;**34**:220—3.
3. Özer SY. Diagnosis and treatment modalities of internal and external cervical root resorptions: review of the literature with case reports. *Int Dent Res* 2011;**1**:32—7.
4. Bendyk-Szeffer M, Łagocka R, Trusewicz M, Lipski M, Buczkowska-Radlińska J. Perforating internal root resorption repaired with mineral trioxide aggregate caused complete resolution of odontogenic sinus mucositis: a case report. *J Endod* 2015;**41**(February (2)):274—8.
5. Takita T, Tsurumachi T, Ogiso B. Endodontic treatment of a maxillary lateral incisor with a perforating internal resorption by using cone beam computed tomography as a diagnostic aid: a case report. *Quintessence Int* 2011;**42**(October (9)):745—52.
6. Asgary S, Eghbal MJ, Mehrdad L, Kheirieh S, Nosrat A. Surgical management of a failed internal root resorption treatment: a histological and clinical report. *Restor Dent Endod* 2014;**39**(May (2)):137—42.
7. Yadav P, Rao Y, Jain A, Relhan N, Gupta S. Treatment of internal resorption with mineral trioxide aggregates: a case report. *J Clin Diagn Res* 2013;**7**(October (10)):2400—1.
8. Nilsson E, Bonte E, Bayet F, Lasfargues JJ. Management of internal root resorption on permanent teeth. *Int J Dent* 2013;**2013**: 929486.
9. Esnaashari E, Pezeshkfar A, Fazlyab M. Nonsurgical management of an extensive perforative internal root resorption with calcium-enriched mixture cement. *Iran Endod J* 2015;**10**:75—8.
10. Mittal S, Kumar T, Mittal S, Sharma J. Internal root resorption: an endodontic challenge: a case series. *J Conserv Dent* 2014;**17**: 590—3.
11. Cotton TP, Geisler TM, Holden DT, Schwartz SA, Schindler WG. Endodontic applications of cone-beam volumetric tomography. *J Endod* 2007;**33**:1121—32.
12. Kalender A, Oztan MD, Basmaci F, Aksoy U, Orhan K. CBCT evaluation of multiple idiopathic internal resorptions in permanent molars: case report. *BMC Oral Health* 2014;**14**:39.
13. Ball RL, Barbizam JV, Cohenca N. Intraoperative endodontic applications of conebeam computed tomography. *J Endod* 2013;**39**:548—57.
14. Shemesh H, Cristescu RC, Wesselink PR, Wu MK. The use of cone-beam computed tomography and digital periapical radiographs to diagnose root perforations. *J Endod* 2011;**37**:513—6.
15. Estrela C, Bueno MR, De Alencar AH, Mattar R, Valladares Neto J, Azevedo BC. Method to evaluate inflammatory root resorption by using cone beam computed tomography. *J Endod* 2009;**35**: 1491—7.
16. Holan G. Idiopathic internal resorption followed by apposition of calcified deposits in primary molars: a case report. *Int J Pediatr Dent* 1998;**8**:213—7.
17. Sari S, Sönmez D. Internal resorption treated with mineral trioxide aggregate in a primary molar tooth: 18-month follow-up. *J Endod* 2006;**32**:69—71.
18. Goldberg F, Massone EJ, Esmoris M, Alfie D. Comparison of different techniques for obturating experimental internal resorptive cavities. *Endod Dent Traumatol* 2000;**16**:116—21.
19. Frank AL, Weine FS. Nonsurgical therapy of the perforative defect of internal resorption. *J Am Dent Assoc* 1973;**87**:863—8.
20. Fuss Z, Tsesis I, Lin S. Root resorption — diagnosis, classification and treatment choices based on stimulation factors. *Dent Traumatol* 2003;**19**:175—82.
21. Trope M, Chivian N, Sigurdsson A, Vann WFJ. Traumatic injuries. In: Cohen S, Burns RC, editors. *Pathways of the pulp*. 8th ed. Mosby: St Louis; 2002.
22. Turkun M, Cengiz T. The effects of sodium hypochlorite and calcium hydroxide on tissue dissolution and root canal cleanliness. *Int Endod J* 1997;**30**:335—42.
23. Mozo S, Llena C, Forner L. Review of ultrasonic irrigation in endodontics: increasing action of irrigating solutions. *Med Oral Patol Oral Cir Bucal* 2012;**17**.
24. Torabinejad M, Chivian N. Clinical applications of mineral trioxide aggregate. *J Endod* 1999;**25**:197—205.
25. Economides N, Pantelidou O, Kokkas A, Tziafas D. Short-term periradicular tissue response to mineral trioxide aggregate (MTA) as root-end filling material. *Int Endod J* 2003;**36**:44—8.
26. Fornara R, Gorni F, Gagliani M. Le perforazioni iatrogene: classificazione e possibilità di trattamento ortogrado. *Giornale Italiano di Endodonzia aprile* 2012;**26**:2—12.

# LETTERA DEL PRESIDENTE

Carissimi Soci,

quest'anno il Congresso Nazionale della Società di Endodonzia si svolgerà al Palazzo della Cultura e dei Congressi di Bologna, città che ha dato sempre risposte positive a tutte le nostre manifestazioni lì organizzate.

Il tema congressuale è "Guardando al futuro", scelto per differenti motivi. Per valutare i nuovi strumenti e le nuove attrezzature che le aziende annualmente ci mettono a disposizione ma anche e soprattutto per osservare quella che sarà la linfa vitale dell'Associazione negli anni futuri: i giovani!

Abbiamo rimodellato la Società in questo senso, dando loro molta più attenzione che in passato. Abbiamo aumentato lo spazio loro dedicato durante il Congresso. Grazie alla disponibilità di numerose sedi Universitarie, siamo andati a presentarci e a spiegare il progetto di una Società che vuole evolvere e diventare sempre più moderna. Abbiamo portato l'insegnamento in maniera capillare, con una grande diffusione sul territorio, con i Corsi a Km Zero, proprio per ridurre più possibile i costi della formazione per chi non ha ancora grosse disponibilità economiche, ovviamente non solo per i giovani.

Quest'anno abbiamo inserito, con grande successo, un concorso per poter valutare inizialmente quali sono le potenzialità tecniche e culturali dei laureati da pochi anni e abbiamo dato la possibilità, non solo al vincitore ma a tutti gli iscritti di partecipare a un momento di fondamentale aggregazione, rappresentato dal Closed Meeting, che è stato particolarmente interessante e produttivo e reso ancora più stimolante dalla loro presenza.

Il Congresso quest'anno avrà una formula differente, volta ad avere un rapporto più stretto tra docente e discente: molte tavole cliniche con la possibilità di essere ancora più vicino ai relatori, peraltro validissimi, e potersi confrontare con loro in un rapporto più stretto e scevro da qualsiasi forma di distacco.

Voglio ringraziare il Segretario, Dott. Franco senza il cui enorme lavoro questo Congresso non avrebbe potuto essere organizzato, tutto il Consiglio per l'indispensabile aiuto e un grazie particolare anche alla segreteria per la collaborazione veramente insostituibile.

Guardiamo al futuro e cerchiamo di anticiparlo e guidarlo sia nella nostra professione che nella nostra disciplina in particolare!

*Il Presidente SIE*
Pio Bertani

# STRUTTURA SOCIETARIA

**SEGRETARIO CULTURALE**

Dott. Roberto Fornara
Via G. Cler, 44
20013 Magenta (MI)
Tel. 02-97296453
Fax 02-97296453
e-mail: robertofornara01@gmail.com

**COORDINATORE**

Dott. Maria Giovanna Barboni
Via Ugo Bassi, 25
40121 Bologna (BO)
Tel. 051-4072763
Fax 051-6565327
e-mail: mjbarboni@mac.com

## SEGRETARI REGIONALI 2015

**SAE Abruzzo**
dott. Lucio Daniele
Viale Corrado IV, 6
67100 L'Aquila (AQ)
tel. 0862-25469
fax 0862-422309
drlucio@tiscali.it

**SEB Basilicata**
dott. Pier Luigi Schirosa
Via Dei Mille, 7/A
75020 Scanzano Jonico (MT)
tel. e fax. 0835-953493
cell. 333-7523958
pierluigi.schirosa@tiscali.it

**SCE Calabria**
dott. Giuseppe Multari
Via G. Del Fosso, 4
89127 Reggio Calabria (RC)
tel. 0965-811236
fax 0965-28410
cell. 368-7840763
g.multari@libero.it

**SEC Campania**
dott. Giancarlo Pongione
Via Antonio Mancini, 43
80127 Napoli (NA)
tel. 081-5780978
fax 081-7414866
cell. 338-5059287
gpongi@tin.it

**SERE Emilia Romagna**
dott. Enrico Cassai
Via Marcello Tassini, 4 int. 5
44121 Ferrara (FE)
tel. 0532-311822
fax 0532-746455
cell. 348-3944406
studiocassai@fastwebnet.it

**SER Lazio**
dott.ssa Emanuela Faitelli
Via Ugo Ojetti, 350
00137 Roma (RM)
tel. e fax 06-82003408
cell. 335-6069404
emanuela.faitelli2@gmail.com

**SEL Liguria**
dott.ssa Denise Pontoriero
Viale Amm.G. Des Geneys, 24/9
16148 Genova (GE)
tel. 335-214235
fax 010-6132840
denisepontoriero@yahoo.it

**SLE Lombardia**
dott. Stefano Gaffuri
Via Napoleone, 50
25039 Travagliato (BS)
tel. 030-6864844
fax 030-6866189
cell. 335-5866543
info@gaffurigalvaniodontoiatri.it

**SME Marche**
dott. Roberto Mancini
Via Del Porto, 17/C
47841 Cattolica (RN)
tel. 0541-963434
fax 0541-833322
roberto@banmancinifabbri.com

**SPE Piemonte e Valle d'Aosta**
dott. Giulio Del Mastro
C.so Francia, 81
10093 Collegno (TO)
tel. 011-4111878
cell. 329-8527937
giulio.delmastro@aio.it

**SEP Puglia**
dott.ssa Eva Amoroso D'Aragona
Via de Rossi, 102
70122 Bari (BA)
tel. 080-5241694
fax 080-5241109
evaamorosodaragona@hotmail.com

**SES Sardegna**
dott. Mauro Cabiddu
Via Lepanto, 67/B
09170 Oristano (OR)
tel. e fax 0783-70275
cell. 339-5087304
maurocabiddu@tiscali.it

**SSE Sicilia**
dott. Ciro Fuschino
Via L. Panepinto, 81
92010 Bivona (AG)
tel. 0922-986407
cell. 392-5250498
ciro.fuschino1@virgilio.it

**SET Toscana**
dott. Andrea Gesi
Via Giuseppe Impastato, 3
56122 Pisa (PI)
tel. e fax 050-23615
cell. 339-7956206
gesi@studiogesi.net

**STE Triveneto**
dott. Alberto Mazzocco
Via Cà di Cozzi 41/a
37124 Verona (VR)
tel. e fax 045-8344430
cell. 349-2504726
mazzocco.alberto@gmail.com

# STRUTTURA SOCIETARIA

## SOCI ONORARI

Borsotti Prof. Gianfranco
Bresciano Dott. Bartolo
Dolci Prof. Giovanni
Mantero Prof. Franco
Pecora Prof. Gabriele
Perrini Dott. Nicola

## SOCI ATTIVI

Agresti Dott. Daniele
Altamura Dott. Carlo
Amato Prof. Massimo
Ambu Dott. Emanuele
Amoroso d'Aragona Dott.ssa Eva
Ascione Dott.ssa Maria Rosaria
Autieri Dott. Giorgio
Badino Dott. Mario
Barattolo Dott. Raniero
Barboni Dott.ssa Maria Giovanna
Bartolucci Dott. Francesco
Bate Dott.ssa Anna Louise
Becciani Dott. Riccardo
Beccio Dott. Roberto
Bertani Dott. Pio
Berutti Prof. Elio
Bianco Dott. Alessandro
Bonaccorso Dott. Antonino
Bonacossa Dott. Lorenzo
Bonelli Bassano Dott. Marco
Borrelli Dott. Marino
Boschi Dott. Maurizio
Bottacchiari Dott. Renato Stefano
Botticelli Dott. Claudio
Braghieri Dott. Attilio
Brenna Dott. Franco
Buda Dott. Massimo
Cabiddu Dott. Mauro
Calabrò Dott. Antonio
Calapaj Dott. Massimo
Calderoli Dott. Stefano
Campo Dott.ssa Simonetta
Canonica Dott. Massimo
Cantatore Prof. Giuseppe
Capelli Dott. Matteo
Cardinali Dott. Filippo
Cardosi Carrara Dott. Fabrizio
Carmignani Dott. Enrico
Carratù Dott.ssa Paola
Carrieri Dott. Giuseppe
Cascone Dott. Andrea
Cassai Dott. Enrico
Castellucci Dott. Arnaldo
Castro Dott. Davide Fabio
Cavalleri Prof. Giacomo
Cavalli Dott. Giovanni
Cecchinato Dott. Luigi
Cerutti Prof. Antonio
Ciunci Dott. Renato Pasquale
Colla Dott. Marco
Conconi Dott. Marcello
Conforti Dott. Gian Paolo
Coraini Dott. Cristian
Cortellazzi Dott. Gianluca
Cotti Prof.ssa Elisabetta
Cozzani Dott.ssa Marina
D'Agostino Dott.ssa Alessandra
D'Arcangelo Prof. Camillo
Daniele Dott. Lucio
De Rosa Dott. Angelo
Del Mastro Dott. Giulio
Dell'Agnola Dott.ssa Antonella
Dettori Dott.ssa Claudia
Di Ferrante Dott. Giancarlo
Di Giuseppe Dott. Italo
Donati Dott. Paolo
Dorigato Dott.ssa Alessandra
Fabbri Dott. Massimiliano
Fabiani Dott. Cristiano
Faitelli Dott.ssa Emanuela
Fassi Dott. Angelo
Favatà Dott. Massimo
Fermani Dott. Giorgio
Ferrari Dott. Paolo
Ferrini Dott. Francesco
Foce Dott. Edoardo
Forestali Dott. Marco
Fornara Dott. Roberto
Fortunato Prof. Leonzio
Franco Dott. Vittorio
Fuschino Dott. Ciro
Gaffuri Dott. Stefano
Gagliani Prof. Massimo
Gallo Dott. Giancarlo
Gallottini Prof. Livio
Gambarini Prof. Gianluca
Generali Dott. Paolo
Gerosa Prof. Roberto
Gesi Dott. Andrea
Giacomelli Dott.ssa Grazia
Giovarruscio Dott. Massimo
Gnesutta Dott. Carlo
Gnoli Dott.ssa Rita
Gorni Dott. Fabio
Greco Dott.ssa Katia
Gullà Dott. Renato
Hazini Dott. Abdol Hamid
Kaitsas Prof. Vasilios
Kaitsas Dott. Roberto
La Rocca Dott. Sergio
Lalli Dott. Fabio
Lamorgese Dott. Vincenzo
Lendini Dott. Mario
Maggiore Dott. Francesco
Malagnino Prof.Vito Antonio
Malagnino Dott. Giampiero
Malentacca Dott. Augusto
Malvano Dott. Mariano
Mancini Dott. Roberto
Mancini Dott. Mario
Manfrini Dott.ssa Francesca
Mangani Prof. Francesco
Martignoni Dott. Marco
Massimilla Dott. Michele
Mazzocco Dott. Alberto
Migliau Dott. Guido
Monza Dott. Daniele
Mori Dott. Massimo
Multari Dott. Giuseppe
Mura Dott. Giovanni
Natalini Dott. Daniele
Negro Dott. Alfonso Roberto
Ongaro Dott. Franco
Orsi Dott.ssa Maria Veronica
Padovan Dott. Piero
Palmeri Dott. Mario
Pansecchi Dott. Davide
Pappalardo Dott. Alfio
Parente Dott. Bruno
Pasqualini Dott. Damiano
Piferi Dott. Marco
Pilotti Dott. Emilio
Pisacane Dott. Claudio
Polesel Prof. Andrea
Pollastro Dott. Giuseppe
Pongione Dott. Giancarlo
Pontoriero Dott.ssa Denise
Portulano Dott. Francesco
Pracella Dott. Pasquale
Preti Dott. Riccardo
Pulella Dott. Carmelo
Puttini Dott.ssa Monica
Raffaelli Dott. Renzo
Raia Dott. Roberto
Rapisarda Prof. Ernesto
Re Prof. Dino
Rengo Prof. Sandro
Riccitiello Prof. Francesco
Ricucci Dott. Domenico
Rieppi Dott. Alberto
Rigolone Dott. Mauro
Rizzoli Dott. Sergio
Roggero Dott. Emilio
Russo Dott. Ernesto
Santarcangelo Dott. Filippo Sergio
Sbardella Dott.ssa Maria Elvira
Sberna Dott.ssa Maria Teresa
Scagnoli Dott. Luigi
Schianchi Dott. Giovanni
Schirosa Dott. Pier Luigi
Serra Dott. Stefano
Simeone Prof. Michele
Smorto Dott.ssa Natalia
Sonaglia Dott. Angelo
Storti Dott.ssa Paola
Strafella Dott. Roberto
Stuffer Dott. Franz
Taglioretti Dott.Vito
Taschieri Dott. Silvio
Tavernise Dott. Salvatore
Tiberi Dott. Claudio
Tocchio Dott. Carlo
Tonini Dott. Riccardo
Tosco Dott. Eugenio
Tripi Dott.ssa Valeria Romana
Uberti Dott.ssa Manuela
Uccioli Dott. Umberto
Vecchi Dott. Stefano
Venturi Dott. Mauro
Venturi Dott. Giuseppe
Venuti Dott. Luca
Veralli Dott. Eduardo
Vignoletti Dott. Gianfranco
Vittoria Dott. Giorgio
Volpi Dott. Luca
Zaccheo Dott. Francesco
Zerbinati Dott. Massimo
Zilocchi Dott. Franco
Zuffetti Dott. Francesco

## SOCI AGGREGATI

Boari Dott. Daniele
Cuppini Dott.ssa Elisa
D'Alessandro Dott. Alfonso
Franchi Dott.ssa Irene
Gallo Dott. Roberto
Giovinazzo Dott. Luca
Iandolo Dott. Alfredo
Palazzi Dott. Flavio
Rovai Dott. Fabio
Squeo Dott. Giuseppe
Zaccheo Dott. Fabrizio

## SOCI ACCADEMICI

Angerame Prof. Daniele
Benedicenti Dott. Stefano
Bossù Prof. Maurizio
Ferrari Prof. Marco
Gherlone Prof. Enrico
Grandini Prof. Simone
Polimeni Prof.ssa Antonella
Prati Prof. Carlo
Salgarello Prof. Stefano

## SOCI SCOMPARSI

**Ricordiamo con affetto e gratitudine i Soci scomparsi:**

Garberoglio Dott. Riccardo
Socio Onorario
Pecchioni Prof. Augusto
Socio Onorario
Spina Dott. Vincenzo
Socio Onorario
Attanasio Dott. Salvatore
Socio Attivo
De Fazio Prof. Pietro
Socio Attivo
Duillo Dott. Sergio
Socio Onorario
Zerosi Prof. Carlo
Socio Onorario
Castagnola Prof. Luigi
Socio Onorario
Lavagnoli Dott. Giorgio
Socio Onorario
Riitano Dott. Francesco
Socio Onorario

## CONSIGLIO DIRETTIVO SIE TRIENNIO 2014-2016

Past President
Martignoni Dott. Marco

Presidente
Bertani Dott. Pio

Presidente Eletto
Riccitiello Prof. Francesco

Vice Presidente
Cavalli Dott. Giovanni

Segretario Tesoriere
Franco Dott. Vittorio

Segretario Culturale
Fornara Dott. Roberto

Consiglieri
Lendini Dott. Mario
Pasqualini Dott. Damiano
Revisori dei Conti
Sberna Dott.ssa Maria Teresa
Greco Dott.ssa Katia

# COME DIVENTARE SOCIO ATTIVO / AGGREGATO

SCARICABILE DAL SITO www.endodonzia.it

## SOCIO AGGREGATO

Per avere lo status di Socio Aggregato si dovrà presentare la documentazione descritta nel sito **www.endodonzia.it** che sarà valutata dalla Commissione Accettazione Soci. Possono accedere alla qualifica di Socio Aggregato tutti i Soci Ordinari della SIE, in regola con le quote associative degli ultimi TRE anni, che completino e forniscano la documentazione alla Segreteria Nazionale (Via Pietro Custodi 3, 20136 Milano) entro i termini che verranno indicati all'indirizzo web: **www.endodonzia.it**
La domanda dovrà essere firmata da un Socio Attivo il quale dovrà aver esaminato e approvato la documentazione.Quest'ultimo è responsabile della correttezza clinica e formale della documentazione presentata.

### DOCUMENTAZIONE PER DIVENTARE SOCIO AGGREGATO

Qualsiasi Socio Ordinario, con i requisiti necessari, può presentare l'insieme dei casi, in numero di 6 (sei), necessari per ottenere la qualifica di Socio Aggregato, secondo le modalità descritte.
L'aspirante Socio Aggregato potrà presentare i sei casi clinici in più volte, con un minimo di due casi per presentazione, in un arco di massimo cinque anni. Il mancato rinnovo della quota associativa, anche per un solo anno, annulla l'iter di presentazione dei casi.

## SOCIO ATTIVO

Per avere lo status di Socio Attivo si dovrà presentare la documentazione descritta nel sito www.endodonzia.it che sarà valutata dalla Commissione Accettazione Soci. Possono accedere alla qualifica di Socio Attivo tutti i Soci Ordinari della SIE, in regola con le quote associative degli ultimi TRE anni, che completino e forniscano alla Segreteria Nazionale (Via Pietro Custodi 3, 20136 Milano) entro i termini che verranno indicati all'indirizzo web: www.endodonzia.it ove sarà possibile reperire tutta la documentazione espressa di seguito. La domanda di ammissione allo "status" di Socio Attivo rivolta al Presidente della SIE, dovrà essere fatta pervenire, insieme alla documentazione, alla Segretaria della SIE. Le date di scadenza saranno rese note sul sito. La domanda dovrà essere firmata da un Socio Attivo il quale dovrà aver esaminato e approvato la documentazione. Quest'ultimo è responsabile della correttezza clinica e formale della documentazione presentata.

### DOCUMENTAZIONE PER DIVENTARE SOCIO ATTIVO

Qualsiasi Socio Ordinario, con i requisiti necessari, può presentare l'insieme dei casi, in numero di 10 (dieci), necessari per ottenere la qualifica di Socio Attivo, secondo le modalità descritte. Il Socio Aggregato che volesse presentare i casi per diventare Socio Attivo, potrà farlo già dall'anno successivo all'ottenimento della sua qualifica. In questo frangente il Socio Aggregato dovrà sottoporre la documentazione formata dai quattro casi mancanti.

## MODALITÀ DI DOCUMENTAZIONE DEI CASI CLINICI

I criteri e le modalità per la valutazione dei casi clinici idonei ad accedere alle qualifiche di Socio Aggregato e di Socio Attivo sono espressi nell'apposita sezione del Regolamento della Società Italiana di Endodonzia (SIE) all'indirizzo web: **www.endodonzia.it**

## CRITERI DI VALUTAZIONE

Il singolo caso clinico nel suo complesso, coerentemente con gli scopi e i fini della SIE, deve essere presentato considerando non solo l'aspetto clinico del caso, ma anche quello formale della documentazione presentata.

## ADEMPIMENTI DEL CANDIDATO

La domanda di ammissione allo "status" di Socio Aggregato/Attivo, rivolta al Presidente della SIE, **dovrà pervenire**, insieme alla documentazione di seguito elencata, **alla Segretaria della SIE con un anticipo di 20 giorni sulle date di riunione della CAS**, sufficiente per poter organizzare il materiale dei candidati. Le date di scadenza saranno rese note sul sito.
La domanda dovrà essere firmata da un Socio Attivo il quale dovrà aver esaminato e approvato la documentazione. Quest'ultimo è responsabile della correttezza clinica e formale della documentazione presentata.

## PRESENTAZIONE DEI CASI ALLA COMMISSIONE ACCETTAZIONE SOCI

La presenza del candidato è obbligatoria durante la riunione della CAS; è altresì consigliabile la presenza del Socio presentatore.

## LA COMMISSIONE ACCETTAZIONE SOCI

La CAS (Commissione Accettazione Soci), eletta ad ogni scadenza elettorale dall'Assemblea dei Soci Attivi ed Onorari, è formata da 5 Soci Attivi, con almeno 5 anni di anzianità in questo ruolo e di indiscussa esperienza clinica. Compito della CAS è quello di esaminare e valutare i Casi Clinici presentati dagli aspiranti Soci Aggregati e Soci Attivi. Per rispetto del lavoro dei Candidati e per omogeneità di giudizio, in ogni riunione verranno valutati non più di 5 candidati a Socio Attivo. Resta libero, invece, il numero dei candidati a Socio Aggregato valutabili in una singola riunione della CAS.
Il Consiglio Direttivo (CD) incaricando la Commissione Accettazione Soci (CAS) la rende responsabile dell' applicazione delle regole descritte nell' articolo 2 del regolamento. Il giudizio della CAS è insindacabile.

## MEMBRI DELLA COMMISSIONE ACCETTAZIONE SOCI 2015

- **Dott. Mario Mancini**
- **Dott. Franco Ongaro**
- **Dott. Andrea Polesel**
- **Dott. Giancarlo Pongione**
- **Dott. Mauro Rigolone**

# Nuovo motore

# X·smart iQ™

# Dentsply Maillefer

**L'innovativo motore X-Smart iQ, con movimento continuo e reciprocante, è controllato da un'applicazione iOS® progettata da DENTSPLY MAILLEFER per iPad Apple.**


Oltre a disporre dei settaggi di tutti gli strumenti rotanti e reciprocanti Dentsply Maillefer, **X-Smart iQ permette di eseguire la sequenza degli strumenti scelti per la terapia endodontica semplicemente premendo il pulsante sul manipolo**, ad esempio per passare dall'uso di Proglider a WAVEONE® GOLD.
Si possono anche creare sequenze personali da aggiungere a quelle già presenti. Impostazioni, velocità e torque degli strumenti a movimento continuo sono variabili liberamente per eventuali altri sistemi.
L'indicazione del livello di torque (**0.5Ncm - 5Ncm**) è immediata grazie al segnale visivo e sonoro; la funzione Auto-reverse si attiva al raggiungimento del limite del torque preimpostato. La funzione di calibrazione *(CAL)* permette di impostare il torque in modo più preciso.

L'acquisizione ed il **trasferimento dei dati** del trattamento appena effettuato avvengono in tempo reale *(numero del dente, lunghezza di lavoro, ultimo strumento utilizzato, otturazione, note)*.

**+ WE KNOW ENDO.**

La speciale sezione dedicata all'**Educazione del Paziente** si compone di immagini semplici ma efficaci attraverso le quali l'Odontoiatra potrà illustrare il trattamento endodontico al paziente.

**DENTSPLY MAILLEFER** sfrutta tutte le potenzialità di una APP iOS® per ridefinire il concetto di Endodonzia!

Simit Dental srl - www.simitdental.it - info@simitdental.it

# VDW.CONNECT Drive™

## Micromotore Endodontico Cordless

VDW.CONNECT Drive™ è l'innovativo micromotore endodontico cordless con movimento continuo e reciprocante, che ridefinisce il panorama della strumentazione endodontica.
Il concetto del nuovo motore VDW.CONNECT Drive™ con la App per iPad Apple per la gestione del trattamento endodontico, ridisegna l'endodonzia in chiave moderna e la combina con prestazioni straordinarie: utilizzo intuitivo, profili individuali, altissima mobilità grazie alla tecnologia senza fili, garantiscono massima flessibilità ed efficienza. La testina miniaturizzata del contrangolo, regolabile a 360°, assicura un facile accesso alla cavità orale ed un'eccellente visibilità. La batteria permette di effettuare fino a 16 trattamenti e il manipolo è ricaricabile anche durante l'uso.

## Liberi di scegliere

VDW.CONNECT Drive™ può essere utilizzato **con e senza la App**:

- senza la App è già pronto per essere usato con il sistema RECIPROC® - one file endo, che permette la preparazione del canale con un solo strumento reciproco, in modo più semplice, più sicuro e più veloce;
- con la App gestisce le impostazioni preprogrammate per i sistemi alternati e per i sistemi rotanti in Ni-Ti più diffusi.

## Intuitivo ed immediato

- Visualizzazione chiara e ordinata sul display;
- Gli strumenti sono mostrati in scala con ingrandimento e con codifica ISO a colori per garantire una gestione facile ed immediata durante la procedura operativa.

**La App VDW.CONNECT** permette di gestire tutte le funzioni del motore e le informazioni necessarie per un trattamento endodontico di successo. Il funzionamento intuitivo e le impostazioni personalizzate garantiscono una maggiore sicurezza durante il trattamento ed un flusso di lavoro più efficiente.

Download on the App Store

VDW.CONNECT App è disponibile su **Apple Store**
**Free Download**

La App VDW.CONNECT è compatibile con iPad e iPad mini,
con aggiornamento Bluetooth 4.0 e aggiornamento iOS 8.0 e successivi.
Apple, il logo Apple, App Store e iPad sono marchi registrati Apple Inc.

Numero Verde 800-310333

DENTSPLY Italia S.r.l.
Piazza dell'Indipendenza, 11B · 00185 Roma · Fax 06 72640394
infoweb.italia@dentsply.com · www.dentsply.it

For better dentistry
DENTSPLY

**26-28 GIUGNO 2015, PADOVA**

# Closed Meeting SIE

**Hotel Majestic - Radisson Blu Resort - Terme di Galzignano, Padova**

*Resoconto a cura del Dott. Cristian Coraini*

Nelle giornate dello scorso 26, 27 e 28 Giugno 2015, presso la splendida cornice dell'**Hotel Majestic - Radisson Blu Resort Terme di Galzignano** (Padova), si è svolta la consueta edizione annuale del Closed Meeting della SIE.
Il programma ha previsto, nella giornata di venerdì 26 mattina, lo svolgimento della riunione del Consiglio Direttivo SIE e della Commissione Accettazione Soci Attivi (CAS).
Nel pomeriggio iniziava il vero e proprio programma scientifico, con la conferenza tenuta dal Professor Antonio Pelliccia, ospite per l'occasione, che ha relazionato sul tema "*Quanto vale un dente? Qualità percepita dal paziente + Endodonzia di valore = Marketing Etico*", destando grande interesse e partecipazione fra i Soci Attivi presenti.
Il pomeriggio culturale proseguiva con la presentazione di 2 casi da parte dei colleghi neo Soci Attivi SIE Dottor Luca Volpi e Dottor Luca Ivaldi, seguto dalla presentazione da parte del Dottor Matteo Meardi del "Miglior Caso Clinico Under 32".
Dalle 18.00 si svolgeva poi la mitica partita di calcetto NORD VS SUD: dopo anni di severe batoste patite, quest'anno si aggiudicava trionfalmente il match la squadra del nord, forse anche complici le defezioni degli esponenti di punta della squadra avversaria (gli anni passano per tutti…).
La giornata proseguiva con il consueto e gradevolissimo aperitivo a bordo piscina, seguito dalla cena presso il ristorante del resort.
Il Sabato 27 cominciava con la conferenza della Professoressa Elisabetta Cotti, sul tema *"Malattia Endodontica e Patologia Sistemica: uno stato dell'arte"*.
Ne è seguita la "Presentazione delle attività svolte dalla Commissione WEB" e la "Tavola Rotonda SIE: *progetti in essere e proposte"*.
La mattinata si concludeva con relax in piscina, attività sportive e revital wellness, usufruendo di un'ampia gamma di servizi e spazi dedicati, disponibili presso la splendida location.
Dopo pranzo, gli incontri culturali-scientifici erano dedicati alle assemblee delle varie Commissioni, quali la Riunione della Commissione Culturale, della Commissione per la Ricerca, della Commissione Web e quella dei Segretari Regionali.
Concludeva la seconda giornata del Closed Meeting l'immancabile e tradizionale cena, per l'occasione tenutasi presso la magnifica e caratteristica "Antica Trattoria Ballotta dal 1605".
La giornata conclusiva della domenica chiudeva il Closed Meeting, con un programma libero culturale, sportivo e di relax.
Si svolgeva infatti presso il Golf Club della Montecchia il torneo di Golf per gli appassionati di questo sport, mentre per chi era attratto dal genio di Giotto, veniva organizzata una gita presso la splendida Cappella degli Scrovegni.
Per i più pigri invece, ancora wellness e relax nelle grandi e magnifiche piscine termali, che precedevano il rientro a casa.
Il Closed Meeting rappresenta un punto fermo per i soci della SIE, un momento di aggregazione culturale e ludico, l'occasione di approfondire contatti e conoscenze, trascorrendo del tempo libero in contesti sempre piacevolissimi, un vero momento di aggregazione in pieno spirito societario SIE.
Anche questa edizione ha colto nel segno, centrando ognuno degli obiettivi menzionati.

CENA DI GALA

RIUNIONE DEI SEGRETARI REGIONALI

COCKTAIL A BORDO PISCINA

DOTT. LUCA IVALDI

DOTT. LUCA VOLPI

DOTT. MATTEO MEARDI

GIOVEDÌ SERA AL CAFFÈ PEDROCCHI

GITA ALLA CAPPELLA DEGLI SCROVEGNI

I SAPORI SICILIANI INCONTRANO PADOVA

I TENNISTI SIE

IL PRESIDENTE DOTT. PIO BERTANI E IL DOTT. COLLA

PROF. ANTONIO PELLICCIA


LA TORTA SIE

LE SQUADRE SCHIERATE

LA PROF.SSA COTTI CON IL PRESIDENTE ED IL SEGRETARIO

RIUNIONE DELLA COMMISSIONE CULTURALE

RIUNIONE DELLA COMMISSIONE PER LA RICERCA

GIORNALE ITALIANO DI ENDODONZIA

# INSTRUCTION AUTHOR

## CONTENT OF AUTHOR GUIDELINES:



The journal to which you are submitting your manuscript employs a plagiarism detection system. By submitting your manuscript to this journal you accept that your manuscript may be screened for plagiarism against previously published works.

## 1. GENERAL

Giornale Italiano di Endodonzia publishes original scientific articles, reviews, clinical articles and case reports in the field of Endodontology. Scientific contributions dealing with health, injuries to and diseases of the pulp and periradicular region, and their relationship with systemic well-being and health. Original scientific articles are published in the areas of biomedical science, applied materials science, bioengineering, epidemiology and social science relevant to endodontic disease and its management, and to the restoration of root-treated teeth. In addition, review articles, reports of clinical cases, book reviews, summaries and abstracts of scientific meetings and news items are accepted.

Please read the instructions below carefully for details on the submission of manuscripts, the journal's requirements and standards as well as information concerning the procedure after a manuscript has been accepted for publication in *Giornale Italiano di Endodonzia*.
Authors are encouraged to visit GIE web site **gi-endodonzia.com** for further information on the preparation and submission of articles and figures.

## 2. ETHICAL GUIDELINES

*Giornale Italiano di Endodonzia* adheres to the below ethical guidelines for publication and research.

### 2.1. Authorship and Acknowledgements

Authors submitting a paper do so on the understanding that the manuscript has been read and approved by all authors and that all authors agree to the submission of the manuscript to the *Giornale Italiano di Endodonzia*.

*Giornale Italiano di Endodonzia* adheres to the definition of authorship set up by The International Committee of Medical Journal Editors (ICMJE). According to the ICMJE, authorship criteria should be based on 1) substantial contributions to conception and design of, or acquisiation of data or analysis and interpretation of data, 2) drafting the article or revising it critically for important intellectual content and 3) final approval of the version to be published. Authors should meet conditions 1, 2 and 3.

It is a requirement that all authors have been accredited as appropriate upon submission of the manuscript. Contributors who do not qualify as authors should be mentioned under Acknowledgements.
**Acknowledgements:**
Under acknowledgements please specify contributors to the article other than the authors accredited. Please also include specifications of the source of funding for the study and any potential conflict of interests if appropriate.

### 2.2. Ethical Approvals

Experimentation involving human subjects will only be published if such research has been conducted in full accordance with ethical principles, including the World Medical Association Declaration of Helsinki (version 2008) and the additional requirements, if any, of the country where the research has been carried out.

Manuscripts must be accompanied by a statement that the experiments were undertaken with the understanding and written consent of each subject and according to the above mentioned principles. A statement regarding the fact that the study has been independently reviewed and approved by an ethical board should also be included. Editors reserve the right to reject papers if there are doubts as to whether appropriate procedures have been used.

When experimental animals are used the methods section must clearly indicate that adequate measures were taken to minimize pain or discomfort. Experiments should be carried out in accordance with the Guidelines laid down by the National Institute of Health (NIH) in the USA regarding the care and use of animals for experimental procedures or with the European Communities Council Directive of 24 November 1986 (86/609/EEC) and in accordance with local laws and regulations.

All studies using human or animal subjects should include an explicit statement in the Material and Methods section identifying the review and ethics committee approval for each study, if applicable. Editors reserve the right to reject papers if there is doubt as to whether appropriate procedures have been used.

### 2.3 Clinical Trials

Clinical trials should be reported using the guidelines available at www.consort-statement.org.

A CONSORT checklist and flow diagram (as a Figure) should also be included in the submission material.

The *Giornale Italiano di Endodonzia* encourages authors submitting manuscripts reporting from a clinical trial to register the trials in any of the following free, public clinical trials registries: www.clinicaltrials.gov, http://clinicaltrials.ifpma.org/clinicaltrials/, http://isrctn.org/. The clinical trial registration number and name of the trial register will then be published with the paper.

### 2.4 Systematic Reviews

Systematic reviews should be reported using the PRISMA guidelines available at http://prisma-statement.org/. A PRISMA checklist and flow diagram (as a Figure) should also be included in the submission material.

### 2.5 Conflict of Interest and Source of Funding

Giornale Italiano di Endodonzia requires that all sources of institutional, private and corporate financial support for the work within the manuscript must be fully acknowledged, and any potential conflicts of interest noted.

Grant or contribution numbers may be acknowledged, and principal grant holders should be listed. Please include the information under Acknowledgements.

### 2.6 Appeal of Decision

The decision on a paper is final and cannot be appealed.

### 2.7 Permissions

If all or parts of previously published illustrations are used, permission must be obtained from the copyright holder concerned. It is the author's responsibility to obtain these in writing and provide copies to the Publishers.

### 2.8 Copyright Assignment

If your paper is accepted, the author identified as the formal corresponding author for the paper will receive an email by editor's address,editor.giornale@endodonzia.it, to complete the license agreement on behalf of all authors on the paper.

## 3. MANUSCRIPT SUBMISSION PROCEDURE

Manuscripts should be submitted electronically by e-mail:
**editor.giornale@endodonzia.it**

### 3.1. Manuscript Files Accepted

Manuscripts should be uploaded as Word (.doc) or Rich Text Format (.rft) files (not write-protected) plus separate figure files. GIF, JPEG, PICT or Bitmap files are acceptable for submission, but only high-resolution TIF or EPS files are suitable for printing.

The text file must contain the abstract, main text, references, tables, and figure legends, but no embedded figures or Title page. The Title page should be provided as a separate file.
In the main text, please reference figures as for instance 'Figure 1', 'Figure 2' etc to match the tag name you choose for the individual figure files uploaded. Manuscripts should be formatted as described in the Author Guidelines below.

### 3.2. Blinded Review

Manuscript that do not conform to the general aims and scope of the journal will be returned immediately without review.
All other manuscripts will be reviewed by experts in the field (generally two referees).
*Giornale Italiano di Endodonzia* aims to forward referees' comments and to inform the corresponding author of the result of the review process.
Manuscripts will be considered for fast-track publication under special circumstances after consultation with the Editor.

*Giornale Italiano di Endodonzia* uses double blinded review. The names of the reviewers will thus not be disclosed to the author submitting a paper and the name(s) of the author(s) will not be disclosed to the reviewers.

To allow double blinded review, please submit your main manuscript

and title page as separate files.

### 3.3. E-mail Confirmation of Submission

After submission you will receive an e-mail to confirm receipt of your manuscript. If you do not receive the confirmation e-mail after 24 hours, please send an e-mail once again to editor.giornale@endodonzia.it or contact segreteria.sie@me.com.

### 3.4. Submission of Revised Manuscripts

All the revised manuscripts will be sent to the author; to submit a revised masucript please re-contact the e-mail address of the journal: editor.giornale@endodonzia.it.

## 4. MANUSCRIPT TYPES ACCEPTED

**Original Scientific Articles**: must describe significant and original experimental observations and provide sufficient detail so that the observations can be critically evaluated and, if necessary, repeated. Original Scientific Articles must conform to the highest international standards in the field.

**Review Articles:** are accepted for their broad general interest; all are refereed by experts in the field who are asked to comment on issues such as timeliness, general interest and balanced treatment of controversies, as well as on scientific accuracy. Reviews should generally include a clearly defined search strategy and take a broad view of the field rather than merely summarizing the authors´ own previous work. Extensive or unbalanced citation of the authors´ own publications is discouraged.

**Mini Review Articles:** are accepted to address current evidence on well-defined clinical, research or methodological topics. All are refereed by experts in the field who are asked to comment on timeliness, general interest, balanced treatment of controversies, and scientific rigor. A clear research question, search strategy and balanced synthesis of the evidence is expected. Manuscripts are limited in terms of word-length and number of figures.

**Clinical Articles:** are suited to describe significant improvements in clinical practice such as the report of a novel technique, a breakthrough in technology or practical approaches to recognised clinical challenges. They should conform to the highest scientific and clinical practice standards.

**Case Reports:** illustrating unusual and clinically relevant observations are acceptable but they must be of sufficiently high quality to be considered worthy of publication in the Journal. On rare occasions, completed cases displaying non-obvious solutions to significant clinical challenges will be considered. Illustrative material must be of the highest quality and healing outcomes, if appropriate, should be demonstrated.

## 5. MANUSCRIPT FORMAT AND STRUCTURE

### 5.1. Format

**Language:** The language of publication is English. It is preferred that manuscript is professionally edited. All services are paid for and arranged by the author, and use of one of these services does not guarantee acceptance or preference for publication

**Presentation:** Authors should pay special attention to the presentation of their research findings or clinical reports so that they may be communicated clearly. Technical jargon should be avoided as much as possible and clearly explained where its use is unavoidable.
Abbreviations should also be kept to a minimum, particularly those that are not standard. The background and hypotheses underlying the study, as well as its main conclusions, should be clearly explained. Titles and abstracts especially should be written in language that will be readily intelligible to any scientist.

**Abbreviations:** Giornale Italiano di Endodonzia adheres to the conventions outlined in Units, Symbols and Abbreviations: A Guide for Medical and Scientific Editors and Authors. When non-standard terms appearing 3 or more times in the manuscript are to be abbreviated, they should be written out completely in the text when first used with the abbreviation in parenthesis.

### 5.2. Structure

All manuscripts submitted to Giornale Italiano di Endodonzia should include Title Page, Abstract, Main Text, References and Acknowledgements, Tables, Figures and Figure Legends as appropriate
**Title Page:** The title page should bear: (i) Title, which should be concise as well as descriptive; (ii) Initial(s) and last (family) name of each author; (iii) Name and address of department, hospital or institution to which work should be attributed; (iv) Running title (no more than 30 letters and spaces); (v) No more than six keywords (in alphabetical order); (vi) Name, full postal address, telephone, fax number and e-mail address of author responsible for correspondence.

**Abstract for Original Scientific Articles** should be no more than 250 words giving details of what was done using the following structure:
• **Aim:** Give a clear statement of the main aim of the study and the main hypothesis tested, if any.
• **Methodology:** Describe the methods adopted including, as appropriate, the design of the study, the setting, entry requirements for subjects, use of materials, outcome measures and statistical tests.
• **Results:** Give the main results of the study, including the outcome of any statistical analysis.
• **Conclusions:** State the primary conclusions of the study and their implications. Suggest areas for further research, if appropriate.

**Abstract for Review Articles** should be non-structured of no more than 250 words giving details of what was done including the literature search strategy.

**Abstract for Mini Review Articles** should be non-structured of no more than 250 words, including a clear research question, details of the literature search strategy and clear conclusions.

**Abstract for Case Reports** should be no more than 250 words using the following structure:
• **Aim:** Give a clear statement of the main aim of the report and the clinical problem which is addressed.
• **Summary:** Describe the methods adopted including, as appropriate, the design of the study, the setting, entry requirements for subjects, use of materials, outcome measures and analysis if any.
• **Key learning points:** Provide up to 5 short, bullet-pointed statements to highlight the key messages of the report. All points must be fully justified by material presented in the report.

**Abstract for Clinical Articles** should be no more than 250 words using the following structure:
• **Aim:** Give a clear statement of the main aim of the report and the clinical problem which is addressed.
• **Methodology:** Describe the methods adopted.
• **Results:** Give the main results of the study.
• **Conclusions:** State the primary conclusions of the study.

**Main Text of Original Scientific Article** should include Introduction, Materials and Methods, Results, Discussion and Conclusion.

**Introduction:** should be focused, outlining the historical or logical origins of the study and gaps in knowledge. Exhaustive literature reviews are not appropriate. It should close with the explicit statement of the specific aims of the investigation, or hypothesis to be tested.
**Material and Methods:** must contain sufficient detail such that, in combination with the references cited, all clinical trials and experiments reported can be fully reproduced.

***(i) Clinical Trials*** should be reported using the CONSORT guidelines available at www.consort-statement.org. A CONSORT checklist and flow diagram (as a Figure) should also be included in the submission material.

***(ii) Experimental Subjects:*** experimentation involving human subjects will only be published if such research has been conducted in full accordance with ethical principles, including the World Medical Association Declaration of Helsinki (version 2008) and the additional requirements, if any, of the country where the research has been carried out. Manuscripts must be accompanied by a statement that the experiments were undertaken with the understanding and written consent of each subject and according to the above mentioned principles. A statement regarding the fact that the study has been independently reviewed and approved by an ethical board should also be included. Editors reserve the right to reject papers if there are doubts as to whether appropriate procedures have been used.

When experimental animals are used the methods section must clearly indicate that adequate measures were taken to minimize pain or discomfort. Experiments should be carried out in accordance with the Guidelines laid down by the National Institute of Health (NIH) in the USA regarding the care and use of animals for experimental procedures or with the European Communities Council Directive of 24 November 1986 (86/609/EEC) and in accordance with local laws and regulations.
All studies using human or animal subjects should include an explicit statement in the Material and Methods section identifying the review and ethics committee approval for each study, if applicable.
Editors reserve the right to reject papers if there is doubt as to whether appropriate procedures have been used.

***(iii) Suppliers:*** Suppliers of materials should be named and their location (Company, town/city, state, country) included.

**Results:** should present the observations with minimal reference to earlier literature or to possible interpretations. Data should not be duplicated in Tables and Figures.

**Discussion:** may usefully start with a brief summary of the major findings, but repetition of parts of the abstract or of the results section should be avoided. The Discussion section should progress with a review of the methodology before discussing the results in light of previous work in the field. The Discussion should end with a brief conclusion and a comment on the potential clinical relevance of the findings. Statements and interpretation of the data should be appropriately supported by original references.

**Conclusion:** should contain a summary of the findings.

**Main Text of Review Articles** should

be divided into Introduction, Review and Conclusions. The Introduction section should be focused to place the subject matter in context and to justify the need for the review. The Review section should be divided into logical sub-sections in order to improve readability and enhance understanding. Search strategies must be described and the use of state-of-the-art evidence-based systematic approaches is expected. The use of tabulated and illustrative material is encouraged. The Conclusion section should reach clear conclusions and/or recommendations on the basis of the evidence presented.

**Main Text of Mini Review Articles** should be divided into Introduction, Review and Conclusions. The Introduction section should briefly introduce the subject matter and justify the need and timeliness of the literature review. The Review section should be divided into logical sub-sections to enhance readability and understanding and may be supported by up to 5 tables and figures. Search strategies must be described and the use of state-of-the-art evidence-based systematic approaches is expected. The Conclusions section should present clear statements/recommendations and suggestions for further work. The manuscript, including references and figure legends should not normally exceed 4000 words.

**Main Text of Clinical Reports and Clinical Articles** should be divided into Introduction, Report, Discussion and Conclusion,. They should be well illustrated with clinical images, radiographs, diagrams and, where appropriate, supporting tables and graphs. However, all illustrations must be of the highest quality

**Acknowledgements:** *Giornale Italiano di Endodonzia* requires that all sources of institutional, private and corporate financial support for the work within the manuscript must be fully acknowledged, and any potential conflicts of interest noted. Grant or contribution numbers may be acknowledged, and principal grant holders should be listed. Acknowledgments should be brief and should not include thanks to anonymous referees and editors.

### 5.3. References

It is the policy of the Journal to encourage reference to the original papers rather than to literature reviews. Authors should therefore keep citations of reviews to the absolute minimum.

We recommend the use of a tool such as EndNote or Reference Manager for reference management and formatting. EndNote reference styles can be searched for here: www.endnote.com/support/enstyles.asp. Reference Manager reference styles can be searched for here: www.refman.com/support/rmstyles.asp

**In the text:** a number in order of citation is the reference inside the manuscript; example (1)

**Reference list:** All references should be brought together at the end of the paper in numerical order and should be in the following form.

*- Names and initials of up to six authors. When there are seven or more, list the first three and add et al.*
*- Full title of paper followed by a full stop (.)*
*- Title of journal abbreviated (es. Journal of Endodontics : J Endod)*
*- Year of publication followed by ;*
*- Volume number*
*- Issue number in parenthesis (es.: (5)) followed by :*
*- First and last pages*

Examples of correct forms of reference follow:

**Standard journal article**
(1) Somma F, Cammarota G, Plotino G, Grande NM, Pameijer CH. The effectiveness of manual and mechanical instrumentation for the retreatment of three different root canal filling materials. J Endod 2008;34(4):466—9.

**Corporate author**
British Endodontic Society - Guidelines for root canal treatment. Giornale Italiano di Endodonzia 1979; 16: 192-5.

**Journal supplement**
Frumin AM, Nussbaum J, Esposito M () Functional asplenia: demonstration of splenic activity by bone marrow scan (Abstract). Blood 1979; 54 (Suppl. 1): 26a.

**Books and other monographs**

**Personal author(s)**
Gutmann J, Harrison JW Surgical Endodontics, 1st edn Boston, MA, USA: Blackwell Scientific Publications, 1991.

**Chapter in a book**
Wesselink P Conventional root-canal therapy III: root filling. In: Harty FJ, ed. Endodontics in Clinical Practice, (1990) , 3rd edn; pp. 186-223. London, UK: Butterworth.

**Published proceedings paper**
DuPont B Bone marrow transplantation in severe combined immunodeficiency with an unrelated MLC compatible donor. In: White HJ, Smith R, eds. Proceedings of the Third Annual Meeting of the International Society for Experimental Rematology; (1974), pp. 44-46. Houston, TX, USA: International Society for Experimental Hematology.

**Agency publication**
Ranofsky AL Surgical Operations in Short-Stay Hospitals: United States-1975 (1978). DHEW publication no. (PHS) 78-1785 (Vital and Health Statistics; Series 13; no. 34.) Hyattsville, MD, USA: National Centre for Health Statistics.8

**Dissertation or thesis**
Saunders EM In vitro and in vivo investigations into root-canal obturation using thermally softened gutta-percha techniques (PhD Thesis) (1988). Dundee, UK: University of Dundee.

**URLs**
Full reference details must be given along with the URL, i.e. authorship, year, title of document/report and URL. If this information is not available, the reference should be removed and only the web address cited in the text.
Smith A Select committee report into social care in the community [WWW document]. (1999) URL http://www.dhss.gov.uk/reports/report015285.html
[accessed on 7 November 2003]

### 5.4. Tables, Figures and Figure Legends

**Tables:** Tables should be double-spaced with no vertical rulings, with a single bold ruling beneath the column titles. Units of measurements must be included in the column title.
**Figures:** All figures should be planned to fit within either 1 column width (8.0 cm), 1.5 column widths (13.0 cm) or 2 column widths (17.0 cm), and must be suitable for photocopy reproduction from the printed version of the manuscript. Lettering on figures should be in a clear, sans serif typeface (e.g. Helvetica); if possible, the same typeface should be used for all figures in a paper. After reduction for publication, upper-case text and numbers should be at least 1.5-2.0 mm high (10 point Helvetica). After reduction, symbols should be at least 2.0-3.0 mm high (10 point).

All half-tone photographs should be submitted at final reproduction size. In general, multi-part figures should be arranged as they would appear in the final version. Reduction to the scale that will be used on the page is not necessary, but any special requirements (such as the separation distance of stereo pairs) should be clearly specified.

Unnecessary figures and parts (panels) of figures should be avoided: data presented in small tables or histograms, for instance, can generally be stated briefly in the text instead. Figures should not contain more than one panel unless the parts are logically connected; each panel of a multipart figure should be sized so that the whole figure can be reduced by the same amount and reproduced on the printed page at the smallest size at which essential details are visible.

Figures should be on a white background, and should avoid excessive boxing, unnecessary colour, shading and/or decorative effects (e.g. 3-dimensional skyscraper histograms) and highly pixelated computer drawings. The vertical axis of histograms should not be truncated to exaggerate small differences. The line spacing should be wide enough to remain clear on reduction to the minimum acceptable printed size.

Figures divided into parts should be labelled with a lower-case, boldface, roman letter, a, b, and so on, in the same typesize as used elsewhere in the figure. Lettering in figures should be in lower-case type, with the first letter capitalized.

Units should have a single space between the number and the unit, and follow SI nomenclature or the nomenclature common to a particular field. Thousands should be separated by a thin space (1 000). Unusual units or abbreviations should be spelled out in full or defined in the legend. Scale bars should be used rather than magnification factors, with the length of the bar defined in the legend rather than on the bar itself. In general, visual cues (on the figures themselves) are preferred to verbal explanations in the legend (e.g. broken line, open red triangles etc.).

**Figure legends:** Figure legends should begin with a brief title for the whole figure and continue with a short description of each panel and the symbols used; they should not contain any details of methods.

**Permissions:** If all or part of previously published illustrations are to be used, permission must be obtained from the copyright holder concerned. This is the responsibilty of the authors before submission.

**Preparation of Electronic Figures for Publication:** Although low quality images are adequate for review purposes, print publication requires high quality images to prevent the final product being blurred or fuzzy.
Submit EPS (lineart) or TIFF (halftone/photographs) files only. MS PowerPoint and Word Graphics are unsuitable for printed pictures. Do not use pixel-oriented programmes. Scans (TIFF only) should have a resolution of 300 dpi (halftone) or 600 to 1200 dpi (line drawings) in relation to the reproduction size (see below). EPS files should be saved with fonts embedded (and with a TIFF preview if possible).
For scanned images, the scanning resolution (at final image size) should be as follows to ensure good reproduction: lineart: >600 dpi; half-tones (including gel photographs): >300 dpi; figures containing both halftone and line images: >600 dpi.

## 6. AFTER ACCEPTANCE

Upon acceptance of a paper for publication, the manuscript will be forwarded to the Production Editor who is responsible for the production of the journal.

**6.1. Figures**
Hard copies of all figures and tables are required when the manuscript is ready for publication. These will be requested by the Editor when required. Each Figure copy should be marked on the reverse with the figure number and the corresponding author's name.

**6.2 Proof Corrections**
The corresponding author will receive an email alert containing a link to a web site.
A working email address must therefore be provided for the corresponding author. The proof can be downloaded as a PDF (portable document format) file from this site. Acrobat Reader will be required in order to read this file. This software can be downloaded (free of charge) from the following Web site: www.adobe.com/products/acrobat/readstep2.html.
This will enable the file to be opened, read on screen, and printed out in order for any corrections to be added.
Further instructions will be sent with the proof. Hard copy proofs will be posted if no e-mail address is available; in your absence, please arrange for a colleague to access your e-mail to retrieve the proofs.
**Proofs must be returned to the Production Editor within five days of receipt, even if there are no corrections. Elsevier may proceed with publication of the article if no response is received.**

As changes to proofs are costly, we ask that you only correct typesetting errors.
Excessive changes made by the author in the proofs, excluding typesetting errors, will be charged separately.
Other than in exceptional circumstances, all illustrations are retained by the publisher.
Please note that the author is responsible for all statements made in his work, including changes made by the copy editor.

## ISTRUZIONI AGLI AUTORI

Il *Giornale Italiano di Endodonzia* è una pubblicazione esclusivamente disponibile in formato elettronico e rappresenta l'organo ufficiale della Società Italiana di Endodonzia.

Si appoggia, per la sua diffusione ad Elsevier e gli articoli in esso pubblicati sono reperibili su Scopus.

**La cadenza di pubblicazione è semestrale: Maggio/Giugno Novembre/Dicembre.**

Per quanto attiene le norme editoriali per la pubblicazione di articoli aventi come tema l'Endodonzia in senso lato si pregano gli autori di riferirsi al documento in inglese reperibile sul sito www.gi-endodonzia.com.

Articoli in lingua italiana saranno pubblicabili, ma si darà preferenza a contributi in lingua inglese che potrebbero avere una risonanza internazionale ben più ampia.

La Società Italiana di Endodonzia si farà carico di rivedere la forma dei contributi in lingua inglese attraverso un sistema di controllo specifico.